

Effect of Hydrochlorothiazide (Esidrex) On Reproductive Parameters in Male Wistar Rats

Oyedeji K. O.*¹, Robert Ebipate¹, Arubi Peter², Oyawale Gboluwaga³

¹Department of Physiology, College of Medicine and Health Sciences, Afe Babalola University, Ado-Ekiti, Nigeria

²Department of Pharmacology and Therapeutics, Benue State University, Markurdi, Nigeria.

³Department of Physiology, College of Medicine, University of Ibadan, Nigeria.

Abstract

Objective: This study was designed to evaluate the reproductive effect of hydrochlorothiazide on reproductive parameters in male Wistar rats.

Methods: Twelve male Wistar rats (120 - 140 g) were divided into control (distilled water) and hydrochlorothiazide-treated (0.36 mg/kg) groups (6 per group) for hormonal assay, andrological and histopathological studies. The animals were orally treated on daily basis for 50 days. Plasma testosterone levels were assayed using Enzyme-linked Immuno-sorbent Assay (ELISA) and semen analysis was done microscopically. Histology of testes was also done. Data were analysed using descriptive statistics and ANOVA at $p=0.05$.

Results: Treatment of rats with hydrochlorothiazide (0.36 mg/kg) caused significant ($p<0.05$) increment in testosterone level relative to control. Treatment of rats with hydrochlorothiazide (0.36 mg/kg) caused significant ($p<0.05$) reductions in progressive sperm motility and sperm counts relative to their respective controls.

Conclusion: It can therefore be concluded that hydrochlorothiazide probably have deleterious effect on the reproductive functions in male rats.

Keywords: Hydrochlorothiazide, Testosterone, Sperm motility, Sperm counts, Rats.

INTRODUCTION

Hydrochlorothiazide is a diuretic medication often used to treat high blood pressure and swelling due to fluid build-up [1]. Other uses include diabetes insipidus, renal tubular acidosis, and to decrease the risk of kidney stones in those with high calcium level in the urine. For high blood pressure it is often recommended as a first line treatment [2].

Hydrochlorothiazide has been reported to induce developmental toxicity in mice and rats [3]. Its potential interaction with green tea extract on diuretic activity in rats has been reported [4]. Hydrochlorothiazide has been reported to potentiate contractile activity of mouse cavernosal smooth muscle [5]. Its proconvulsive effect in an in vitro rat seizure model [6] as well as pathologic effects of its chronic administration to F344 rats have been reported [7]. Chronic hydrochlorothiazide administration has also been reported to increase H^+ -ATPase B1 subunit abundance in rat kidney [8].

However, due to scanty information from literature on the effect of hydrochlorothiazide on reproductive parameters in male rats, this study therefore aims at investigating the effect of this antihypertensive agent on these aforementioned parameters in male rats.

MATERIALS AND METHODS

Experimental Animals

Adult male rats weighing between 120 – 140 g bred in the Pre-Clinical Animal House of the College of Medicine and Health Sciences, Afe Babalola University were used. They were housed under standard laboratory conditions and had free access to feed and water; they were acclimatized for two weeks to laboratory conditions before the commencement of the experiments. All experiments were carried out in compliance with the recommendations of Afe Babalola University Ethics Committee on guiding principles on care and use of animals.

Drug

Hydrochlorothiazide (esidrex) tablets (Norvatis Pharma Ltd) were bought from Danax Pharmacy, Ibadan, Nigeria. Hydrochlorothiazide (25 mg) was dissolved in 10 ml of distilled water to give a concentration of 2.5 mg/mL. The dosage of hydrochlorothiazide used in this study was in accordance with that reported by the manufacturer.

Body Weight

Body weight was monitored on weekly basis throughout the duration of the experiment for each rat.

Experimental Design

Twelve male rats (120 – 140 g) were randomly divided into two groups, with each consisting of six animals. The two groups were subjected to the following oral treatments once a day for fifty (50) days:

Group I: received 0.5 mL/100 g of distilled water as control group.

Group II: received 0.36 mg/kg of hydrochlorothiazide.

Collection of Blood Samples

Twenty four hours (day 51) after the last dosing of the groups, blood samples were collected from all the animals through the medial cantus for the determination of plasma testosterone levels. All the animals were later sacrificed by an overdose of diethyl ether and the testes were removed along with the epididymis for semen analysis.

Hormonal Assay

Plasma samples were assayed for testosterone using the enzyme-linked immunosorbent assay (ELISA) technique using the Fortress kit.

Semen Collection

The testes were removed along with the epididymides. The caudal epididymides were separated from the testes, blotted with filter papers and lacerated to collect the semen.

Semen Analysis

Progressive sperm motility: This was done immediately after the semen collection. Semen was squeezed from the caudal epididymis onto a pre-warmed microscope slide (27°C) and two drops of warm 2.9% sodium citrate was added, the slide was then covered with a warm cover slip and examined under the microscope using x400 magnification. Ten fields of the microscope were randomly selected and the sperm motility of 10 sperms was assessed on each field. Therefore, the motility of 100 sperms was assessed randomly. Sperms were labelled as motile, sluggish, or immotile. The percentage of motile sperms was defined as the number of motile sperms divided by the total number of counted sperms (i.e. 100) [9].

Sperm viability (Life/dead ratio): This was done by adding two drops of warm Eosin/Nigrosin stain to the semen on a pre-warmed slide, a uniform smear was then made and dried with air; the stained slide was immediately examined under the microscope using x400 magnification. The live sperm cells were unstained while the dead sperm cells absorbed the stain. The stained and unstained sperm were counted and the percentage was calculated [10].

Sperm morphology: This was done by adding two drops of warm Walls and Ewas stain (Eosin/Nigrosin stain can also be used) to the semen on a pre-warmed slide, a uniform smear was then made and air-dried; the stained slide was immediately examined under the microscope using x400 magnification [10]. Five fields of the microscope were randomly selected and the types and number of abnormal spermatozoa were evaluated from the total number of spermatozoa in the five fields; the number of abnormal spermatozoa was expressed as a percentage of the total number of spermatozoa.

Sperm count: This was done by removing the caudal epididymis from the right testes and blotted with filter paper. The caudal epididymis was immersed in 5 mL formol-saline in a graduated test-tube and the volume of fluid displaced was taken as the volume of the epididymis. The caudal epididymis and the 5 mL formol-saline were then poured into a mortar and homogenized into a suspension from which the sperm count was carried out using the improved Neubauer haemocytometer under the microscope.

Testicular Histology

After removing the testes, they were immediately fixed in Bouin's fluid for 12 hours and the Bouin's fixative was washed from the samples with 70 % alcohol. The tissues were then cut in slabs of about 0.5cm transversely and were dehydrated by passing through different grades of alcohol: 70 % alcohol for 2 hours, 95 % alcohol for 2 hours, 100 % alcohol for 2 hours, 100 % alcohol for 2 hours and finally 100 % alcohol for 2 hours. The tissues were then cleared to remove the alcohol, the clearing was done for 6 hours using xylene. The tissues were then infiltrated in molten Paraffin wax for 2 hours in an oven at 57°C, thereafter the tissues were embedded. Serial sections were cut using rotary microtome at 5 microns (5µm). The satisfactory ribbons were picked up from a water bath (50⁰-55⁰C) with microscope slides that had been coated on one side with egg albumin as an adhesive and the slides were dried in an oven. Each section was deparaffinized in xylene for 1 minute before immersed in absolute alcohol for 1 minute and later in descending grades of alcohol for about 30 seconds each to hydrate it. The slides were then rinsed in water and immersed in alcoholic solution of hematoxylin for about 18 minutes. The slides were rinsed in water, then differentiated in 1% acid alcohol and then put inside a running tap water to blue and then counterstained in alcoholic eosin for 30 seconds and rinsed in water for a few seconds, before being immersed in 70 %, 90 % and twice in absolute alcohol for 30 seconds each to dehydrate the preparations. The preparations were cleared of alcohol by dipping them in xylene for 1 minute. Each slide was then cleaned, blotted and mounted with DPX and cover slip, and examined under the microscope. Photomicrographs were taken at x40, x100 and x400 magnifications

Statistical Analysis

The mean and standard error of mean (S.E.M.) were calculated for all values. Comparisons between the control and the treated groups were done using one-way analysis of variance (ANOVA) with Duncan's Multiple Range Test. Differences were considered statistically significant at p<0.05.

RESULTS

Effect on Body weight

Treatment of rats for fifty days with hydrochlorothiazide (0.36 mg/kg) produced no significant (p>0.05) changes in body weight throughout the duration of treatment (Fig. 1).

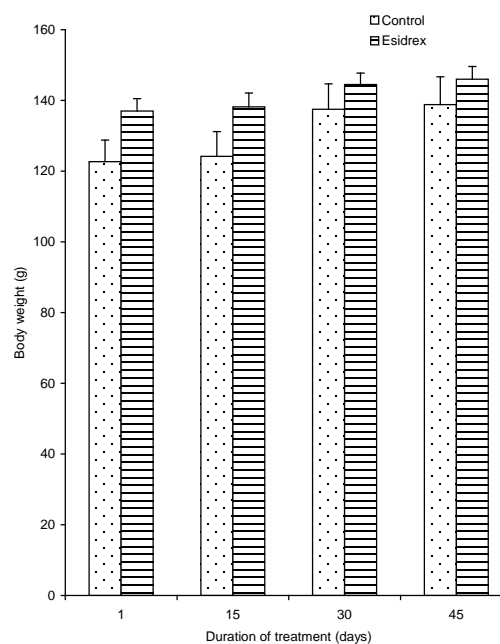


Fig. 1: Body weight changes in control rats and rats treated with hydrochlorothiazide for 50 days (n=6, *p<0.5)

Effect on Plasma Testosterone Level

Treatment of rats for fifty with hydrochlorothiazide (0.36 mg/kg) produced significant (p<0.05) increment in testosterone level relative to control (Fig. 2).

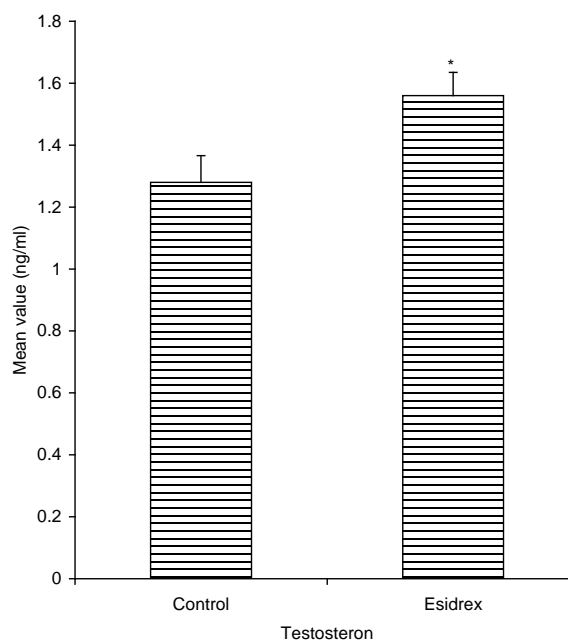


Fig. 2: Effect of treatment of rats for 50 days with hydrochlorothiazide on plasma testosterone level (n=6, *p<0.5)

Effect on Sperm Characteristics

The effect of 50 days treatment of rats with hydrochlorothiazide (0.36 mg/kg) on sperm characteristics are shown in Fig. 3 and 4. Treatment of rats with hydrochlorothiazide (0.36 mg/kg) caused significant ($p < 0.05$) reductions in progressive sperm motility, but produced no significant changes ($p > 0.05$) in the percentage of viable sperms relative to their respective controls. Treatment of rats with hydrochlorothiazide (0.36 mg/kg) caused significant ($p < 0.05$) increase in the percentage of abnormal sperms, as well as induced significant ($p < 0.05$) reduction in sperm count relative to their respective controls.

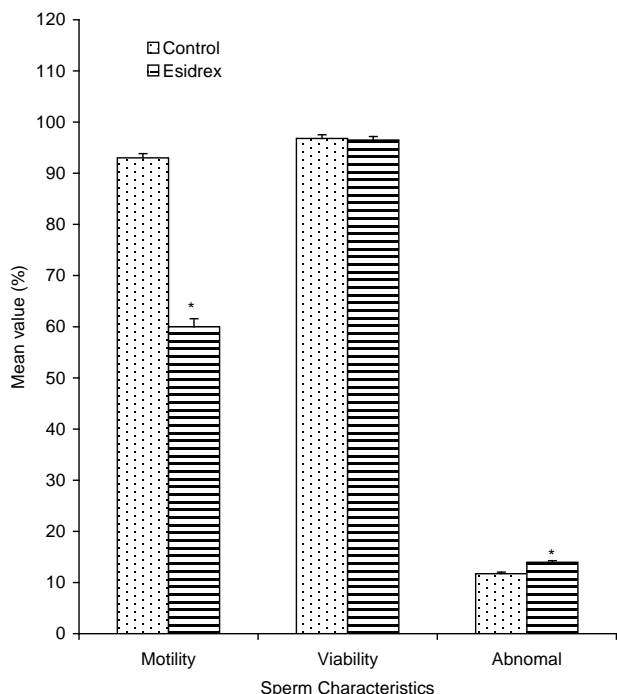


Fig. 3: Spermogram showing the effect of 50 days treatment of rats with hydrochlorothiazide on sperm characteristics (n=6, * $p < 0.05$)

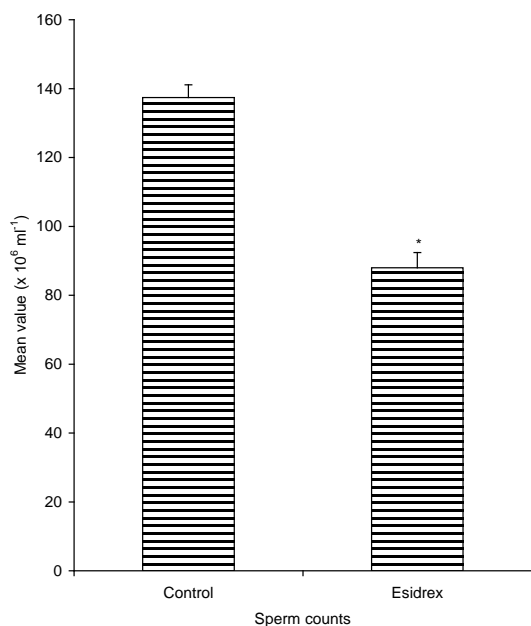


Fig. 4: Spermogram showing the effect of 50 days treatment of rats with hydrochlorothiazide on sperm count (n=6, * $p < 0.05$)

Histopathological Effect

Plates 1 and 2 respectively show the transverse sections through the testes of control rat and rat treated with hydrochlorothiazide (0.36 mg/kg) for fifty days.

Treatment of rats with hydrochlorothiazide (0.36 mg/kg) caused no visible lesion in the testes of rat, which is similar to what was observed in the control rat.

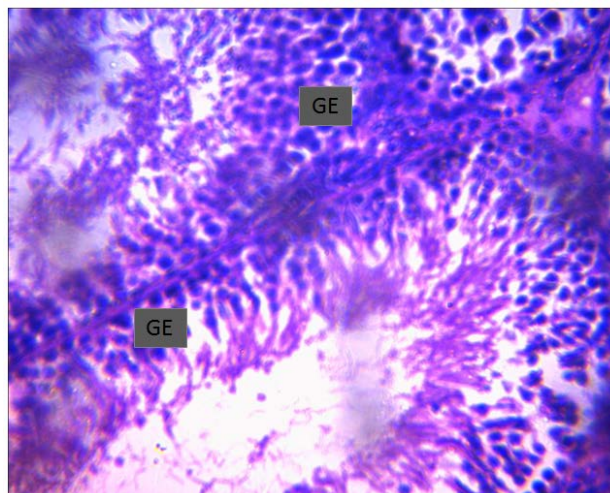


Plate 1: Effect of 50 days treatment of rat with distilled water (control) on rat testis ($\times 400$). Photomicrograph showing normal viable germinal epithelium (GE) with no visible lesion seen.

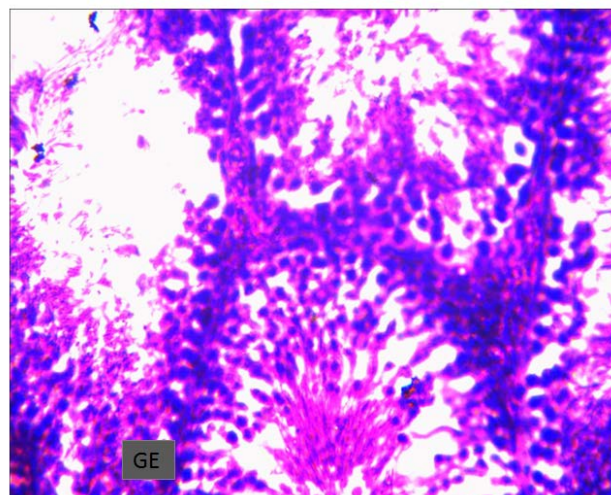


Plate 2: Effect of 50 days treatment of rat with hydrochlorothiazide (0.36 mg/kg) on rat testis ($\times 400$). Photomicrograph showing normal viable germinal epithelium (GE) with no visible lesion seen.

DISCUSSION

This study has shown that the treatment of rats with hydrochlorothiazide caused no significant changes in body weight of rats. This suggests that hydrochlorothiazide was not toxic to the animals [11]. This could also be due to the absence of androgenic property in this drug, since it has been reported that androgens possess anabolic activities [12]. It could also be due to absence of anorectic and lipolytic properties in this drug [13]. Similar result was reported by [14] in *Vernonia amygdalina* extract treated rats. The drug induced significant increase in testosterone level which was not expected. The plausible explanation for this observation could be as a result of direct damage to the testes by atenolol,

since it has been reported that any direct damage to the testis is likely to impair gonadal response to FSH and LH [15]. Contrary report was given by [11] in rats treated with aspirin. This increase in testosterone levels could also indicate that hydrochlorothiazide did not inhibit the mechanism involved in the process of hormone synthesis in the Leydig cells.

Hydrochlorothiazide caused significant decrease in sperm motility. This suggest that the drug was able to permeate the blood-testis barrier with a resultant alteration in the micro-environment of the seminiferous tubules, since it has been reported that the decrease in the sperm motility caused by chemical agents was due to their ability to permeate the blood-testis barrier [16] and thus creating a different micro-environment in the inner part of the wall of the seminiferous tubules from the outer part [17]. Similar report was given by [18] in rats treated with *sarcotemma acidum* extract.

There was an insignificant decrease in sperm viability as well as a significant increase in the percentage of morphologically abnormal sperm cells induced after treatment of rats with hydrochlorothiazide. This could be due to the ability of the drug to either interfere with the spermatogenic processes in the seminiferous tubules and epididymal functions which may result in alteration of spermatogenesis [19, 20]. Similar result was reported by [21] in isolated tetracyclic steroid treated rats.

Sperm count is considered to be an important parameter with which to access the effect of chemicals on spermatogenesis [22]. Spermatogenesis is influenced by the hypothalamic adenohypophysial-Leydig cell system relating gonadotropin releasing hormone, luteinizing hormone and androgen. This implies that the decrease in sperm count caused by hydrochlorothiazide in the treated rats might not be as a result of plasma level of testosterone, because this hormone has been reported to be important in the initiation and maintenance of spermatogenesis [23]. Similar report was given by [24] in *Terminalia chebula* extract treated rats.

Photomicrographs revealed that rats treated with hydrochlorothiazide presented with normal germinal epithelium with no visible lesion. Similar results were reported by [25] in rats treated with *Hibiscus macranthus* and *Basella alba* extracts. This suggests that hydrochlorothiazide has no toxic effect on the exocrine function of the testes at histological level [11].

CONCLUSION

In conclusion, this study has shown that hydrochlorothiazide has spermatotoxic or antispermatogenic effect in male rats. However, the effect of this drug on human reproductive functions is unknown. Nevertheless, considering these findings in animal models, it is recommended that moderation should be exercised in the consumption of this drug by those taking it for therapeutic purposes.

CONFLICT OF INTEREST

We vehemently declare that there is no conflict of interests in this research work.

REFERENCES

- "Hydrochlorothiazide". The American Society of Health-System Pharmacists; 2016.
- Wright JM, Musini VM. First-line drugs for hypertension. The Cochrane database of systematic reviews, 3: CD001841; 2009.
- George JD, Price CJ, Tyl RW, Marr MC, Kimmel CA. The evaluation of the developmental toxicity of hydrochlorothiazide in mice and rats. *Fundam Appl Toxicol* 1995; 26 (2): 174-180.
- Chakraborty M, Kamath JV, Ananya Bhattacharjee A. Potential interaction of green tea extract with hydrochlorothiazide on diuretic activity in rats. *International Scholarly Research Notices* 2014; ID 273908.
- Gagliano-Jucá T, Napolitano M, Del Grossi FCF, et al. Hydrochlorothiazide potentiates contractile activity of mouse cavernosal smooth muscle. *Sex Med* 2016; 4 (2): 113-123.
- Kellinghaus C, Gorji A. Proconvulsive effect of hydrochlorothiazide in an in vitro rat seizure model. *Iranian Journal of Basic Medical Sciences* 2016; 17 (11): 860-866.
- Lijinsky W, Reuber MD. Pathologic effects of chronic administration of hydrochlorothiazide, with and without sodium nitrite, to F344 rats. *Toxicol Ind Health* 1987; 3 (3): 413-422.
- Na KY, Kim GH, Joo KW, et al. Chronic furosemide or hydrochlorothiazide administration increases H⁺-ATPase B1 subunit abundance in rat kidney. *American Journal of Physiology* 2007; 292 (6): 1701-1709.
- Mohammad – Reza P, Farzaneh D, Taherch TK, Zoherb PP. The effects of hydroalcoholic extract of *Actinidia chinensis* on sperm count and motility, and blood levels of estradiol and testosterone in male rats. *Achieves of Iranian Medicine* 2005; 8 (3): 211-216.
- Laing JA (1979): Fertility and infertility in domestic animals. 3rd edition 1979 Bailliere Tindall, a division of Cassell Lt; 1979.
- Oyediji KO, Bolarinwa AF, Adigun AF. Effect of aspirin on reproductive functions in male albino rats. *IOSR Journal of Pharm and Bio Sci* 2013; 4 (6): 49-54.
- Johnson MH, Everitt BJ. Essential reproduction Great Britain: BlackWell Scientific Publication; 1998.
- Carvajal, Zarrabal O, Hayward Jone PM, Orta Flores Z, Nolasco Hipolito C et al. Effect of *Hibiscus sabdariffa l.* dried calyx Ethanol Extract on fat absorption, excretion and body weight implication in rats. *Journal of biomedicine and biotechnology* 2009; 209.
- Oyediji KO, Bolarinwa AF, Azeem AA. Effect of effect of methanolic extract of *Vernonia amygdalina* on reproductive parameters in male rats. *Asian Journal of Pharmaceutical and Clinical Research* 2013; 6 (2): 1-4.
- Braide VB, Agube CA, Essien GE, Udoh FV. Effect of Garcinia Kola seed alkaloid extract on levels of gonadal hormone and pituitary gonadotrophins in rat serum. *Nigeria Journal of physiological Sciences* 2003; 18 (1-2): 59-64.
- Baldessarini RJ. In drugs and the treatment of psychiatric disorders. The pharmacological basis of therapeutics Ed. By Goodman and Gilman. Macmillan Pub. Co. Inc, 301-417; 1980.
- Bloom W, Fawcett DW. Male reproductive system. In the textbook of Histology. Saunders Company, Philadelphia; 1975.
- Verma PK, Sharma A, Annu M, Prachi S, Gupta RS, Joshi SC, Dixit VP. Effect of *Sarcostemma acidum* stem extract on spermatogenesis in male albino rats. *Journal of andrology* 2002; 4 (1): 43-47.
- William KW. Hormones and Hormone antagonists. In: Remington, The Science and Practise of Pharmacy, vol 11, 20th edition, 77: 1390-1391; 2000.
- Bowman WC, Rand MJ. The reproductive system and drugs affecting the reproductive systems. Textbook of pharmacology, 2nd edition, 20: 1-8; 1985.
- Oyediji KO, Bolarinwa AF, Oladosu IA. Effect of isolated tetracyclic steroid constituent of *Portulaca oleracea* on reproductive parameters in male rats. *Asian Journal of Pharmaceutical and Clinical Research* 2013; 6 (2): 222-226.
- Reddy PS, Pushpalatha T, Reddy PS. Reduction of spermatogenesis and steroidogenesis in mice after fentin and fenbutatin administration. *Toxicology Letter* 2006; 166: 53 – 59.
- Christensen AC. *Leydig cell*: In: Handbook of Physiology, edited by P.O. Greep and E.B. Astwoods. Washington D C American Physiological Society; 1975.
- Krishnamoorthy P, Vaithinathan S, Rani V, Bhuvanewari A. Effect of *Terminalia chebula* fruit extract on lipid peroxidation and antioxidative system of testis of albino rats. *African Journal of Biotechnology* 2007; 6 (16): 1888 – 1891.
- Moundipa FP, Kamtchouing, Koueta N, Tantchou J, Foyang NPR, Mbiapo FT. Effects of aqueous extracts of *Hibiscus macranthus* and *Basella alba* in mature rat testis function. *Journal of ethnopharmacology* 1999; (65): 133 – 139.