

Some microscopic observations of submandibular salivary gland in the Ferret (*Mustela putorius furo*)

¹Zainab Sajid Mohammed; ²Widad Adid Gawad ; ³Manar Mohammed Husan ; ⁴Abdulahdi Sallal Mohammed

¹Ahlulbait university/Iraq / ²College of Pharmacy , University of Al-Qadissiya/ College of Dentistry/Iraq ,

³Babylon University / College of science for women/Iraq ,

⁴AL_Furat AL_Awsat Technical University /Faculty of Medical and Health Techniques Kufa/Iraq.

Abstract:

The present study was conducted on six adult males ferret . Anatomical description of submandibular glad was oval-shaped, located under mandible, pair gland, occupied the cervical region. Histologically , submandibular gland was compound-tubulo-branched acinar gland, composed of fibrous capsule, send trabeculae to divide the pranchyma of gland into lobes and lobules , histological findings was revealed , mixed gland (sero-mucos), consist of mucous and serous acini, the predominant acini was mucous and less serous acini in the number, some time the serous acini was appeared as demuline, the epithelial lining of secretory acini was pyramidal epithelial cells. the ductal system included, intralobular, interlobar and main duct, the intralobular and interlobar ducts lined by simple cuboidal epithelium, while the main duct lined with stratified or simple cuboidal epithelial cells. myoepithelial cells were warped the mucous, acinus and ducts of submandibular salivary gland in the ferrer, function of myoepithelial cells ha contractile function to expel the salivary secretions from acini into ductal system of gland.

Keywords: Ferret, Submandibular , Salivary glands, ductal system.

INTRODUCTION

Main and minor salivary gland, enclosed by a fibrous capsule, which send septa to pranchyma to divide into lobes and lobules, the salivary glands are consist of three type of epithelial cells, myoepithelial cells, acinar cells and ductal cells (1,2).

Most abundant acini in the human submandibular salivary gland was serous acini, the rodent sublingual salivary gland composed of mucous acini which located in the center of gland while sero-mucous acini occupied at periphery (3). The secretions of the salivary glands can be distinguished into serous, mucous and seromucous acini, the acini of the salivary glands classified into three types , serous acinus lined by small pyramidal epithelial cells with basophilic granules , these cells had spherical nucleus which located near the basement membrane, sero-mucous acinus had serous demulinus as crescent enclosed the large mucous part, while the mucous acinus lined with columnar epithelium had flatten nucleus which located near to basement membrane (4).

The salivary glands histology of mammalia consisted of three kinds of main compound tubylo acinar gland, which included paroted, sublingual and submandibular and sublingual salivary gland were mixed; sero-mucous glands (5). The salivary glands secretion which represented by saliva that led to moisten the buccal mucosa and lubrication of the food before swallowing (6). The secretory acinar cells were enclosed by myoepithelial cells, the ductal system of submandibular gland composed of intrcalated , intralobular that lined by simple columnar or simple cuboidal epithelium , the excretory duct which lined by stratified cuboidal epithelium (7). The aim of this present study was focused the light on the histological structure of the sub-mandibular salivary gland in ferret , and compared with other mammalia.

MATERIALS AND METHODS

Six adult males Ferret (*Mustela putorius furo*) were captured in the Agriculture area around the Technical Institute /Kufa , in the period extend from February to December (2010). In this study was used metal cage traps, the animals were immediately transformation into histology and anatomy laboratory of medical laboratories department in this Institute . the adult males Ferret were anaestathized with chloroform by inhalation method. Each Ferret was scarified on the procedure (8). The animals were

placed on the dorsam, after recumbency, the incision through mid line in the ventral side, the incision was extended from the mandibular area to inguinal region, then dissection of the submandibular salivary glands were removed from Ferret body, the specimens of gland fixed with (10%) formalin for period (48)hrs., the histological specimen was passed through serial graduated ethanol alcohol, then clearing with xylo, after that impregnation and embedding in the paraffin , and sectioning was carried out at six micrometers thick, and staining with hmatoxylin and eosin (9).

RESULTS

Two pairs of submandibular salivary gland in the Ferret left and right gland was located under the lower jaw in the cervical region. The histological observation was appeared, compound branched tubulo-acinar gland , which enclosed fibrous capsule (figure 1) , the capsule consist of collagenous fiber with large arteries and veins , the septi of capsule extended through the pranchyma which led to division of the gland into lobes and lobules (figure 4).

The ductal system of submandibular gland in the Ferret was included, intralobular duct, interlobar duct and main duct (figure 1,2,3,5), the epithelial linings of intralobular and interlobar duct lined by simple cuboidal epithelium , while the main duct lined by stratified cuboidal and simple cuboidal cells, the epithelial lining of the main duct that surrounded by smooth muscle fibers was appeared as delicate fibers, their function led to press on the gland to release their secretion . the resent study observations revealed , the submandibular gland in the Ferret , was sero-mucous mixed gland, histology of this gland composed from mucous acini and serous demulinus or spareated acinus, the mucous acini appeared large acini lined by pyramidal secretory cells, had flatten nuclei which located near the basement membrane of glandular cells, the lumen of mucous acinus filled with mucous secretions appeared as vacuoles, while the serous acini were small , also lined secretory pyramidal epithelial cells. the serous demulinus like crescent shape enclosed the mucous acinus. Both mucous and serous acini which myoepithelial cells , these cells warped the acini, and their function similar to smooth muscle cells were carried out contraction to release mucous and serous secretions into the ducts.

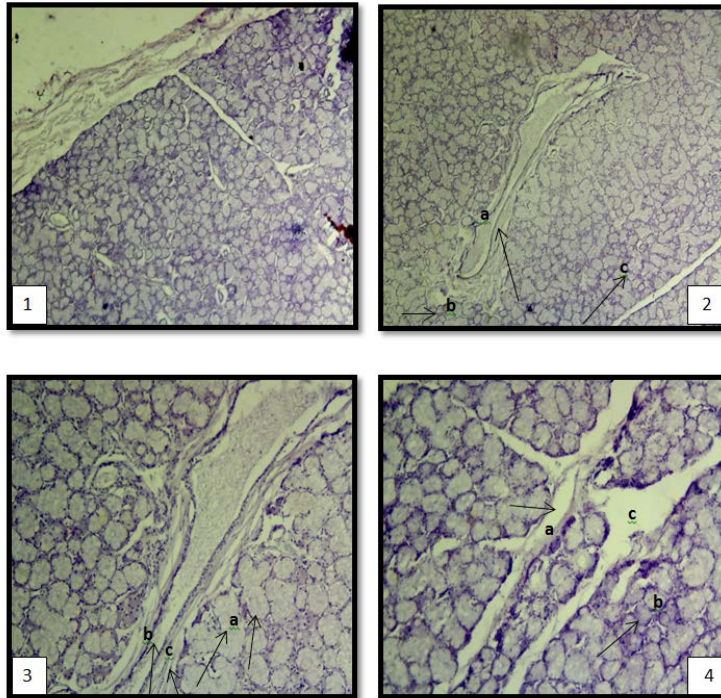


Figure 1:The submandibular gland of ferret surrounded by fibrous capsule, (a) it send spetules to divide the gland into lobes (b) to divided the gland in to (c)lobes (d) lobules (e) the intralobular duct which located in the side the lobule . **4x (H&E).**

Figure 2:Submandibular gland of ferret showed (a) the main duct surrounded by connective tissue (b) the submandibular gland of ferret consisted of lobes (c) lobules and (d) intralobar duct. **4x (H&E).**

Figure 3:Revealed submandibular salivary gland of ferret composed of (a) lobes and lobules (b) ductal system consisted of main salivary duct (c) enclosed by loose connective tissue (d) intralobular duct. **10x (H&E).**

Figure 4:Revealed ferret submandibular glands (a) lobes and lobules , and capsule send septa. (b) lobes (c) lobules. **4x (H&E).**

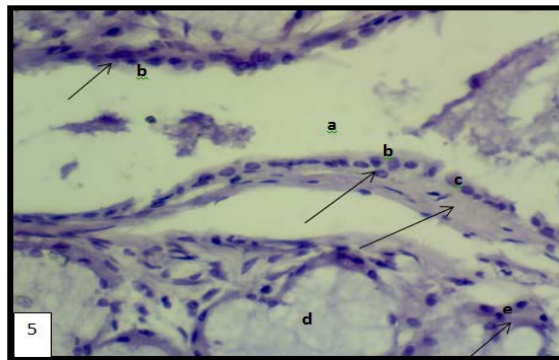


Figure 5: Showed the main duct of ferret salivary submandibular gland (a) gland lined by simple cuboidal epithelium (b) the duct which surrounding by muscular tissue (c) main duct located between lobes, it is composed of mucous acini (d) serous demuline . **40x H&E.**

Figure 6: Showed the ferret salivary submandibular gland mixed compound tubule-acinar gland composed of (a) mucous acini (b) serous acini (c) the acini that surrounded by myoepithelial cells. **10x H&E**

Figure 7: Showed the ferret salivary submandibular gland (a) myoepithelial cells that enclosed large mucous acinus (b)serous demulinus which surrounded small mucous acinus (c)vacuoles of mucous secretion (d) intralobular duct . **10x H&E**

DISCUSSION

The Ferret was one of sixty –five members in Mustelidae family (10). The domestic Ferret live and distributed in the western north American and European (11), the submandibular salivary gland in the Ferret covered with fibrous connective tissue , these observation was corresponded with previous study on hamster sunmandibular gland (12). The Ferret submandibular gland composed of two lobes which located in the cervical area these findings was agreement with (13) in the Ferret , mentioned the Ferret submandibular gland found single on the left and right side. Our observations revealed , the predimonant acini was mucous and less serous acini, some serous acini was as crescent shape enclosed the mucous acini, the present study was differed with previous study (14). The predimonant acini was mucous in human submandibular salivary gland. The intercalated and striated in the salivary gland were termed, the interalobular ducts , the secretory acini which enclosed by myepithelial cells, these cells had contractile function to assist expelion of secretion from secretory acinar cells and push secretion through ductal system of gland, these suggestions were accordance with (15). The salivary reservoir was absent in the Fereet submandibular salivary gland, while found in the mucous and some rat species (16) the identified a salivary reservoir was located adjacent the oral termination of main salivary duct of submandibular gland. Some resent works about carnivorous submandibular salivary gland was conducted on the wild Carnivra animal such as (*Millivora capenesis*) to identify the gross and histological structure of submandibular gland (17), they observed the submandibular gland in *Millivora* was mixed gland (muco-serous) these observations were similar to this present study especially about secretory units and ductal system of Ferret submandibular gland.

REFERENCES

- Denny, P.C.; Ball, W.D. and Redman, R.S. (1997).Salivary glands:paradigm for diversity of gland development .crit.Rev. Oral Bio. Med.; 8: 51-75.
- Amano, O.; Mizobe, K.; Bando,Y. and Skiyama,K. (2012).Anatomy and histology of rodent and human major salivary glands:Overview of the Japan salivary glands society-sponsored workshop. Acta Histochem, Cytochem; 45:241-250.
- Hand, A.R.; Pathmanathan, D.; and Field, R.B. (1999).Morphological features of the minor salivary glands.Arch. Oral.Bio.; 44: 3-10.
- Christine; Angelic, B.and Jason, P. (2016).Aquaporins in salivary glands: Form Basic Research to Clinical Applications.Int.J.Mol. Sci.; 17: 1-13.
- Siliva,E; Stella, M. and Emma, B. (2005). Histological study of the salivary glands in *Zaedyus pichiy* (Mammalia, Xenarthra, Dasypodidae). Int.J. Morphol.; 23:19-23.
- Vissink. A.; Mitchell, J.; Baum, B.; Limes and K.; Jensen, S. and Fox, P. (2010).Clinical management of salivary gland hypofunction and Xerostomia in head and nech cancer patients: Successes and barriers Int.J. Radiat Oncol. Biophys.; 78:983-991.
- Ikpegbu, E.; Nlebedum, U.; Nnadozie, O. and Agbakwuru, I. (2013).The submandibular salivary gland microscope morphology of the adult African gaint pouched rat (*Cricetomys gambianus*, Water house-1840) .Iranian Journal of Veterinary Medicine.; 7: 117-122.
- Adeyemo, O. and Oke, B. (1990). Comparison of the testicular and epididymal proteins of the African gaint rat (*Cricetomys gambianus*). And laboratory rats. Tropic Vet.; 8: 17-27.
- Bancroft, J. and Steven, A. (1977).Theory and practice of histological techniques. Churchill livingstone, Newyork. USA.PP:88-89.
- Anderson, E.(1989).The phylogeny of mustelids and the systematics of Ferret. In: Seal US .Throne ET , Bogan MA, Anderson SH(eds.), Conservation Biology and the Black-Footed Ferret . New Haven, CT: Yale University Press, PP: 10-20.
- Fox, J. (1998).Taxonomy , history and use .In: Fox JG of the Ferret .Baltimore: William & Wilkins; 3-18.
- Khojastech, S.M. and Delashoub , M.(2012).Microscopic anatomy of the parotid and submandibular salivary glands in European hamster.; 3: 1544-1548.
- Poddar, S. and Jacob, S. (1977).Gross and microscopic anatomy of the major salivary glands of the Ferret acta Anatomica, 98: 434-443.
- Amano, O.; Mizoba, K.; Yasuhiko, B. and Koji, S. (2012). Anatomy and histology of rodent and human major salivary glands. Acta Histochem, 45: 241-250.
- Redmam, R.(1994). Myoepithelial cells of salivary glands. Acta Microscop. Res. .Tech.; 287: 25-45.
- Matsuoka, T.; Aiyama, S.and Hanawa, E. (1994). Ampulla in the main excretory duct of the mouse submandibular gland .Histological and three dimensional examination. JPN. J. Oral Biol; 36: 536-541.
- Abdulhadi; S. M. ; Tawfeeq, J.A. and Yussra, H.A.(2011).Gross And Microscopic Description of Submandibular Salivary gland of (*Millivora Capenesis*)