

The ratio of collagen types I/III as a marker of skin aging and prognosis of aesthetic facial surgery results

N.E. Manturova¹, G.O. Smirnova¹, V.A. Stupin¹, E.V. Silina²

¹Pirogov Russian National Research Medical University, Ostrovityanova Str., 1, Moscow 117997

²I.M. Sechenov First Moscow State Medical University, Trubetskaya Str., 8, Moscow, 119991

Abstract

Scope is to study the skin aging mechanisms with varying proportions of collagen type I/III to formulate the criteria for forecasting the results of surgical aesthetic interventions.

Material and methods: Morphological features of the skin have been studied in 20 women aged 45 to 60 years, defined after surgical interventions performed for the reason of the 2nd-3rd degree of involuntary changes in the facial skin. The emphasis has been made on the collagen type I/III ratio. A complex of morphological methods, including light and transmission electron microscopy, has been used.

Results. An important link of the pathogenesis of progression of involutory changes in the facial skin - a reduced ratio of collagen type I/III was defined, indicating the connective tissue pathology. The progress of involutory changes, deformation type of facial aging, and early development of ptosis have been more rapid in patients with reduced collagen type I/III ratio. Histological examination of these patients noted the presence of giant fibroblasts, as well as those with increased synthetic activity, which indicated the immaturity of connective tissue. Repeated aesthetic facial surgeries were performed on these patients 6 times more often (relative to those with a normal ratio of collagen type I/III) for a 7-9 years period.

Keywords: aging, aesthetic surgery, antiaging therapy, collagen, lifting.

INTRODUCTION

Aging of soft facial tissues is part of the overall biological aging process and is determined by the same laws. Age-related skin changes occur usually after 35 years: epidermal layer thinning occurs, the skin becomes loose, drier due to violations of hydrobalance, microcirculation, the layer of collagen and elastin fibers in the dermis becomes thinner, wrinkles appear together with folds, gravitational ptosis progresses [1-3]. While in patients aged 40-50 nonsurgical correction options can give a nice effect and allow maintaining the homeostasis of the skin at a younger level, the issue of the surgical intervention arises in most patients of older age groups with the deformational type of aging.

A good clinical result after surgery is guaranteed to the patient within 7-10 years. Why is it possible to reach the long-lasting results for some patients, while for others the results are not so despite all the efforts of the surgeon, the correct volume of surgical intervention, and the absence of complications? A good immediate effect of surgical intervention is observed, but in 3-5 years the ptosis of soft tissues progresses, and a repeated surgery becomes necessary [4-6]. Why do some patients aged 50-60 have a fine wrinkled type of aging, and others - deformation accompanied by a pronounced gravitational ptosis? Perhaps the answer to these questions is related to the features of aging of the skin and connective tissue in general, namely collagen.

Collagen is the most abundant protein in mammals, the basic building material of the extracellular matrix, representing 25-35% of the total protein mass. It is collagen that provides the elasticity and strength of the skin. Mass fraction of collagen in tissues depending on their function varies from 10 to 80%, while the greatest amount of it is contained precisely in the skin, which in the adult person is mainly represented by mature collagen type I, and much less falls on the collagen type III [7-10]. Change in the normal ratio of collagen type I and III in the facial skin can cause premature aging.

The **scope is to** study the skin aging mechanisms with varying proportions of collagen type I/III to formulate the criteria for forecasting the results of surgical aesthetic interventions.

MATERIALS AND METHODS

Morphological features of the skin have been studied in 20 women aged 45 to 60 years, defined after surgical interventions performed for the reason of the 2nd-3rd degree of involuntary changes in the facial skin (SMAS lifting, SMAS

lifting in combination with lower blepharoplasty). Surgical interventions were performed for two of them repeatedly, 3.5-5 years after subcutaneous lifting by a standard procedure.

A complex of morphological methods of research, including light and transmission electron microscopy, has been used in the paper. In order to identify morphological maturity, the density of the location and the main types of collagen, sirius dye red coloring was carried out. The preparations were studied in polarized light. The microphotographs obtained in electronic format were analyzed in the Image Pro Plus, where a set of calculations was carried out to determine the ratio of the pixels of red (collagen type I) and green (collagen type III) color ranges.

A telephone interview was performed in 4 years for the final evaluation of the repeated surgical interventions.

RESULTS

The study has revealed that 8 patients in the study group (including 2 reoperative ones) with involutory skin changes of the 3rd degree and pronounced ptosis before surgery (deformation aging type) had a congenital pathology of connective tissue due to a relative surplus of immature collagen type III with weak strength characteristics. This led to a decrease in the ratio of mature collagen type I to type III and a decrease in the strength of connective tissue. The ratio of collagen type I/III in these patients was on average (Me) 3.68. In the remaining 12 patients, the average collagen type I/III ratio was (Me) 4.18, which was 1.14 times more. The majority (83.3%) of patients in this subgroup had type 2 involutory changes with no pronounced ptosis of soft facial tissues and no clinical signs of connective tissue pathology. This was confirmed by the inherent nature of the pathology of connective tissue.

This assumption had been confirmed by the study of preparations colored with red sirius dye in polarized light; collagen type I had been represented by red, closely packed fibrils. Immature collagen type III looked thinner and had green color. Microscopic examination revealed that the connective tissue in patients with the 3rd degree of involutory changes of facial tissues had a different diameter, and collagen fibers formed reticulated fibrous or parallel fibrous architectonics. It was noted that with both types of collagen fibers' organization, an increase in the content of fine beams giving a green glow was observed in a number of cases, which indirectly indicated an increase in the content of collagen type III (Fig. 1).

For a detailed assessment of the relationship between the collagen types and the types of skin aging, the severity and degree of progression of involuntional changes, the frequency of repeated operations and the morphological characteristics of the skin in both subgroups, the preparations of the patients were divided into 2 subgroups, depending on the change in the ratio of collagen type I and III: subgroup A - normal collagen type I/III ratio (Me = 4.18), 12 patients; subgroup B - decreased collagen type I/III ratio (Me = 3.68), 8 patients.

It was found that subgroup B patients with a decreased ratio of collagen type I/III had faster progression of involuntional changes, deformation type of aging of soft facial tissues, and the adverse results of aesthetic facial interventions could be predicted for this group: 2 out of 8 patients (25%) were reoperated, and the second lifting was performed only 3.5-5 years after the first one. In addition, it was the subgroup where a significantly increased frequency of varicose vein disease of lower extremities and hernias of different localizations (50% of patients), as well as obesity of the 2nd-3rd degree (62.5%) were revealed. This confirmed the assumption of the similarity of this pathology and indicated the weakness of connective tissue (Table 1).

Histological examination of biopsy material of A and B subgroup patients enables noting that skin involuntional changes affect all of its divisions, including derivatives. The morphological analysis allowed revealing the following changes in the epidermal and subepidermal zone, similar to both subgroups: thinning of the epithelial layer due to the decrease in spinous and granular layers; reduction in the number and size of epidermal spines, which gave a smooth papillary pattern. Moderately pronounced acanthosis, keratosis had been detected in the epidermis, and spongiosis - in spinous and granular layers. The boundary between the epidermis and the dermis was almost flat. The electron microscopic level of the study revealed the thinning of all the components of the dermo-epidermal connections, which was typical for involuntional skin changes in patients of the older age group.

The number of cells in the dermis had been reduced dramatically, while fibroblasts had become the predominant dermis cells among which several types could be conditionally distinguished, different for subgroups A and B. In subgroup A, the fibroblast population was represented by both functionally active forms and cells with reduced synthetic activity; cells with destructive changes and single fibroblasts containing lipofuscin and fat had been frequently met (Fig. 2).

In the skin of patients of subgroup B with an impaired ratio of collagen in addition to cells with different severity of destructive and dystrophic changes, the giant fibroblasts were present, in the cytoplasm of which there were thread filaments of great length and variable thickness, located along the entire cell,

as well as fibroblasts with increased synthetic activity, which was not typical for the skin of patients of this age group and indicated the immaturity of connective tissue (Fig. 3).

It is worth noting that in the morphological study another feature of the skin of subgroup B patients was the lack of macrophages in tissue. The weakening of the macrophage reaction could be a manifestation of one of the factors of pathological regeneration of the connective tissue.

The data obtained on the morphological and functional heterogeneity of fibroblast population were a good criterion to characterize the degree of the tissue maturity and its potential in the various processes of morphogenesis, including regenerative ones.

The results of the telephone interview conducted 4 years after this study allowed to confirm the unsatisfactory prognosis of surgical aesthetic interventions in patients with diseases of the connective tissue and reduced correlation of collagen type I/III. 2 patients from subgroup B (25%) underwent reoperations in the facial area during this period, and in subgroup A only 1 (8.3%) patient was reoperated. Thus, for the period of 7-9 years, the results of surgical aesthetic interventions were unsatisfactory in 1 (8.3%) of women of subgroup A and in 4 (50%) of patients of subgroup B, which was 6 times higher ($p < 0.05$).

DISCUSSION

The study allowed revealing an important link in the pathogenesis of the progression of involuntional changes in the facial skin - a reduced ratio of collagen type I/III. This indicated pathology of connective tissue and reduction in the strength of connective tissue. The progress of involuntional changes, deformation type of facial aging, and early development of ptosis had been more rapid in patients with the decreased collagen type I/III ratio.

Modern studies allowed revealing an increase of procollagen III in the matrix RNA (mRNA) and a normal or slightly increased amount of procollagen I mRNA in skin fibroblasts in case of involuntional skin changes. The number of metalloproteinase (enzymes, modifying the immature collagen type III in mature one) and their genetic predecessors (mRNA) was the same for the persons with the first, second and third degree of involuntional changes. The above facts indicate a genetically determined violation of collagen synthesis.

The revealed features of involuntional changes in tissues allow considering the aging process of the dermis not only as a result of genetically determined changes in cells associated with a decrease in metabolism, a violation of microcirculation and tissue trophism, but also as one of the possible options of skin dysregeneration, which includes the elements and mechanisms of recovery, similar to embryonic histogenesis of connective tissue.

Table 1. Link of the type of aging, the progression of involuntional skin changes with the connective tissue pathology

| | Subgroup A, normal collagen type I/III ratio (n=12) | Subgroup B, decreased collagen type I/III ratio (n=8) | p (X2 criterion) | Total |
|--|---|---|------------------|----------------------|
| Aging type: - deformation; - mixed (fine-wrinkled) | 2 (16.7%) 10 (83.3%) | 8 (100%) 0 | <0.05 | 10 (50%) 10 (50%) |
| Involuntional changes - 3rd degree with pronounced ptosis - 2nd degree | 2 (16.7%) 10 (83.3%) | 8 (100%) 0 | <0.05 | 10 (50%) 10 (50%) |
| Obesity | 1 (8.3%) | 5 (62.5%) | <0.05 | 6 (30%) |
| Hernias | 0 | 4 (50%) | <0.05 | 4 (20%) |
| Lower extremity varicose vein disease | 0 | 4 (50%) | <0.05 | 4 (20%) |

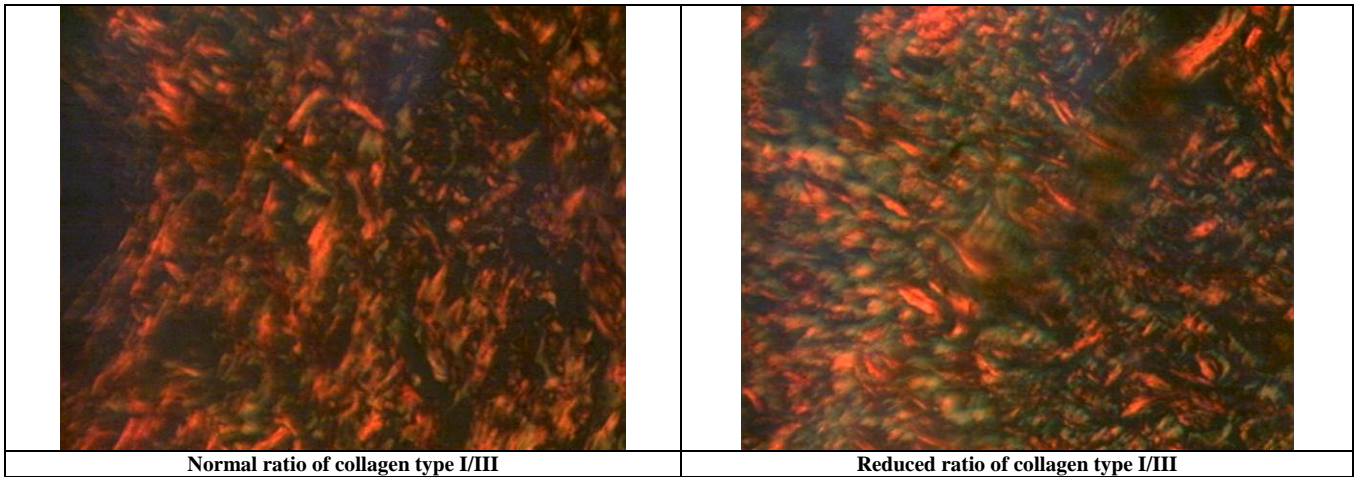


Fig. 1. Electron microscopy of the skin of patients with a normal and decreased ratio of collagen type I/III (coloring with red sirius dye in polarized light)

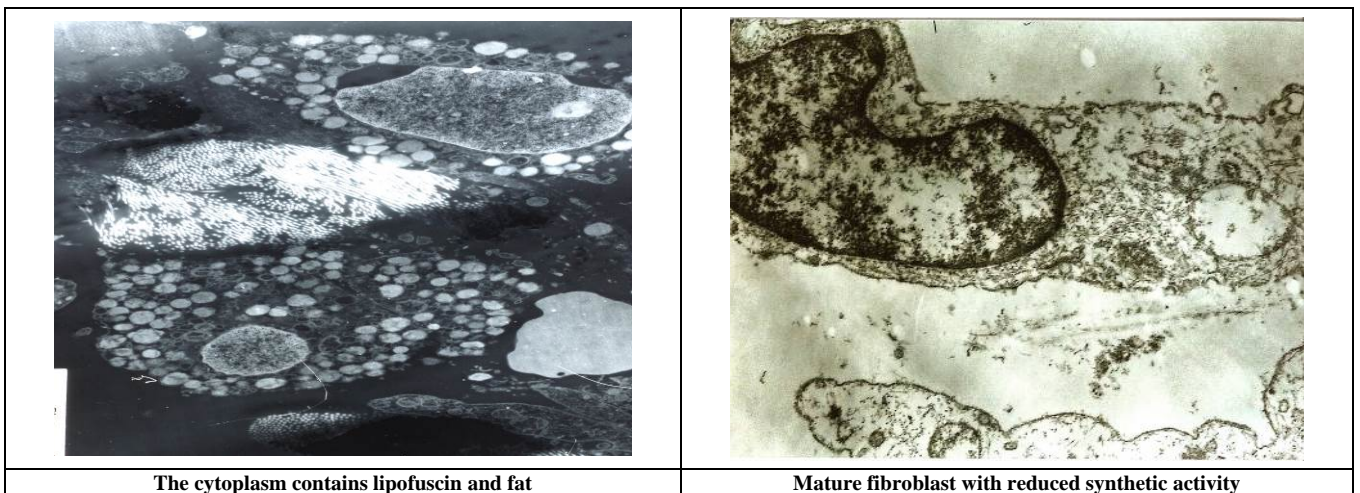


Fig. 2. Electron microscopy of the fibroblastic series cells with dystrophic-destructive changes, characteristic for subgroup A

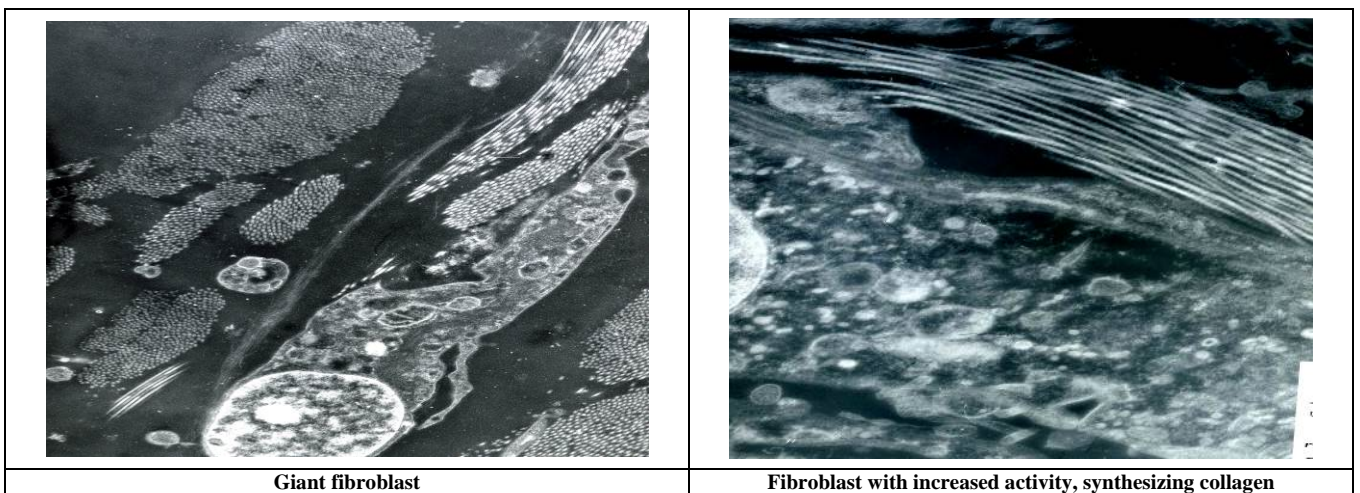


Fig. 3. Electron microscopy of the fibroblastic series cell with dystrophic-destructive changes of varying severity, characteristic for subgroup B

CONCLUSION

Thus, it can be concluded that in patients with decreased collagen type I/III ratio (less than 4), it is possible to predict the adverse results of aesthetic facial interventions.

REFERENCES

1. Alexis, A.F., Obioha, J.O., Ethnicity and Aging Skin, *J. Drugs Dermatol.* 2017, 16(6), s77-s80.
2. Kanaki, T., Makrantonaki, E., Zouboulis, C.C., Biomarkers of skin aging, *Rev. Endocr. Metab. Disord.* 2016, 17(3), 433-442.

3. Longo, C., Well-aging: Early Detection of Skin Aging Signs, *Dermatol. Clin.* 2016, 34(4), 513-518. DOI: 10.1016/j.det.2016.05.014.
4. Garnham, B., Designing 'older' rather than denying ageing: problematizing anti-ageing discourse in relation to cosmetic surgery undertaken by older people, *J. Aging Stud.* 2013, 27(1), 38-46. DOI: 10.1016/j.jaging.2012.11.001.
5. Silina, E.V., Manturova, N.E., Mamedov, E.V., Smirnova, G.O., The clinical and laboratory evaluation of the facial skin state after surgical correction, *Khirurgiia* 2012, 6, 45-49.
6. Strong, B., Sainsbury, D., Hodgkinson, P., Ragbir, M., Williams, N., Aesthetic day surgery safety in a UK facility: A 4 year retrospective study and discussion of the literature, *J. Plast. Reconstr. Aesthet. Surg.* 2018, 71(5), 769-770. DOI: 10.1016/j.bjps.2017.11.028.
7. Bella, J., Hulmes, D.J., Fibrillar Collagens, *Subcell Biochem.* 2017, 82, 457-490.
8. Silina, E.V., Stupin, V.A., Gabitov, R.B., Collagen role in the mechanisms of chronic wounds healing diabetic foot syndrome, *Klinicheskaya Meditsina* 2018, 96(2), 106-115. DOI: <http://dx.doi.org/10.18821/0023-2149-2018-96-2-106-115>.
9. Mienaltowski, M.J., Birk, D.E., Structure, physiology, and biochemistry of collagens, *Adv. Exp. Med. Biol.* 2014, 802, 5-29. DOI:10.1007/978-94-007-7893-1_2.
10. Deshmukh, S.N., Dive, A.M., Moharil, R., Munde, P., Enigmatic insight into collagen, *J. Oral. Maxillofac. Pathol.* 2016, 20(2), 276-283. DOI: 10.4103/0973-029X.185932.