

Effects of Atorvastatin Drug *in* Albino Male Rats

Sarah .H. Jabir and Haider salih Jaffat*

Department of Biology, Faculty of Sciences, University of Kufa, Iraq

Abstract

Background: Statins, which are inhibitors of 3-hydroxy-3-methylglutaryl-CoA (HMG-CoA) reductase, are considered as one of the most important drugs and the drug of choice for reducing an abnormal cholesterol level. Statins are normally used to decrease the risk of coronary heart disease (CHD), but they tend to be associated with liver adverse effects. The objective of this prospective study was to investigate the effect of atorvastatin therapy on the liver function.

Methods: Study comprised of male albino rats (n=55). Where randomly divided in to a control group (standard diet), atorvastatin 20 mg/kg groups, atorvastatin 40 mg/kg groups, Ator 20 mg/kg+Vit.c 150mg and Ator 40 mg/kg+Vit.c 150mg .after period 30 days half number from each group were sacrifice, and after 60 days another rats were sacrifice.

Results: Compare with the control group , in atorvastatin groups for two periods can effect by significant increase ($p<0.05$) in activities of liver enzymes alkaline phosphatase (ALP), aspartate transaminase (AST) and alanine transaminase (ALT) and increase level of HDL but decrease (LDL,VLDL,TC and TG) and histological examination of liver showed that showed hepatocyte necrosis, sinusoidal vessels congestion and cytoplasmic vacuolization, but in other group (Ator+ vitamin c) can improve the results and decrease the damage effect of atorvastatin on liver.

Conclusion: Atorvastatin can cause increase in levels of liver enzymes alkaline phosphatase (ALP), aspartate transaminase (AST) and alanine transaminase (ALT)) and increase level of HDL but decrease (LDL,VLDL,TC and TG)and histological examination of liver showed that showed hepatocyte necrosis, sinusoidal vessels congestion and cytoplasmic vacuolization. But ascorbic acid (vitamin c) caused recover the results and reduction injury of liver tissues.

Keywords: Atorvastatin , Ascorbic acid, Statins.

INTRODUCTION

Atorvastatin inhibits hydroxy-3-methylglutarylcoenzyme A (HMG-CoA) reductase, an enzyme located in hepatic tissue that produces mevalonate. Mevalonate is a molecule used in cholesterol synthesis Inhibition of HMG-CoA reductase lowers the amount of cholesterol produced, which in turn lowers the total amount of Low density lipoproteins –cholesterol (LDL-C). It also decreases de novo cholesterol synthesis, increasing expression of Low density lipoproteins receptors (LDLRs) on hepatocytes This increases LDL uptake by the hepatocytes, decreasing the amount of LDL-C in the blood [1]. Reactive oxygen species (ROS) are chemically reactive molecules produced by living organisms as a result of normal cellular metabolism. At low to moderate concentrations, they function in physiological cell processes. However, when present in high concentrations, they produce adverse modifications to cell components, such as lipid, protein, and deoxyribose nucleic acid (DNA)[2,3]. Antioxidants is molecules have important role in suppression oxidation of other molecules, have biological role in the body is very important for protection against oxidative damage, thus prevention from cardiovascular, carcinogenic, neurological diseases and delaying chronic health problems like cataracts[4,5]. Vitamin c It's a powerful antioxidant, which act in aqueous environments of the body . As it cannot be synthesized in human, it must be obtain from the diet [6] The liver is structurally and functionally heterogeneous and has been considered second only to brain in its complexity Being the "main extracellular compartment" for adult vertebrates, the liver has thousands of vital functions including the efficient uptake of amino acids, carbohydrates bile acids, cholesterol, proteins, lipids and vitamins for storage and metabolism subsequent to release into bile and/or blood [7]

MATERIALS AL METHODS

Well adult albino male rats, (*Rattus norvegicus*) considering between 205-300 g, were gained from animal house in the Faculty of Pharmacy, University of Baghdad, Iraq, and used in the education. The animals were housed in the animal house of Faculty of Science, University of Kufa, in a typical situation contains (degree of temperature 22-28 °C) and exact circumstances to normal laboratory nutrition with profitable diet (pellets) and water providing to animals through the two ages of the experiments. One protracted to 4 weeks and the second period lengthy to 8 weeks. Rats were left to adjust for at smallest three

weeks before the jump of the trial. None of the rats had any clinically obvious contagions, Fifty sexually mature male rats were randomly divided into five groups (5 rats in each group). Three groups of experimental rats, was specified Atorvastatin vocally by gavage needle for three times each week, and the Atorvastatin was given orally by gavage needle daily in two conc. (20, 40mg/kg) rats randomly divided in to five groups(Standard diet), Ator20 mg/kg, Ator40 mg/kg, Ator 20mg/kg+Vit.c 150mg and Ator 40mg/kg+Vit.c 150mg d 0.071mg of atorvastatin 20mg and served as positive control group.

Collection of blood sample

At the finish of experimentations (after 8 weeks), weight of animal of this education was record. Each animals was anaesthetiz by a mixture of xylazine 0.2 ml and ketamine 0.1 ml and they were scarifi. [8] It was instaled on a box of cork pin by then was drawing blood from the heart directly by Heart punctur to grow a enough quantity of blood 5ml. Each blood samples was divid in two part. The chief part (about 0.5ml) was plac in a tub containing EDTA (22mg/ml) as an anticoagulants and mix thoroughly, then use for determination of hematologi analysis by an automatic analyzr. The remain blood was placed in a tube without anticoagulant and left for 30 minutes at room temperature and used to obtain serum via centrifugation at 6000 rpm for 5 minut. All samples were kept in a refrigerator at -20°C until the time of analysis (biochemical analysis) [9]

RESULTS

Effect of Atorvastatin and Ascorbic acid on liver and kidney weight

The results in Table (1) showed a significant increase ($p<0.05$) in liver weight level in the group treated with atorvastatin for 4 and 8 weeks in contrast with control group.

The group of male rats given atorvastatin with ascorbic acid also showed a significant increase ($p<0.05$) in liver weight level el for 4 and 8 weeks in contrast with control group.

Effect of vitamin c and atorvastatin on lipid profile (TG,TC, VLDL, LDL and HDL)

The results in Table (2) (3) showed a significant increase ($p<0.05$) in HDL level but decrease ($p<0.05$) in LDL, VLDL, Chlo. and TG levels in the group treated with atorvastatin for 4 and 8 weeks in contrast with control group.

The group of male rats given atorvastatin with ascorbic acid also

showed a significant increase (p<0.05) in HDL level but decrease (p<0.05) in LDL, VLDL, Chlo. and TG levels for 4 and 8 weeks in contrast with control group.

Effect of vitamin c and atorvastatin on levels of liver enzymes (ALT, AST and ALP)

The results in Table (4) showed a significant increase (p<0.05) in ALT, AST and ALP levels in the group treated with atorvastatin for 4 and 8 weeks in contrast with control group.

The group of male rats given atorvastatin with ascorbic acid also showed a significant increase (p<0.05) in ALT, AST and ALP levels for 4 and 8 weeks in contrast with control group (figures 1-3).

Table 1: Effect of atorvastatin and vitamin c on liver weight for 4weeks and 8 weeks.

Parameters Groups	Mean ±SD
	liver weight%
20 1Mon.	7.9±1.05
20 2Mon.	8.02±1.04
20+Vi 1Mon.	8.7±1.19
20+Vi 2Mon.	8.3±0.9
40 1Mon.	9.9±0.7
40 2Mon.	8.3±1.4
40+Vi 1Mon.	8.4±1.17
40+Vi 2Mon.	8.2±0.6
control	3.840±0.236
LSD	0.41

Value are mean ±SD. : *Significant differences (P<0.05);Number of rats=50

Table 2: effect of atorvastatin in concentration 20mg/kg with ascorbic acid on lipid profile in male rats treated for 4 and 8 weeks.

Paramete rs Groups	Mean ±SD				
	TG (mg/dl)	Chloe. (mg/dl)	VLDL (mg/dl)	LDL (mg/dl)	HDL (mg/dl)
20 1Mon.	57.49±3.20	76.4±4.39	11.59±0.80	9.02±4.18	55.39±3.41
20 2Mon.	36.74±2.20	63.4±3.51	7.58±0.60	4.65±2.29	51.17±5.25
20+Vi 1Mon.	50.37±3.86	69.2±1.92	11.18±0.80	6.56±1.82	51.46±3.38
20+Vi 2Mon.	53.32±2.63 ^a	62.2±6.34	7.18±0.29	3.09±0.79	51.93±5.84
control 1Mon.	68.80±1.64	89.0±1.00	12.51±0.56	39.40±0.55	38.8±0.84
control 2Mon.	71.40±1.52	91.2±0.84	13.92±0.48	41.60±2.19	41.2±1.10
LSD	3.047	4.05	1.08	2.706	4.411

Value are mean ±SD. *Significant differences (P<0.05)Number of rats=50

Table 3: Effect of atorvastatin in concentration 40mg/kg with ascorbic acid on lipid profile in male rats treated for 4 and 8 weeks.

Paramete rs Groups	Mean ±SD				
	TG (mg/dl)	Chloe. (mg/dl)	VLDL (mg/dl)	LDL (mg/dl)	HDL (mg/dl)
40 1Mon.	60.91±3.18	76.2±2.05	23.23±2.02	3.61±0.45	49.36±1.40
40 2Mon.	37.44±0.72	72.4±1.67	7.17±0.15	9.94±1.63	55.00±1.65
40+Vi 1Mon.	52.53±1.89	84.4±0.89	18.55±0.83	24.41±3.08	41.44±2.53
40+Vi 2Mon.	45.90±0.85	74.0±3.94	11.05±0.26	14.62±0.83	48.44±4.62
control 1Mon.	68.80±1.64	89.0±1.00	12.51±0.56	39.40±0.55	38.8±0.84
control 2Mon.	71.40±1.52	91.2±0.84	13.92±0.48	41.60±2.19	41.2±1.10
LSD	3.047	4.05	1.08	2.706	4.411

Value are mean ±SD. *Significant differences (P<0.05) Number of rats=50

Table 4: Effect of atorvastatin in concentration 20 mg/kg and 40mg/kg with ascorbic acid on level on level of liver enzymes (ALT,AST and ALP) in male rats treated for 4 weeks and 8 weeks

Parameters Groups	Mean ±SD		
	AST (U/L)	ALT (U/L)	ALP (U/L)
20 1Mon.	72±2.12	112.6±1.95	85.6±4.72
20 2Mon.	60.6±4.39	88.6±2.97	75.4±3.05
20+Vi 1Mon.	80.2±4.15	122.2±1.48	100±7.07
20+Vi 2Mon.	72±2.12	104.0±3.16	75.4±3.05
40 1Mon.	83.2±2.59	120.6±8.02	95.2±4.15
40 2Mon.	73.6±2.70	95.2±4.15	78.6±2.51
40+Vi 1Mon.	98±1.58	130±7.91	110±7.91
40+Vi 2Mon.	79.2±1.92	108.2±1.48	90±3.81
control 1Mon.	51.2±1.30	78.4±1.67	39.2±1.30
control 2Mon.	52.8±1.92	80.6±2.07	40.6±1.14
LSD	3.41	5.39	5.64

Value are mean ±SD. *Significant differences (P<0.05) Number of rats=50

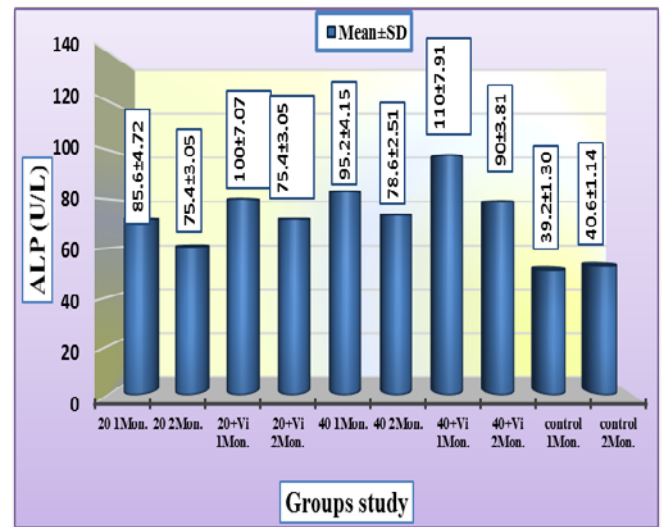


Figure 1: Effect of atorvastatin and ascorbic acid on the level ALP in the male rats for 4 and 8 weeks.

Value are mean ±SD. *Significant differences (P<0.05) Number of rats=50

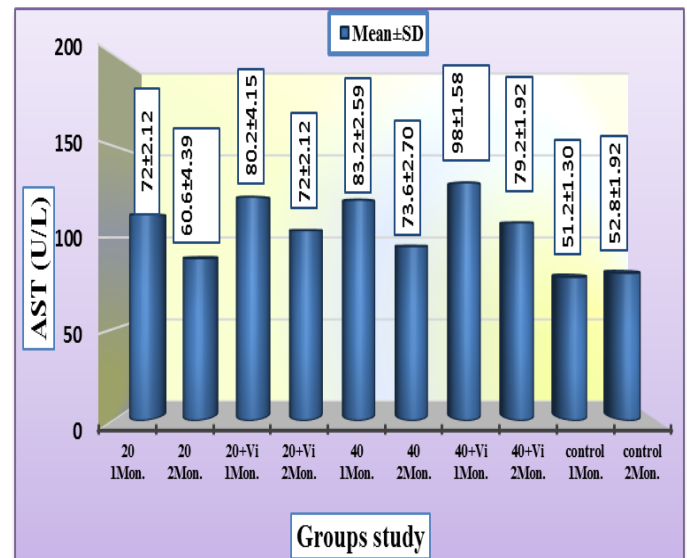


Figure 2: Effect of atorvastatin and ascorbic acid on the level AST in the male rats for 4 and 8 weeks.

Value are mean ±SD. *Significant differences (P<0.05) Number of rats=50

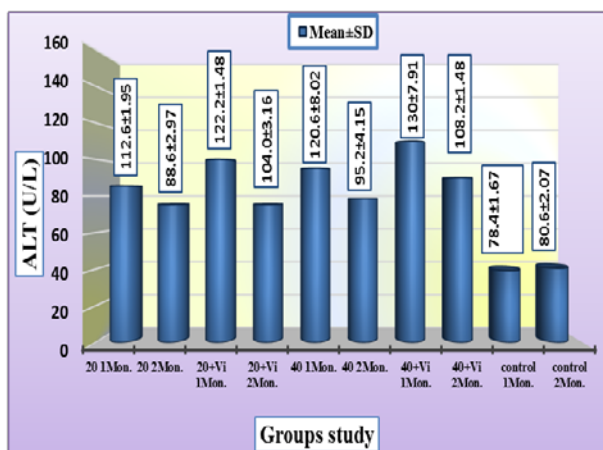


Figure 3: Effect of atorvastatin and ascorbic acid on the level ALT in the male rats for 4 and 8 weeks.
Value are mean ±SD. *Significant differences (P<0.05) Number of rats=50

Histological study of liver

The results in figure (4) showed histological changes, the liver sections of control showing ordinary normal central vein and hepatocytes.

In figure (5) (6) in periods (4weeks,8weeks), atorvastatin could induce histological changes, including bleeding, hepatocyte necrosis, hepatocyte degeneration, inflammatory cells infiltration in hepatic portal space and congestion of hepatic sinusoids.

In figure (7) : Group atorvastatin with vitamin c at concentration 20mg/Kg to showed infusion in some liver cells, inflammatory cells and the presence of normal hepatocyte cells showed, necrosis and bleeding. and In figure (8) : Group atorvastatin with vitamin c at concentration 40mg/Kg to showed infusion in some liver cells, inflammatory cells, Fibroblast Regeneration and the presence of normal hepatocyte cells.

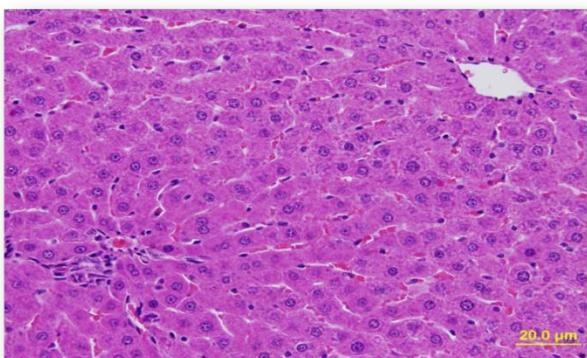


Figure 4: liver section of control showing normal hepatic section Architecture, N.C.V. =normal central vein and N.H. + Normal hepatocyte (H&E 400X).

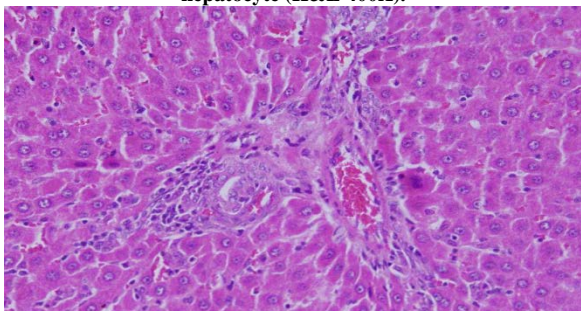


Figure 5: Liver section of male rats treated with atorvastatin for 4 weeks, showing inflammatory cells infiltration in the hepatic portal space, cytoplasmic vacuolization, HP=hepatocyte degeneration and B=bleeding (H&E 100X).

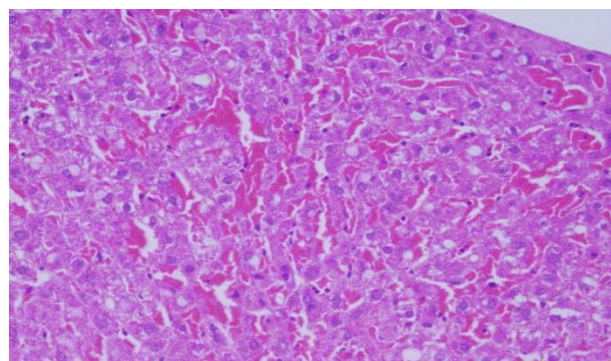


Figure 6: Liver section of animal rats treated with atorvastatin for 8 weeks showed, B=bleeding, dilation and congestion of hepatic sinusoids,C.V.= cytoplasmic vacuolization, HN= Hepatocyte necrosis, HP=hepatocyte degeneration.

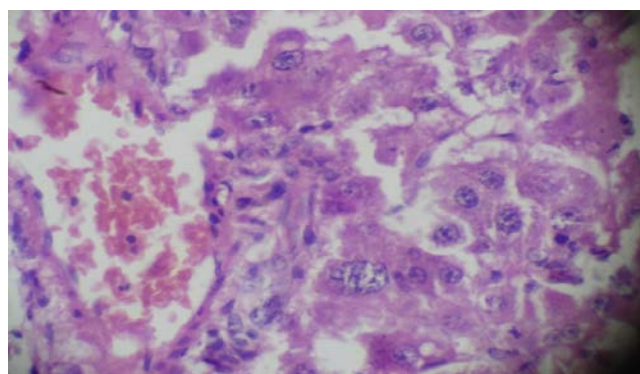


Figure 7: Liver section of male rate treated with Atorvastatin 20 mg/Kg +Vitamin C ,showed infusion in some liver cells, I.C. = inflammatory cells and the presence of N.H. = normal hepatocyte cells showed, N. =necrosis and B. = bleeding (H&E 400X) .

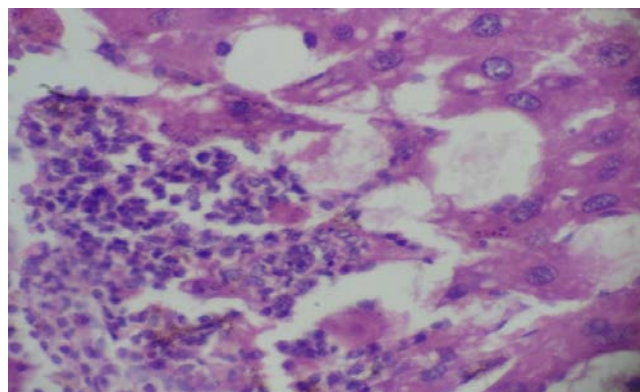


Figure 8: Liver section of treated rats by Atorvastatin 40 mg/Kg+ Vitamin C showed infusion in some liver cells, I.C. = inflammatory cells, F.R. =Fibroblast Regeneration and the presence of N.H. = normal hepatocyte (H&E 400X).

DISCUSSION

Effect of atorvastatin and Ascorbic acid on lipid profile

High level of blood cholesterol is a influential factor of atherosclerosis and many associated diseases like obesity, heart attacks and stroke and kidney failure [10] Studies have shown that atorvastatin reduces TC, TG, and LDL, while increasing levels of HDL [11,12]Our results were in accordance with these findings. It has been reported that high levels of fat increase fat-mediated oxidative stress and decrease antioxidative enzyme activity [13] In contrast, there are various reports indicating the beneficial effects of antioxidant supplementation in preventing dyslipidemia and cardiovascular disease [14,15]The study of [16]show that Atorvastatin treatment decreased serum level of TC,TG, LDL and

VLDL significantly while increased serum HDL significantly and this accordance with current study .The mechanism involved was largely attributed to the ability of atorvastatin to impair cholesterol synthesis via inhibiting the enzyme HMG-CoA reductase which is the rate limiting step in cholesterol biosynthesis. This both decreases circulating lipoproteins and increases their uptake by up regulating hepatic LDL receptors. Although statins share a common mechanism of action, there are differences in their relative efficacy for improving the lipid profile [17]. High doses of atorvastatin and rosuvastatin lowers LDL-C and non-HDL-C by 50 per cent or more [18]).

The primary main point of the study was to demonstrate the beneficial effect of administering atorvastatin with the two dosages of 40 mg/day and 20 mg/day for 2 month on different serum lipid profiles. Although it was previously believed that the most prominent effects attributable to statin therapy are its only potent LDL-C lowering properties, but, nowadays, it has been well established that statins, especially atorvastatin can significantly reduce non-HDL-C, and TG, but in some recent studies, show that atorvastatin could reduce TG levels in the range of 10-20% [19] Although these lipid-lowering effects have been shown following administration of different types of statins, but atorvastatin produces greater plasma LDL and TG reductions than other statins that may be due to its long-lasting action, presumably a reflection of longer residence time of atorvastatin and its active metabolites in the liver. The TG reduction with atorvastatin seems to stem from limiting very low-density lipoprotein (VLDL) secretion from the liver and increase in clearance of TG-rich lipoprotein via induced LDL receptors from plasma [20] In this particular study, the effects of atorvastatin on lipid profile was similar considering different dosages of the drug and thus administrated lower dose of the drug might be more preferable due to its probable side-effects, the use of atorvastatin with 20 mg/Kg is more emphasized to prevent adverse effects. Similar studies had revealed that the dosage range of atorvastatin is 10 to 80 mg once daily provides significant reductions from baseline in TG and LDL levels as well as an increase in HDL cholesterol levels with a well toleration 19, Even, it has been shown that high-dose atorvastatin therapy does not have a significant additional effect on the reduction of TG compared with a standard dose of 10 mg in both diabetics and non-diabetics patients [21,22]. In patients with hypertriglyceridemia, LDL-C reduction was substantial and dependent on the choice and dose of statin. TG reduction was numerically less than for LDL-C, and additional TG-lowering therapy may be considered to further reduce residual cardiovascular risk [23] In conclusion, antioxidant vitamins when given with Atorvastatin additionally improve lipid profile, inhibit lipid-peroxidation, and improve antioxidant status [24]

Among them, Ascorbic acid is a potent anti-oxidant that is known to prevent low-density lipoprotein(LDL) from oxidation [25], ascorbic acid, a water-soluble antioxidant, acts as an important factor in lipid regulation, increases HDL levels, and protects against LDL oxidation [26]Our findings showed a significant increase of HDL concentration, significant decrease in cholesterol, LDL, and triglyceride levels, and also reduction of LDL/HDL ratio with no significant changes in the control group after 12 weeks of supplementation with ascorbic acid The results of the present study were in accordance with and supported by earlier The results of the present study were in accordance with and supported by earlier studies conducted by Khajehdehi. The lipid peroxidation starts only after the depletion of natural antioxidants such as ascorbic acid and others in the body [27]This was supported by the fact that the low serum levels of antioxidant vitamins are associated with high risk of CAD [28]The combination of atorvastatin with ascorbic acid showed significant beneficial effects on serum lipid profile. Only this combination showed additional benefits as compared with statin alone.

Effect of atorvastatin and Ascorbic acid on liver function (AST,ALT,ALP)

AST and ALT were found in serum and various body tissues but are mostly associated with liver parenchymal cells. The elevated level of AST and ALT will be observed in acute liver damage condition. In addition, the level of ALT will rise with intrahepatic cholestasis and infiltrative disease of the liver [29]

Statins are metabolized mainly by the liver and increase aminotransferases levels with hepatic potential toxicity that might be attributed to alteration of the hepatocyte cellular membrane rather than direct liver injury [30,31]. The increased level of ALP, AST and ALT indicate these enzymes out from liver into stream of blood and indicate tissue harm, which is associated with liver necrosis [32,33]. AST is localized in the mitochondria, whereas ALT is distributed throughout the cytoplasm. In the case of hepatic stress, mitochondria damage with ROS accumulation tends to increase the level of AST rather than ALT [34]

Effect of atorvastatin and Ascorbic acid on Histological of Liver

Statins are powerful drugs very commonly used hypocholesterolaemia treatment. Several side effects, mainly related to hepatotoxicity [35]. The current recommendation that liver biochemistries be checked before and periodically after starting statin therapy is not evidence-based and is controversial. The presumed purpose of this recommendation is to identify patients with liver disease so that statins can be avoided in them, and to monitor for statin hepatotoxicity[36]Some reportes show that rosuvastatin, atorvastatin, fluvastatin and lovastatin administration induced an increase in adipose tissue size [37,38]. The incidence of statin-induced liver injury may increase because of the presence other risk factors which could increase patient liver-injury susceptibility. Three risk factors (obesity, dose, drug interaction) were studied.The available data indicate that statins are not frequently responsible for liver injury, but there are several issues related to their usage in humans that require further research, such as Drug-drug interactions also increase the hepatotoxicity of statins prolonged use of statins and long-term effects of statins on

Hepatic histology [39]. Asymptomatic hepatic enzyme elevations are the most common forms of hepatic side effects associated with atorvastatin [40]Bhardwaj *et al.* summarized several forms of side effects attributed to the use of atorvastatin, including hepatocellular injury, cholestatic injury, mixed pattern of atorvastatin-associated hepatocellular and cholestatic injury, autoimmune-type reaction and fulminant liver failure[41]Drug-drug interactions are one of the possible risk factors for statin-induced hepatitis ,Treatment by ascorbic acid with atorvastatin, show increase in apoptotic cells and ordinary histological due to antioxidant action of ascorbic acid that act as scavenger of free radicals. vitamin c enhance recovery from atorvastatin- induced liver damage in a manner partially depended on their antioxidant properties and bioavailability, necrosis induced by atorvastatin may be due to statin effect on permeability of hepatocytes membrane that lead to depletion of cholesterol [42].

REFERENCES

1. Wierzbicki, A. S. "Atorvastatin", *Exp. Opin on pharmacother*; 2001, 2: 819-830.
2. Stadman, E.R. Role of oxidant species in aging. *Curr. Med. Chem.*, 2004, 11: 1105-1112.
3. Valko, M.; Leibfritz, D.; Moncol, J.; Cronin, M. T. D.; Mazur, M.; Telsler, J. Free radicals and antioxidants in normal physiological functions and human disease. *Int. J. Biochem. Cell Biol.* 2007, 39, 44-84.
4. Willcox JK., Ash SL and Catignani GL. Antioxidants and prevention of chronic disease. 2004, 44(4):275-95.

5. Maiese, K., Morhan, S. and Chong, Z. Oxidative stress biology and cell injury during type 1 and type 2 diabetes mellitus. *Curr. Neurovasc. Res.*, 2007, 63-71.
6. Burt, A. D., and Day, C. P. Pathophysiology of the liver. In *Pathology of the Liver* (R. N. M. MacSween, A. D. Burt, B. C. Portmann, K. G. Ishak, P. J. Scheuer and P. P. Anthony, eds.), 2002, 67-105.
7. Kavakli, H.; Koca, C. and Alici, O. Antioxidant effects of curcumin in spinal cord injury in rats. *Turkish journal of trauma and emergency surgery*, 2011, 14-18.
8. Silici, S.; Ekmekcioglu, O.; Eraslan, G.; Demirtas, A. Antioxidative effect of royal jelly in cisplatin-induced testes damage. *Urology*, 2009, 74:545-51.
9. Sathivel, A., Raghavendran, H.R., Srinivasan, P., Devaki, T., Anti-oxidative and anti-hyperlipidemic nature of *Ulva lactuca* crude polysaccharide on D-galactosamine induced hepatitis in rats. *Food Chem. Toxicol.* 2008, 46 (10), 3262-3267.
10. McKenney, JM; Jones, PH.; Bays, HE. et al. Comparative effects on lipid levels of combination therapy with a statin and extended release. 2007.
11. Sathivel, A., Raghavendran, H.R., Srinivasan, P., Devaki, T., Anti-oxidative and anti-hyperlipidemic nature of *Ulva lactuca* crude polysaccharide on D-galactosamine induced hepatitis in rats. *Food Chem. Toxicol.* 2008, 46 (10), 3262-3267.
12. Slim, R.M., Toborek, M., Watkins, B.A., Boissonneault, G.A., Hennig, B., Susceptibility to hepatic oxidative stress in rabbits fed different animal and plant fats. *J. Am. Coll. Nutr.* 1996, 15 (3), 289-294.
13. Minhajuddin, M., Beg, Z.H., Iqbal, J. Hypolipidemic and antioxidant properties of tocotrienol rich fraction isolated from rice bran oil in experimentally induced hyperlipidemic rats. *Food Chem. Toxicol.* 2005, 43 (5), 747-753.
14. Gorinstein, S., Leontowicz, H., Leontowicz, M., Drzewiecki, J., Najman, K., Katrich, E., Raw and boiled garlic enhances plasma antioxidant activity and improves plasma lipid metabolism in cholesterol-fed rats. *Life Sci.* 2006, 78 (6), 655-663.
15. Save, V.; Patil, .; Moulik, N.; Rajadhyaksha, G. Effect of atorvastatin on type 2 diabetic dyslipidaemia. *J. Cardiovasc Pharmacol Ther* 2006, 11:262-70.
16. Schachter, M. Chemical, pharmacokinetic and pharmacodynamic properties of statins an update. *Fundam. Clin. Pharmacol.*; 2005, 19(1):117-25.
17. Nicholls, SJ.; Brandrup-Wognsen, G.; Palmer, M.; Barter, PJ. Meta-analysis of comparative efficacy of increasing dose of Atorvastatin versus Rosuvastatin versus Simvastatin on lowering levels of atherogenic lipids (from VOYAGER) *Am. J. Cardiol.*; 2010, 105:69-76.
18. Stein, E.A.; Lane, M.; Laskarzewski, P. Comparison of statins in hypertriglyceridemia. *Am. J. Cardiol.* 1998, 81(4A):66B-9B.
19. Funatsu, T.; Kakuta, H.; Tanaka, H.; Arai, Y.; Suzuki, K.; Miyata, K. Atorvastatin (Lipitor): a review of its pharmacological and clinical profile. *Nihon Yakurigaku Zasshi.* 2001, 117(1):65-76.
20. Stein, E.A.; Lane, M.; Laskarzewski, P. Comparison of statins in hypertriglyceridemia. *Am. J. Cardiol.* 1998, 81(4A):66B-9B.
21. Jones, P.; Kafonek, S.; Laurora, I.; Hunninghake, D. Comparative dose efficacy study of atorvastatin versus simvastatin, pravastatin, lovastatin, and fluvastatin in patients with hypercholesterolemia (the CURVES study). *Am. J. Cardiol.* 1998, 81(5):582-7
22. Karlson, BW1; Palmer MK.; Nicholls, SJ.; Lundman, P.; Barter PJ5 A VOYAGER Meta-Analysis of the Impact of Statin Therapy on Low-Density Lipoprotein Cholesterol and Triglyceride Levels in Patients With Hypertriglyceridemia. 2016, 117(9):1444-8.
23. Solanki, Y.B and Bhatt, R.V. Effects of antioxidant vitamins along with atorvastatin and atorvastatin-niacin combination on diet-induced hypercholesterolemia in rats. *Int J Physiol Pathophysiol Pharmacol.*; 2010, 2(1): 57-63.
24. Nakagawa, T.; Mazzalim, M.; Kang, D.H.; Sánchez-Lozada L.G.; Herrera-Acosta, J.; Johnson, R.J. Uric acid – A uremic toxin? *Blood Purif* 2006, 24:67-70.
25. Afkhami-Ardekani, M.; Shojaoddiny-Ardekani, A. Effect of Vitamin C on blood glucose, serum lipids & serum insulin in type 2 diabetes patients. *Indian J. Med. Res.*; 2007, 126:471-4
26. Esterbauer, H.; Jargons, G.; Quehenberger, O.; Koller, E. Auto-oxidation of human low-density lipoprotein: loss of polyunsaturated fatty acids and vitamin-E and generation of aldehydes. *J. Lip. Res.* 1987, 28:495-509.
27. Reimersma, R.A.; Wood, D.A.; Macintyre, C.C.H.; Elton, R.A.; Gey, K.F.; Oliver, M.F. Low plasma vitamin-E and C increased risk of angina in Scottish men. *Ann NY Acad Sci.* 1989, 570:291-295.
28. Gaze, D.D.C. The role of existing and novel cardiac biomarkers for cardiorotation. *Current opinion in investigational Drugs*, 2007, Vol.8, no.9, pp:771-717
29. VEILLARD, N.R. AND MACH, F., Statins: the new aspirin? *Cell Mol. Life Sci.*, 2002, 59: 1771-1786.
30. CLARKE, A.T. AND MILLS, P.R., Brief clinical observation: Rosuvastatin associated liver disease. *Dig. Liver Dis.*, 2006, 38: 772-777.
31. Zainab, S. Study of the Protective Effect of Ginger Extracts Against hepatic Induced by Carbon Tetrachloride in Rats. A thesis in physiology, Faculty of Science / University of Kufa, Iraq. 2013.
32. Esraa, M. Antihyperlipidemic and Hepatoprotective Effect of Cinnamon (*Cinnamomum zeylanicum*) Extract in Carbon Tetrachloride Induced Hepatotoxic and Hyperlipidemic in Male Rats. A thesis in physiology, Faculty of Science / University of Kufa, Iraq. 2015.
33. Hu, Z.; Lausted, C.; Yoo, H.; Yan, X.; Brightman, A.; Chen, J.; Wang, W.; Bu, X.; Hood, L. Quantitative liver-specific protein fingerprint in blood: a signature for hepatotoxicity. *Theranostics.*, 2014, 4: 215-228.
34. Sampson, UK.; Linton, MF.; Fazio, S. Are statins diabetogenic? *Curr Opin Cardiol*; 2011, 26: 342-347.
35. Browning, JD.; Szczepaniak, L.S.; Dobbins, R.; Nuremberg, P.; Horton, JD.; Cohen, JC et al. Prevalence of hepatic steatosis in an urban population in the United States: impact of ethnicity. *HEPATOLOGY*; 2004, 40: 1387-1395.
36. Parikh, NI.; Keyes, MJ.; Larson, MG.; Pou KM. Visceral and subcutaneous adiposity and brachial artery vasodilator function. *Obesity*, 2009, 17: 2054-2059.
37. Fierbinteanu-Braticevici, C.; Negreanu, L.; Tarantino, G. Is fatty liver always benign and should not consequently be treated? *J. Physiol. Pharmacol* 2013, 64: 3-9.
38. Karahalil, B.; Hare, E.; Göksel Koç, İrem Uslu, Kerem Şentürk, and Yağmur Özkan. Hepatotoxicity associated with statins, *Arh. Hig. Rada Toksikol*; 2017, 68:254-260.
39. Newman, CB.; Palmer, G.; Silbershatz, H, et al. Safety of atorvastatin derived from analysis of 44 completed trials in 9,416 patients. *Am. J. Cardiol.*; 2003, 92:670-676.
40. Bhardwaj, S.S.; Chalasani, N. Lipid lowering agents that cause drug-induced hepatotoxicity. *Clin. Liver Dis.* 2007, 11:597-613.
41. POLLACK, M. AND LEEUWENBURGH, C. Apoptosis and aging: role of the mitochondria. *J. Gerontol. Biol. Sci. Med. Sci.*, 2001, 56A: B475-482.