



Radiological Evaluation of the Effect of chia seeds oil on skin wound healing, Histological examination on male rats

Rana Fawzi Salih*, Enas fadhil

College of Dentistry, University of Baghdad, Baghdad

Abstract

Background: Wounds are any disruption to the normal anatomic structure of tissue which leads to the loss of epithelial continuity with or without a loss of underlying connective tissue, as well as the anatomic and functional integrity of the living tissue. Wound healing is a complex process with overlapping phases haemostasis, inflammation, proliferation and maturation/matrix Remodeling. Each phase of wound healing requires different management strategies, and inappropriate treatment can delay wound healing. The aim of wound treatment is a rapid wound closure and re-establish tissue function, chia seeds oil are widely used herbal medicines because of their anti-inflammatory and antioxidant capacity as they considered a good source of polyunsaturated fatty acids. Wound healing process can be assessed by histological examination of wound area besides the using of advanced color doppler ultrasound, the noninvasive testing of wound healing phases by providing considerable insights into an early angiogenesis and constitutes a helpful test in the detection of neovascularization by means of color Doppler vascularit index CDVI.

Aim of the study: The present study aimed to highlight the healing efficiency of chia seeds oil by color Doppler vascularity index

Materials and methods: A thirty male rats used in this study were divided into two groups for three healing intervals the experimental groups were: 1-15 rat were topically treated with chia seeds oil 2- the control

All animals subjected to surgical operation in the dorsum of the rat, creating a horizontal wound with full skin thickness depth and 2 cm length treated with tested oils (chia seeds oil)

Animals' scarifications were done in (3,7 and 10 days) durations.

Routine processing and sectioning technique was performed for histological evaluation.

Results: radiological and histological findings of this study showed that re-epithelialization, and remodeling of dermal fibrous connective tissue were accelerated after topical application of chia seed oil at wound site.

Conclusion: The study revealed that application of chia seeds oil was more effective in enhancement of wound healing as compared to the controlled one and the colored Doppler vascularity index was a useful diagnostic test of angiogenesis in wound healing.

Keywords: chia seeds oil, colored Doppler vascularity index, wound healing.

INTRODUCTION

Skin wound healing is a complex process involving a series of overlapping phases, including inflammation, proliferation, and remodeling. This process requires interactions between a variety of cell types, cytokines, growth factors, and extracellular matrix (ECM) molecules most wounds especially open wounds are often associated with wide ranging bacterial, fungal and viral floras. Although most of the bacterial infections can be managed using conventional antibiotics, there are several reports of multi-drug resistant bacteria and delay of wound healing by traditional drug treatments (1). Therefore, there is need for alternative therapies in wound management. Based on traditional medicine, studies showed improvement in the healing process with the use of natural products. Fatty acids (FAs) from these oils can modulate events such as cell migration and proliferation, phagocytic capacity, angiogenesis and production of inflammatory mediators leading to enhance wound healing (2) and they can also act as chemotactic agents for leukocytes and promote cell proliferation (3).

Among the fatty acids, much attention has been given to omega-6 and omega-3 fatty acids, chia seeds oil is a good source of these polyunsaturated fatty acids (4)

Aim of the Study: Study the effect of topical application of chia seed oil by means of radiological examination with colored Doppler and histological examination with H&E, on wound healing of rats.

MATERIALS AND METHODS

The materials used in the present study were chia seed oil, Anesthetic solution (ketamine + xylazine/ kg B.W.), 10% ethanol alcohol 96%, xylol, paraffin wax, and Hematoxylin and Eosin (H&E) stain.

thirty male rats with body weight (250-300) gram, aged (2-5) months were used in this study, A surgical horizontal wound with full skin thickness depth and 2 cm length was done in the skin of the back of the rat then the animals will be randomly divided into:

A-Control group treated with distilled water daily. was irrigated with distilled water.

B-Experimental group includes chia group was treated with one drop of chia seeds oil daily Every single group composed of 15 rats that will be studied histologically (H&E stain) and radiologically with colored Doppler ultrasound according to healing periods (3,7,10) days in three periods 3,7,10 days (5 rats for each period) Surgical technique

The surgery was performed under a well sterilized condition and gentle technique. Every animal was weighted to calculate the dose of general anesthesia that was given to it. The general anesthesia was induced by Intra-peritoneum with anesthesia (injection of xylazine 2% plus ketamine HCL 50mg), Then the animal was placed on the surgical table and the surgical towel was placed under the site of the operation. skin of the dorsum of each rat was shaved using cream and the skin was cleaned with a mixture of ethanol and iodine then a piece of cotton damped with alcohol and left covering the shaved skin for one minute. Using skin pen, marking on the skin of the dorsum was done by Verneer for incision (2 cm). A full thickness of skin by using blade no 24 Undermining of the incision by surgical scissor was done After that each incision in three experimental groups were treated with One drop of chia seeds oil daily.

The animal scarified were done in 3,7 and 10 days healing periods. (15 rats for each). Then skin incision was dissected and fixed in 10% buffered formalin.

Histological evaluation was performed using light microscope to measure the (number of inflammatory cells, epidermal thickness) The CDVI was defined as the ratio of the number of the colored pixels within a specified section to the number of total pixels in that specific section, and was calculated by using Encomate software (Electronic Business Machine Co. Ltd., Taipei, Taiwan)

Doppler ultrasound was performed before surgical operation to evaluate angiogenesis in wound area at all healing periods (3,7,10) days.

The color window was set to cover the whole wound incision on the screen.

The wound area was then scanned carefully in all directions, and the wound section with subjectively maximal color signals was captured and stored for later analysis. Each wound was scanned three times; thus, three wound sections with maximal color signals were available for quantitative analysis. After the examination, the previously stored images were retrieved and displayed on the monitor. Quantification of the vascular color signals within the demarcated wound area was then automatically performed using the special software (Encomate, Electronic Business Machine Co., Ltd., Taiwan). The results were expressed as the “color Doppler vascularity index (CDVI)” (the number of colored pixels within the specific section /the number of total pixels in that particular section). For each wound, the mean of the CDVI of three representative wound sections was used for statistical analysis (5,6).

RESULTS

Colour Doppler vascularity index findings CDVI CONTROL

At 3 day duration:

In this group colour Doppler imaging show low vascularity was detected at cubcutaneous tissue,with hypochoic fluid around the injured tissue.

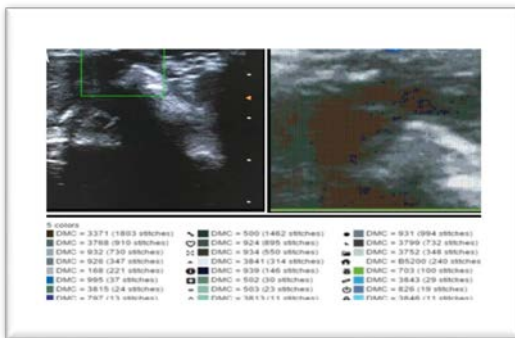


Figure 1: Low vascularity was detected at 3ed day of control group




Figure 2: Colour Doppler imaging show mild increase in vascularity at 7 day of healing period of control group

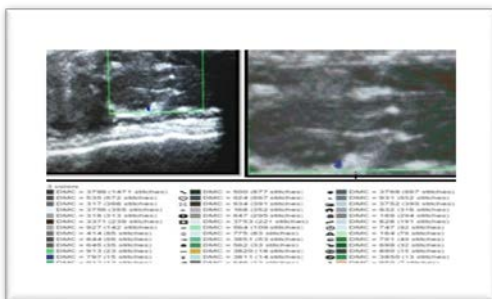


Figure 3: Diminished vascularity was seen in 10 day period of control group

EXPERIMENTAL GROUP

Skin incision treated with chia seeds oil

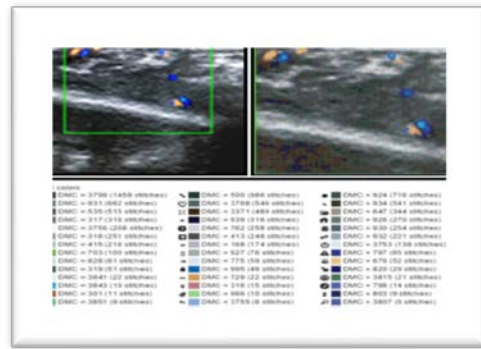


Figure 4: Increased vascularity was noted in 3ed day of healing period in chia seeds oil treated group

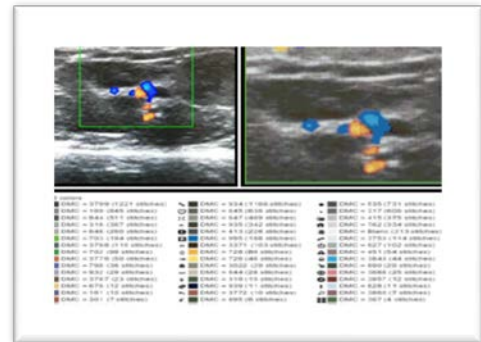


Figure 5: Colour Doppler imaging show increased vascularity at 7 day duration in chia seeds oil treated group.

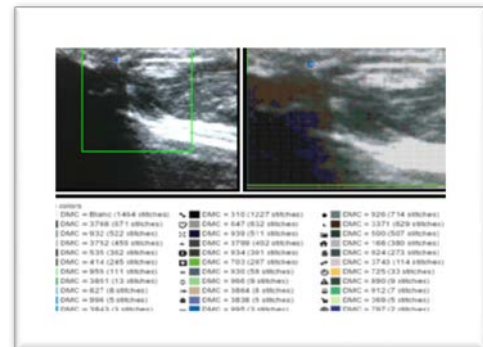


Figure 6: Decreased vascularity was detected in colour Doppler imaging compared to 7 day duration

Histological findings (Hematoxylin and eosin stain)

1 CONTROL

At 3 Day duration

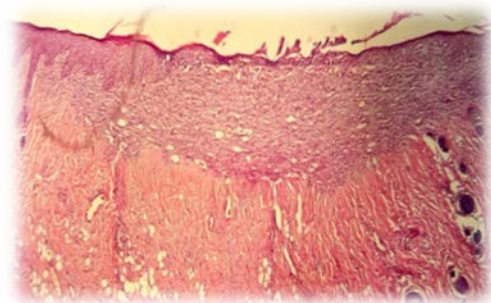


Figure -7-View of control group at wounded area after 3day shows granulation tissue and repithelization, new blood vessels, collagen fibers ,fibroblast, fat ells. H&EX10

At 7 Days duration

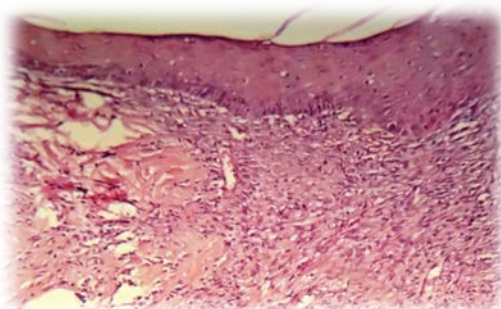


Figure 8: Microphotograph of wound site of 7 day duration in control group shows. Complete epithelization at wound area, Collagen fiber, new blood vessel and fat cells. H&EX20

At 10 Days duration

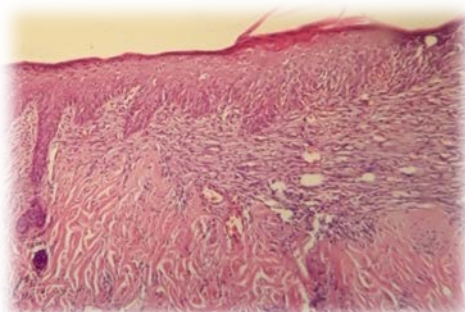


Figure 9: Microphotograph of wound site of Control group 10 day duration shows. Complete epithelization at wound area Collagen fiber, fibroblast, fat cells and newly blood vessels H&EX10.

2-EXPERIMENTAL GROUP

At 3 Days duration

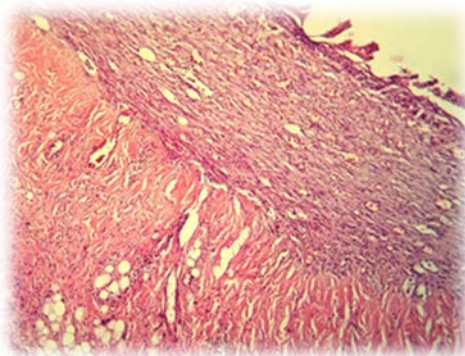


Figure 10: Microphotograph of wound site of 3 day chia seeds oil duration shows. Complete epithelization at wound area, fibroblast cells, collagen fiber, blood vessels and H&EX20.

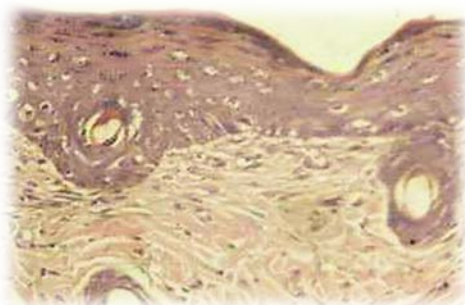


Figure -11- Microphotograph of wound site of chia seeds oil group 7 day duration shows complete epithelization well defined newly blood vessels collagen fiber and active fibroblast. H&EX20.

At 7 Days duration

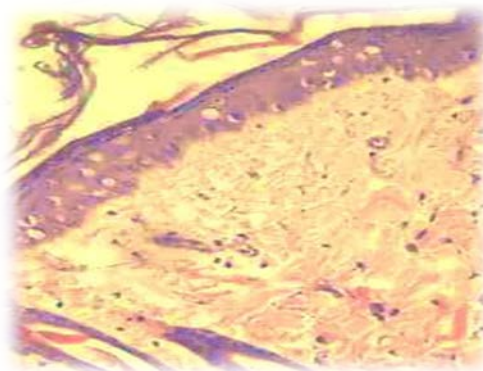


Figure 12: Microphotograph of wound site of chia seeds oil group 10 day duration shows complete epithelization well defined newly blood vessels collagen fiber and fibroblast. H&EX20.

Color Doppler vascularity index

Table 1 showed the descriptive statistic for the number, mean, standard deviation, minimum and maximum values of data measured at different healing periods for all groups for CDVI. The highest mean value of the index was seen in chia oil group at day (7) and the least mean value was seen in control group at day (3)

Table 1: Descriptive statistics of CDVI in each duration of wound healing

Period	Groups	N	Mean	SD	SE	Min	Max
3ed day	Control	5	0.0108	0.0008	0.0004	0.01	0.012
	chia oil	5	0.0158	0.0016	0.0007	0.014	0.018
	Total	10					
7 th day	Control	5	0.0308	0.0042	0.002	0.028	0.038
	chia oil	5	0.0416	0.0023	0.001	0.039	0.044
	Total	10					
10 th day	Control	5	0.0202	0.0027	0.001	0.018	0.024
	chia oil	5	0.0258	0.0015	0.0007	0.024	0.028
	Total	10					

Inflammatory cells count

Table -2 - showed the descriptive statistic for the number, mean, standard deviation, , minimum and maximum values of data measured at different healing periods for inflammatory cells count . The highest mean value of the inflammatory cells count were seen in 3 day in control group and the least mean value were seen in 10 days in chia oil group

Wound contraction Table -3- showed the descriptive statistic for the number, mean, standard deviation, minimum and maximum values of data measured at different healing periods for all groups for contraction of wound. The lowest mean value for contraction of wound were seen in chia seeds oil group at 10 days interval

Table 2: Descriptive statistics of inflammatory cell count in each duration of wound healing for all groups

Period	Groups	N	Mean	SD	SE	Min	Max
3ed day	Control	5	73.2	6.0	2.7	65	80
	Chia oil	5	57.2	4.9	2.2	50	62
	Total	10					
7 th day	Control	5	53.4	3.0	1.3	50	54
	Chia oil	5	44.4	3.5	1.6	40	45
	Total	10					
10 th day	Control	5	45.8	3.1	1.4	42	49
	Chia oil	5	34.4	2.7	1.2	31	37
	Total	10					

Table 3: Descriptive statistics of contraction of wound with time of healing for all groups.

Period	Groups	N	Mean	SD	SE	Min	Max
3 rd day	Control	5	1.92	0.08	0.03	1.8	2
	Chia oil	5	1.85	0.10	0.04	1.7	1.95
	Total	10					
7 th day	Control	5	1.76	0.05	0.02	1.7	1.8
	Chia oil	5	1.54	0.05	0.02	1.5	1.6
	Total	10					
10 th day	Control	5	1.67	0.07	0.03	1.6	1.75
	Chia oil	5	1.26	0.04	0.02	1.2	1.3
	Total	10					

Epidermal thickness

Table -4- showed the descriptive statistic for the number, mean, standard deviation, minimum and maximum values of data measured at different healing periods for all groups for thickness of epidermis. The highest mean value of the epidermal thickness were seen in 10 days in chia oil group and the least mean value for epidermal thickness was seen in 3 day control group

Table 4: Descriptive statistics of Thickness of epidermis with time of healing for all groups.

Period	groups	N	Mean	SD	SE	Min	Max
3 rd day	control	5	487	24.4	10.9	450	515
	Chia oil	5	567.8	11.3	5.0	550	579
	Total	10					
7 th day	control	5	608.6	10.3	4.6	600	625
	Chia oil	5	624.2	11.6	5.2	611	640
	Total	10					
10 th day	control	5	635.6	10.6	4.7	625	651
	Chia oil	5	640	11.8	5.3	625	655
	Total	10					

DISCUSSION

Histological evaluation

According to the present findings: granulation tissue was monitored earlier in the treated wounds than in the control ones. This suggests that topical use of seed oil from chia seeds may enhance the healing process while promoting a fast formation of granulation tissue. The results of control group showed gradual increase in epithelialization. At day 3, the control group showed incomplete epithelial regeneration. However, chia seeds oil-treated group revealed a complete epithelial regeneration. While in control group at day 7 of incisional wound histological evaluation revealed complete epithelialization. (7) Who improved that new epithelium formation was complete at 7 days of incisional wound in control group at skin of mice.

Control group showed thin epithelium compared with oil treated group and revealed a full re-epithelialization. The control group showed a slower epithelialization than the groups treated with the tested oil (chia seeds oil), contraction is an essential part of the healing process (8). A contraction of wound is the phenomenon in which the size of wound is reduced by the inward movement of wound margins, wound contraction begins 4 to 5 days after initial injury and actively continues for approximately 2 weeks. Wound contraction is characterized by a predominance of myofibroblasts at the wound periphery. In this study wound contraction was accelerated in tested oil treated group in 7 and 10 duration as compared to the control group. At

day (7,10) wound treated with chia oil showed a higher relative collagen volume than wound from control group rats. This might suggest that chia oil stimulate the development of fibroblasts. Therefore, chia oil seem to stimulate the proliferation of fibroblasts and the synthesis of collagen fibers. Oils containing higher amounts of poly unsaturated fatty acids like chia seeds oils provided a better advancement in wound contraction effect compared with the control (9). The histological examination of experimental group at 7 days of incisional wound, the histological results showed reduction in inflammatory cell count and replacement of granulation tissue by fibrous connective tissue and this agree with (7). who found that reduction of inflammatory cells and replacement of granulation tissue by fibrous connective tissue in skin wound of experimental mice group at 7 days.

A decrease in number of inflammatory cells in the oil treated group with chia seed oil during period of 3 and 7 and 10 days as a compare with control group suggest an anti-inflammatory effect of oils containing a high amount of polyunsaturated fatty acids such as linoleic and linolenic acid which are important in the inflammatory cascade (prostaglandins, thromboxanes, and leukotrienes) as reported by Wendt (10). Antioxidant content of chia oil is more than that of chia seeds. Antioxidant activity is expressed by different enzymes for example superoxide dismutase and glutathione peroxidase. Chia oil is very useful to induce the expression of these enzymes. Thus it promotes the antioxidant activity. Chia seeds act by the presence of fatty acids and antioxidants that promote a reduction in the inflammatory response (11).

Results from rats treated with chia oil showed a thick and well-structured epidermis covering the wound. The epidermis of control group gives a normal appearance, similar to adjacent normal skin but a considerably thin and poorly organized epidermal layer. Results of the CDVI show increase neovascularization in chia oil group in comparison with control group wound. colour doppler from rats treated with chia seeds oil showed higher blood vessel volume than the control group. Moreover, previous studies suggest that the antioxidant effect of any drug prevents cell damage, increases vascularity, enhance local neovascularization and increases the strength of collagen fibers (12). Results of CDVI revealed that chia seeds oil could significantly stimulate angiogenesis, during the proliferative phase (7 days), the increased number of vessels in the wound tissue might be suggested due to the effect of fatty acids (oleic and linolenic acids) included in chia seeds oil that can stimulate neovascularization as reported by (13).

CONCLUSION

The study revealed that application of chia seed oil was more effective in enhancement and in acceleration of healing process of wound in animals as compared to the controlled one and the colored Doppler is a useful diagnostic test in evaluation of angiogenesis of wound healing.

REFERENCE

- Nolff M. C., Reese S., Fehr M., Denning R., Meyer-Lindenberg A. Assessment of wound bio-burden and prevalence of multi-drug resistant bacteria during open wound management. *J. Small Anim. Pract.* 2016, 57, 255–
- Fruhwith GO, Hermetter A. Seeds and oil of the styrian oil pumpkin: Components and biological activities. *J Eur Lipid Sci Tech* 2007, 109:1128–40
- L. M. Pereira, E. Hatanaka, E. F. Martins et al., "Effect of oleic and linoleic acids on the inflammatory phase of wound healing in rats," *Cell Biochemistry and Function*, vol. 26, no. 2, pp. 197–204, 2008.
- Cheryl Kaiser, Matt Ernst. "Chia" (PDF). University of Kentucky, College of Agriculture, Food and Environment, Center for Crop Diversification Crop Profile. Retrieved 13 February 2016, 34:44-10

5. Cheng WF, Lee CN, Chu JS, et al. Vascularity index as a novel parameter for the in vivo assessment of angiogenesis in patients with cervical carcinoma. *Cancer*; 1991, 85: 651–657
6. Chen CN, Cheng YM, Liang JT, et al. Color Doppler vascularity index can predict distant metastasis and survival in colon cancer patients. *Cancer Res*; 2000, 60: 2892–2897
7. AlWattarWM. Immunohistochemical Evaluation of The Effect of 790-805nm Diode Laser on Interlukin-1 β , Epidermal, Fibroblast, Vascular Endothelial and Platelet Derived Growth Factors In Wound Healing. Phd thesis, Baghdad university, 2013, ch4,p:128,ch3,P:88.
8. Liu M, Dai Y, Li Y, et al. Madecassoside isolated from *Centellaasiatica* herbs facilitates burn wound healing in mice. *J Planta Med* 2008, 74:809–15
9. Cardoso CRB, Souza MA, Ferro EAV, Favoreto S, Jr, and Pena JDO. Influence of topical administration of n-3 and n-6 essential and n-9 nonessential fatty acids on the healing of cutaneous wounds. *Wound Repair Regen* ; 2004, 12:235
10. Wendt SB. Comparação da eficácia da calêndula e do óleo de girassol na cicatrização por segunda intenção de feridas em pequenos animais Master's Degree Programm (Ciências Veterinárias), Universidade Federal do Paraná, Curitiba, Brazil 2005.
11. - Guevara-Cruz M, Tovar A, Aguilar-Salinas C, Medina-Vera I, Gil-Zenteno L, Hernandez-Viveros I, Lopez-Romero P, Ordaz-Nava G, Canizales-Quinteros S, Guillen Pineda L, Torres N. A Dietary Pattern Including Nopal, Chia Seed, Soy Protein, and Oat Reduces Serum Triglycerides and Glucose Intolerance in Patients with Metabolic Syndrome. *J. Nutr.*; 2012, 142:64-69.
12. Rojo L. E , Villano C. M., Joseph G. et al., "Wound-healing properties of nut oil from *Pouterialucuma*," *Journal of Cosmetic Dermatology*, 2010, vol. 9, no. 3, pp. 185–195,
13. Ekci B, Karabicak I, Atukeren P, Altinli E, Tomaoglu K, and Tasci I. The effect of omega-3 fatty acid and ascorbic acid on healing of ischemic colon anastomoses. *Ann Ital Chir*, 2011, 82:475.