

Experimental Model of Toxic Hepatitis on Rabbits

O.A. Gracheva, A.E. Pugatina, M.G. Zukhrabov, D.R. Amirov, B.F. Tamimdarov, D.M. Mukhutdinova, Z.M. Zukhrabova

Faculty of veterinary medicine, Kazan State Academy of Veterinary Medicine by N.E. Bauman, Sibirsky tract 35, Kazan city, 420029, Russia

Abstract.

One of the methods for investigating complex mechanisms of pathological process development in the body is biological modeling. Absence of standardized reproducible experimental models makes comparative assessment of multiple drug efficacy studies including in case of liver diseases much more difficult. Among experimental toxic lesions of the liver, the model of liver lesion induced by tetrachloromethane in mice is widely spread, which has considerable drawbacks. So, for certain tasks it becomes necessary to work with other animal species, in particular, with rabbits. Modeling of acute and chronic lesion of liver was done by intraperitoneal administration of 50 % carbon tetrachloride olive oil solution based on 1 ml per kg of body mass twice a week. In the course of experiment, on day 5 rabbits develop toxic lesion of liver supported by hematology examination. Hepatic functional insufficiency was characterized by hypoproteinemia, dislipidemia, statistically significant increase of serum transaminase activity, total bilirubin. Ultrasound, x-ray, morphological analysis of liver tissues in experimental rabbits showed changes consistent with hepatitis signs. Thus, this investigation has demonstrated that use of rabbits as a model gives a number of advantages: the possibility of studying biochemical markers in dynamics, ultrasound and x-ray monitoring of lesion.

Key words: liver, rabbit, toxicity, blood, analysis, preparations

INTRODUCTION.

As the production pharmaceutical market is establishing, interest to drug development and testing grows. In this connection, the investigations aimed at creating experimental models of pathological processes, which, by their manifestation, cell population response and biochemical status, would be largely consistent with the course of diseases in animals, become particularly relevant [1].

At present, the number of experimental models of liver lesion is rather great [2, 3, 4]. However, absence of standardized reproducible experimental models makes comparative assessment of multiple studies of drug efficacy much more difficult and in a number of cases puts forecasting achievement of an effect in doubt [5]. In laboratory animals, acute and chronic lesion of liver can be induced by different methods: surgical — by liver resection; chemical — administration of toxic agents (tetrachloromethane, paracetamol etc.); special diets (choline-deficit etc.); by combining hepatic toxins with hepatic carcinogens suppressing proliferation of hepatocytes; genetic models [6,7].

Among toxic models, the model of liver lesion induced by tetrachloromethane (CCl₄ - carbon tetrachloride) is widely used. Literature contains contradictory data concerning preference of this model of toxic lesion of liver or other. Drawbacks and advantages of various models are mentioned [8]. Rats are used most frequently as an object of modeling. Essentially, the model consists in intraperitoneal administration of 50 % *раствора* CCl₄ olive oil solution to rats based on 1 ml per kg of body mass twice a week. In case of this method, acute toxic hepatitis develops 2 days after experiment onset and liver cirrhosis - 2 months later. However, this model has a number of drawbacks. Under similar experimental conditions, different rats developed different morphological changes in liver by day 60, which evidences their different sensitivity to tetrachloromethane, it is impossible to trace biochemical status changes in dynamics. Hence, for certain tasks, it becomes necessary to work with larger animals, specifically, rabbits. Modeling toxic lesion of liver in rabbits gives several advantages. Firstly, the regeneration capability of rabbit liver is lower than that of rats, which makes this model more adequate. Secondly, it becomes possible to carry out not only postmortem morphology analysis of organs, but in-life morphofunctional investigation of pathological changes in target organs with less consequences for the animal. Laboratory diagnostics of clinical and chemical blood indices in dynamics allows assessing functional changes in affected organs during an experiment and the result of subsequent correction of induced disorders. Use of a larger animal will also allow performing in-life instrument-assisted diagnostics of liver lesions (ultrasound and x-ray examination) [9].

The purpose of this study was to evaluate the possibility of using rabbits as an experimental model of toxic lesion of liver for subsequent evaluation of the hepatoprotective effect of new veterinary drugs.

MATERIALS AND METHODS.

As the object for modeling toxic lesion liver, rabbits of Bely Velikan breed weighting 2.3-2.5kg and aged 3 months were used. The animals were kept in the vivarium environment with natural light conditions on standard diet [10] in compliance with the European Convention for Protection of Vertebrate Animals Used for Experiments or Other Scientific Purposes and code of laboratory practice during pre-clinical trials in RF.

Modeling of acute liver lesion was carried out by intraperitoneal administration of 50 % CCl₄ (tetrachloromethane) olive oil solution based on 1 ml per kg of body mass twice a week.

Special attention was paid to indices characterizing the course of pathological processes and possibility of applying the elaborated model for drug efficacy evaluation. To this end, regular observations of animals were performed with feed and water consumption, changes in appearance (hair, visible mucous tissues), peculiarities of behavior being noted, and weighting was also done every week.

Prior to experiment onset and on day 5, 15, and 30, hematological analysis was performed in rats. Morphological examination included determination of hemoglobin, count of erythrocytes and leukocytes, leukogram computation using automatic hematological analyzer ARD-22 (Russia). Biochemical examinations included assessment of metabolic effects of the hepatic toxic agent under study on protein (total protein, albumin and globulin content), carbohydrate (glucose level), and lipid (triglycerides and cholesterol) metabolisms, markets of the functional condition of liver (activity of aspartate transaminase (AST), alanine aminotransferase (ALT), alkaline phosphatase (AP), glutamyl transpeptidase (GTP), total bilirubin) using chemical analyzer «Biochem SA» at the premises of the Veterinary Clinical & Diagnostic Center Laboratory.

Ultrasound examination of rabbit liver before and during the experiment was performed using Mindray DC-7 apparatus with a linear sensor; x-ray examination – portable x-ray apparatus Dongmun DIG-360.

At the end of experiments, animals were subjected to euthanasia in a CO₂ chamber. Pthomorphology included necropsy, macroscopic examination. For histology, liver pieces were sampled from killed animals. To prepare histological specimens, the material was fixated in 9:1 alcohol-formalin, consolidation was done by paraffin embedding. 5-7 μm-thick sections were stained with hematoxylin and eosin.

Table 1 - Dynamics of Blood Serum Chemistry in Experimental Rabbits

Indices	Groups	Experiment Period, days			
		Background	5	15	30
Total Protein, g/l	experimental	67.60±0.91	51.60±1.82*	48.00±1.90*	49.40±1.04*
	control	68.00 ±1.27	65.00 ±1.84	65.40 ±1.79	66.00 ±1.90
Albumin, g/l	experimental	32.78 ±0.90	22.24 ±0.81*	23.28 ±0.38*	22.78 ±0.71*
	control	33.54 ±0.85	34.62 ±1.50	35.96 ±1.03	35.80 ±1.36
Globulins, g/l	experimental	34.82 ±1.36	29.36 ±0.49*	24.72 ±1.04*	26.62 ±0.71*
	control	34.46 ±2.0	30.38 ±0.43	29.44 ±1.07	30.20 ±1.19
Glucose, mmol/l	experimental	7.68 ±0.12	10.72 ±0.36*	7.84 ±0.33	5.20 ±0.54*
	control	7.52 ±0.13	7.54 ±0.10	7.44 ±0.17	7.48 ±0.19
Cholesterol, mmol/l	experimental	1.05 ±0.11	5.96 ±0.08*	0.88 ±0.02	0.92 ±0.03
	control	1.04 ±0.06	1.08 ±0.07	1.11 ±0.08	1.05 ±0.04
Triglycerides, mmol/l	experimental	1.26 ±0.03	4.87 ±0.09*	0.95 ±0.09	0.76 ±0.04
	control	1.36 ±0.04	1.37 ±0.02	1.39 ±0.02	1.23 ±0.07

Note: *- p≤0.01 relative to background.

The data obtained as a result of investigations were subjected to variation statistic processing with application of Student's reliability criterion on a PC using Microsoft Excel.

RESULTS AND DISCUSSION.

Experimental induced toxic hepatitis was supported by clinical and chemical examinations. Examinations established that on day 3 after toxic agent application the animals developed clinical symptoms of intoxication that manifested in hypodynamia and depression of animals. Hair was matt, ruffled; the animals tended to lie; mucous tissues and skin were pale and yellowish; appetite was decreased. Symptoms of prominent intoxication in that group of rabbits disappeared only on day 10-12 after onset of the experiment.

Hematology examinations found that administration of tetrachloromethane suppresses hematopoiesis, manifesting in drastic decrease of blood serum hemoglobin in experimental animals compared to background values and those of intact animals. For instance, on experimental day 5, hemoglobin decrease in animals with experimental hepatitis amounted to 43% and did not increase to the end of experiment. Similar dynamics was observed in erythrocyte count: on day 5 after toxic effect, blood erythrocytes decreased by 36.8% and at the end of experiment the count was 15% lower than that of intact animals. On the contrary, the count of leukocytes doubled in the experimental group and remained higher than physiological norm to the end of the follow-up period. Leukogram examination found that changes occur due to increase of percentage ratio of segmented neutrophils and monocytes. The first examination established that the count of segment leukocytes upon occurrence of intoxication increased in experimental animals by 14 %; that of monocytes increased 2-fold; correspondingly, the count of lymphocytes decreased; percentage relations of other types of leukocytes did not change; this pattern is typical for intoxication and beginning of an inflammatory process.

Biochemical examinations in case of toxic hepatitis induced by carbon tetrachloride note functional insufficiency of liver and suppression of its functions. Biochemical analysis of the fifth day of experiment established a wide range of prominent pathobiochemical changes including development of hypoproteinemia (total protein concentration fell by 23.7%, that of albumins – by 32.2%), dislipidemia (3-4-fold increase of total cholesterol and triglycerides).

During development of acute toxic hepatitis, the content of total protein and albumin in blood serum of experimental rabbits decreases versus background and control values by 20-25% on average, which evidences disturbance of the protein synthesis function of liver. This tendency was persistent in rabbits to the

end of the term of experiment. On day 5 of the experiment, blood serum glucose reliably increases in rabbits, which is probably caused by impairment of liver capability to maintain carbohydrate balance of blood. However, already by the end of experiment, hypoglycemia is detected; at the end of experiment, glucose level is 30% lower than in healthy animals, which might be connected with disturbance of glycogenolysis and gluconeogenesis in the liver of experimental animals.

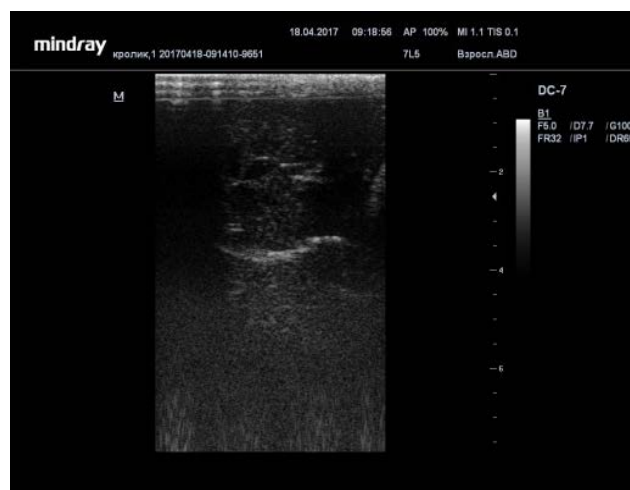


Fig.1. Ultrasound image of intact rabbit liver

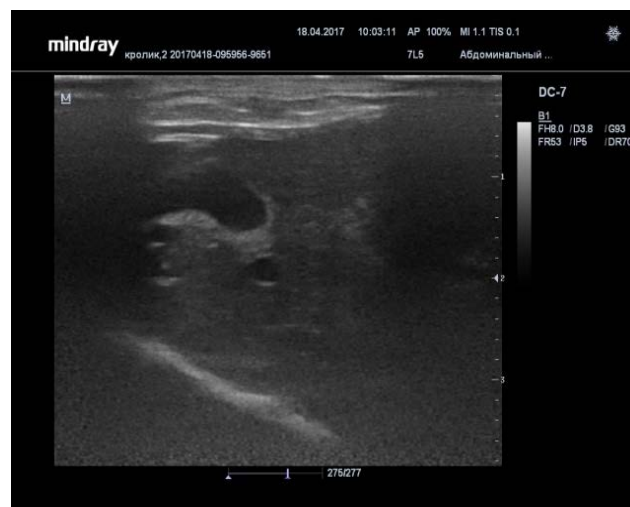

Fig.2. Ultrasound image of rabbit liver during hepatitis

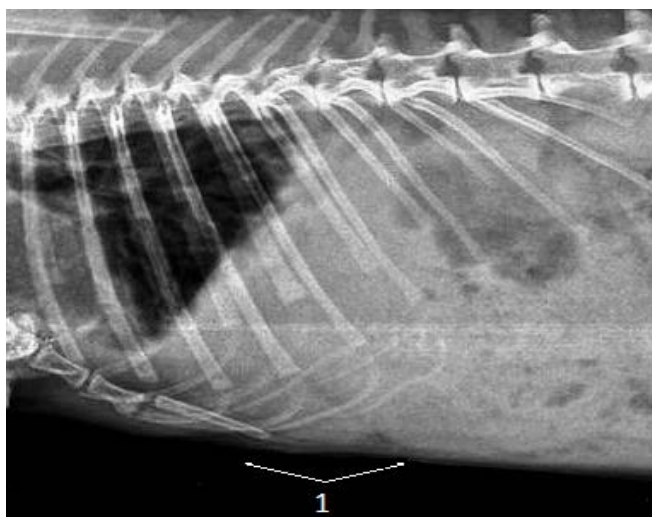


Fig.3. X-ray of chest and abdominal organs of rabbit (1- liver protruding outside the coatal margin)

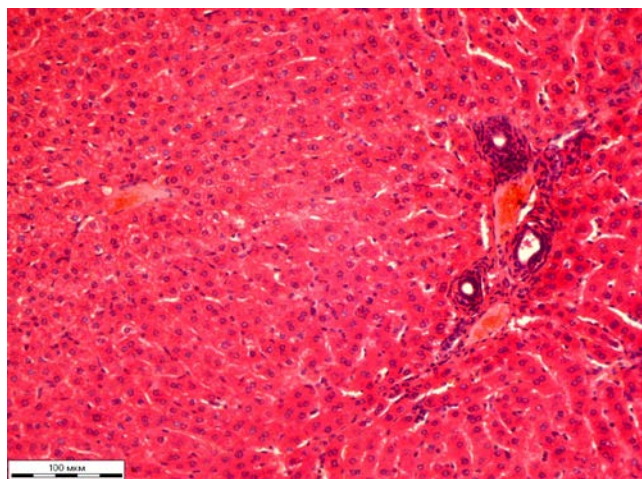


Fig.4. Rabbit of intact group, liver. Stained with Ehrlich's hematoxylin, water-based eosin, lens X20.

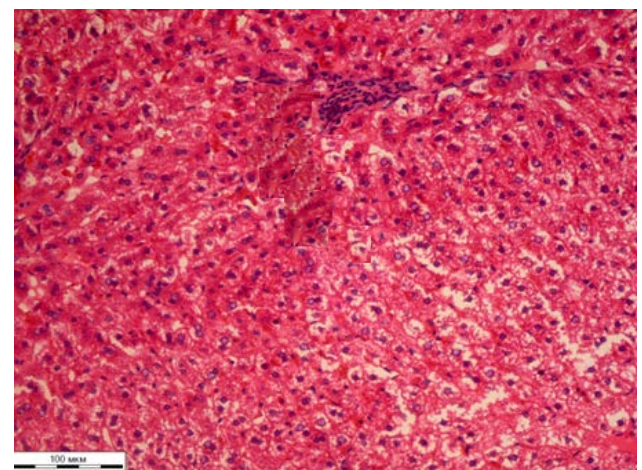


Fig.5. Rabbit of experimental group, liver. Stained with Ehrlich's hematoxylin, water-based eosin, lens X20.

Cholesterol content and concentration quite frequently changes due to functional condition of the liver. During most functionally compensated hepatic diseases before hepatic failure develops, increased cholesterol content is observed while in case of hepatic insufficiency its blood serum content falls down. In the acute toxic hepatitis conditions, most reliable changes in the blood of

experimental rabbits occur during the first week of the study when total cholesterol and triglycerides increase 3-4-fold versus baseline. This seems to be a consequence of increased secretion of liver lipoproteins into plasma and disturbance of cholesterol biosynthesis in liver from acetyl coenzyme A. But already at the end of experiment, the level of triglycerides in the blood serum of rabbits from the experimental group is 38.2% lower than background and norm, and that of cholesterol – by 12.4%, which evidences development of a chronic inflammatory processes and hepatic insufficiency.

During use of the model of toxic lesion of rabbit liver upon administration of carbon tetrachloride to animals, very prominent changes in the activity of enzymes that are markers of the functional condition of liver were recorded. Significant increase of AST and ALT activity already on experimental day 5 9-7-fold, correspondingly, versus control was observed. GTP activity in animals of the first group increased 8-fold compared to control animals and was equal to 54.54 ± 5.54 U/l. In the same experimental rabbits, blood serum lactic dehydrogenase activity changed much less with 1.5-fold increase versus the control group of animals; alkaline phosphatase activity increased 4.3-fold.

On experimental day 30, in animals of the experimental group, AST, ALT, GTP, LDH, and AP activity indices tended to decrease compared to the same indices on experimental day 5. However, that tendency was rather moderate and activity of all above-mentioned enzymes was reliably higher than that of the control group of rabbits.

The investigation of one of key indices of pigmental metabolism – blood bilirubin – allowed recording a reliable increase of its content in the blood of rabbits with experimental toxic lesion of liver induced by administration of tetrachloromethane. Total bilirubin concentration on experimental day 5 in blood serum of animals of the first group was equal to 15.16 ± 0.53 $\mu\text{mol/l}$, which is 3 times higher compared to control group animals. On experimental day 30, in the blood of experimental group rabbits, total bilirubin concentration decreased by 18.5% compared to day 5, but its content in experimental animals remained reliably higher than the same indices in intact rabbits. On experimental day 30, blood serum total bilirubin was 2.5-fold higher than control.

Summing up the results of investigation of biochemical indices of the liver functional condition in rabbits with experimental toxic lesion at different time points of observation, it can be asserted that the recorded increase of aminotransferase activity in the blood of experimental animals evidences damage of hepatocyte membranes and death of liver cells under the action of tetrachloromethane.

During ultrasound examination of rabbit liver, transabdominal visualization method was used. In intact rabbits (fig.1), liver did not protrude outside the coatal margin; an easily recognizable reference point in the abdominal cavity was the diaphragm as a hyperechogenic line closely adjacent to the liver. Hepatic parenchyma echogenicity was equal of spleen parenchyma echogenicity. Liver echostructure was homogenous, fine, of moderate echogenicity, with few echonegative and echopositive structures, feebly-marked network of intrahepatic vessels, bile ducts were almost non-visualized. Gall bladder was located in epigastric region as an elongated pear-shaped anechoic formation with very thin smooth walls, surrounded by hepatic parenchyma.

In experimental rabbits (fig.2), during ultrasound examination, liver increased in size, organ capsule echogenicity increased, signs of portal hypertension were noted, echogenicity remained unchanged, in a number of cases in increased to heterogeneously hyperechogenic; at that, liver contours remained smooth and clear. Gall bladder walls became more dense and thick, these changes corresponded to hepatitis signs. In all cases, during respiratory excursion organ mobility was preserved.

X-ray examination of liver (fig.3) was performed with animals in right lateral position. The organ was barely discernible on images because liver shadow melted with stomach shadow. Ventrocaudal margin of liver visualized protruding outside the coastal margin, being sharp in this instance (which evidenced insignificant increase of the organ).

According to histological analysis, the morphological pattern of liver tissue of control rabbits corresponded in general to the norm. In histologic specimens, rabbit liver had poorly resolved lobulation. Interlobular septa formed by connective tissue were observed in the triad region only. In triads, interlobular veins were filled with blood, had a thin wall, their lumen was flattened, the lumen of interlobular arteries was roundish. The wall of interlobular bile excretory ducts is lined with single-layer cubic epithelium. In connective tissue around triads, moderate accumulation of lymphoid cells was observed. Central veins of lobes were filled with blood, lined with endothelial cells. Hepatocytes had polygonal shape, one or two basophil stained nuclei. In sinusoid capillaries, endotheliocyte nuclei are identified (fig. 4).

Analysis of the histological pattern of experimental rabbit liver found that liver lobes preserved beam structure. Sinusoid capillaries are narrowed down. In parenchyma, vast diffuse areas of vacuola dystrophy are observed, which are characterized by cytoplasm vacuolization and marginalization of nuclear heterochromatin of hepatocytes. Between cells, focal

accumulations of lymphocytes are observed (fig.5), which evidence presence of pathological processes.

CONCLUSION.

Thus, the investigations performed indicate possibility of using the method described by us for creation of an experimental tetrachloromethane model of toxic lesion of liver in rabbits. Development of toxic hepatitis as early as day 5 of experiment was supported with hematological data characterizing functional insufficiency of liver, and with results of additional functional examinations.

REFERENCES

- [1] Ahmed S.K. International Journal of Stem Cells, 2014, 2, 87-97
- [2] Domenicali M.A. J. Hepatol 2009, 6, 991-999
- [3] Qin Dongmei et al Iran Red Crescent Med J., 2013,12, 1-8
- [4] Goldani H. AExp Toxicol Pathol, 2007, 5, 331-337
- [5] Lessa A.S. et al BMSVetRes 2010, 6, 6-13
- [6] Olaleye M.T. Saudi Journal of Biological Sciences 2014, 21, 486-492
- [7] Hayas H. Physiol Gastrointest Liver Physiol 2011,30, 729-738
- [8] Skuratov A.G. Experimental and Clinical Gastroenterology 2012, 9, 74-83
- [9] Osipov B.B. Contemporary Medicine Challenges and Development Prospects 2012, 3, 108-110
- [10] Ross B. Victorian Government department of primary industries 2004, 70.