

Effect of Carvedilol on Reproductive Function in Female Wistar Rats

Oyedemi K.O.*¹, Amakiri-Whyte T.¹, Oderinde gbenga²

¹Department of Physiology, College of Medicine and Health Sciences, Afe Babalola University, Ado-Ekiti, Nigeria

²Department of Anatomy, College of Medical Sciences, Ahmadu Bello University, Zaria.

Abstract

Aim: This study was designed to investigate the effect of carvedilol on reproductive function in female Wistar rats.

Methods: Sixteen female rats (120 – 160 g) were used for the estrous cycle and histopathological studies. Carvedilol (0.09 mg/kg) was administered orally on daily basis for 21 and 50 days respectively for the estrous cycle and histological studies. Estrous cycle was carried out using the technique of Marcondes *et al.*, histologies of the ovaries and uteri were also carried out. Data were analysed using descriptive statistics and student's t-test at $p=0.05$.

Results: Treatment of rats for 21 days with carvedilol (0.09 mg/kg) produced a significant ($p<0.05$) increase in the proestrous phase with insignificant ($p>0.05$) changes in the estrous, metestrous and diestrous phases of the estrous cycle relative to their respective controls. The histopathological study presented with ovarian medullar that is severely congested (hemorrhagic) including a marked congestion of the endometrium.

Conclusion: It can therefore be concluded that carvedilol probably has anti-fertility effect with some deleterious effects on the ovaries and uteri at histological level in female Wistar rats.

Keywords: Carvedilol, Proestrous, Estrous, Ovaries, Rats.

INTRODUCTION

Carvedilol is a novel adrenergic antagonist that competitively blocks β_1 and β_2 vascular receptors, primarily through a selective α_1 -blockade [1]. The drug has been introduced for the treatment of congestive heart failure, mild to moderate hypertension and myocardial infarction [2, 3]. Carvedilol has been shown to have greater cardioprotective efficacy than other β -blockers in animal models of cardiac ischemia [4] as well as scavenge oxygen free radicals [5] and to inhibit lipid peroxidation in biological systems [6, 7].

It has been reported to decrease portal pressure and endothelial-related vasodilatory activities [8]. It has protective effect on paracetamol-induced hepatotoxicity in rats [9] as well as decreased cleft palate induced by caffeine in rats' embryos in prenatal period [10]. Its effect on reproductive parameters in male Wistar rats has also been reported [11]. However, due to scanty information from literature on the effect of carvedilol on reproductive parameters in female rats, this study therefore aims at investigating the effect of this antiarrhythmic agent on these aforementioned parameters in female rats.

MATERIALS AND METHODS

Experimental Animals

Adult female rats weighing between 120 g – 160 g bred in the Pre-Clinical Animal House of the College of Medicine and Health Sciences, Afe Babalola University were used. They were housed under standard laboratory conditions and had free access to feed and water; they were acclimatized for two weeks to laboratory conditions before the commencement of the experiments. All experiments were carried out in compliance with the recommendations of Afe Babalola University Ethics Committee on guiding principles on care and use of animals.

Drug

Carvedilol tablets (TEVA UK, Ltd) were bought from Danax Pharmacy, Ibadan, Nigeria.

Carvedilol (3.125 mg) was dissolved in 10 ml of distilled water to give a concentration of 0.313 mg/ml.

The dosage of carvedilol used in this study was in accordance with that reported by the manufacturer.

Experimental Design

Study on Estrous Cycle

Six matured female rats showing at least three regular 4 – 5 day cycles were used for this study. Vaginal lavages (smears) were examined microscopically every day at a constant interval of 6.30 – 7.30 a.m. for 21 days before and after treatments with the antiarrhythmic drug. The smears were classified into one of the phases of the estrous cycle using the Marcondes technique [12]. Vaginal secretion was collected with a plastic pipette filled with 10 μ L of normal saline (NaCl 0.9 %) by inserting the tip into the rat's vagina, but not deeply. Vaginal fluid was placed on glass slide. One drop was collected with a clean tip from each rat. Unstained material was observed under a light microscope, without the use of condenser lens, with 10 and 40 x objective lenses. Three types of cells could be recognized: round and nucleated ones are epithelial cells; irregular ones without nucleus are the cornified cells; and the little round ones are the leucocytes. The proportion (preponderance) among them was used for the determination of estrous cycle phases [13, 14]. The duration of the estrous cycle was determined. In this study, the experimental animals also served as the control. The first 21 days served as the control days, while the last 21 days served as the treatment days. Each of the 6 rats for this estrous cycle study received 0.09 mg/kg of carvedilol.

Histopathological Study

In another set of experiment, ten matured female rats divided into two equal groups (five animals per group) received the following treatment of the antiarrhythmic agent and control orally per day for fifty days as follows:

Group I rats received 0.5 ml/100 g of distilled water as the control group.

Group II rats received 0.09 mg/kg of carvedilol.

On the 51st day, all the rats were sacrificed by an overdose of diethyl ether. The ovaries and uteri were dissected out, cleaned of fat and immediately fixed in Bouin's fluid.

Histological preparation of tissues

After weighing the ovaries and uteri, they were immediately fixed in Bouin's fluid for 12 hours and the Bouin's fixative was washed from the samples with 70 % alcohol. The tissues were then cut in slabs of about 0.5 cm transversely and the tissues were dehydrated by passing through different grades of alcohol: 70 % alcohol for 2 hours, 100 % alcohol for 2 hours, and finally 100 % alcohol for 2 hours. The tissues were then cleared to remove the alcohol, the clearing was done for 6 hours using xylene. The tissues were then infiltrated in molten paraffin wax for 2 hours in an oven at 57°C, thereafter the tissues were embedded. Serial sections were cut using rotary microtome at 5 microns (5µm). The satisfactory ribbons were picked up from a water bath (50 -55°C) with microscope slides that had been coated on one slide with egg albumin as an adhesive and the slides were dried in an oven. Each section was deparaffinized in xylene for 1 minute before immersed in absolute alcohol for 1 minute and later in descending grades of alcohols for about 30 seconds each to hydrate it. The slides were then rinsed in water and immersed in alcoholic solutions of hematoxylin for about 18 minutes. The slides were rinsed in water, and then differentiated in 1 % acid alcohol and then put inside a running tap water to blue and then counterstained in alcoholic eosin for 30 seconds and rinsed in water for a few seconds, before being immersed in 70 %, 90 % and twice in absolute alcohol for 30 seconds each to dehydrate the preparations. The preparations were cleared of alcohol by dripping them in xylene for 1 minute. Each slide was then cleaned, blotted and mounted with DPX and cover slip, and examined under the microscope. Photomicrographs were taken at x40 and x100 magnifications.

Statistical Analysis

The mean and standard error of mean (S.E.M.) were calculated for all values. Comparison between the control and the treated group was done using student's t-test. Differences were considered statistically significant at $p < 0.05$.

RESULTS

Treatment of rats for 21 days with carvedilol (0.09 mg/kg) produced a significant ($p < 0.05$) increase in the proestrous phase, but caused insignificant ($p > 0.05$) changes in the estrous, metestrous and diestrous phases of the estrous cycle relative to their respective controls (Fig. 1).

Treatment of rats with carvedilol (0.09 mg/kg) for 50 days presented with ovarian medullar that is severely congested (hemorrhagic) with different developmental stages seen, including the Graffian follicle, contrary to what was observed in the control rats (Plates 1 and 2).

Treatment of rats with carvedilol (0.09 mg/kg) for 50 days presented with a marked congestion of the endometrium contrary to what was observed in the control rats (Plates 3 and 4).

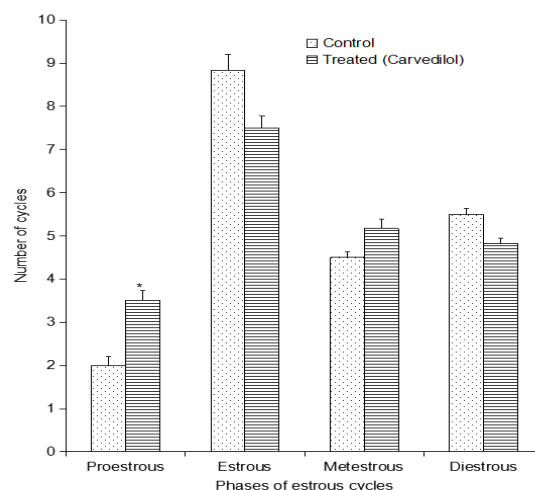


Fig. 1: Effect of 21 days treatment with carvedilol on estrous cycle (n = 6, * $p < 0.05$)

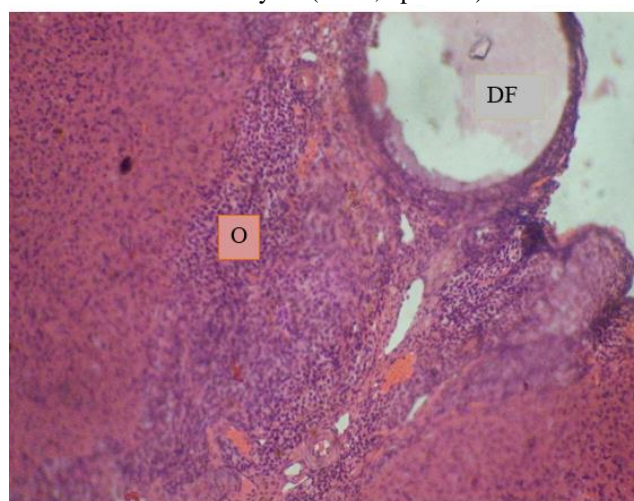


Plate 1: Effect of 0.5 ml distilled water (control) on the ovary at x100.

Photomicrograph showing a normal ovary (O) with a developing follicle (DF).

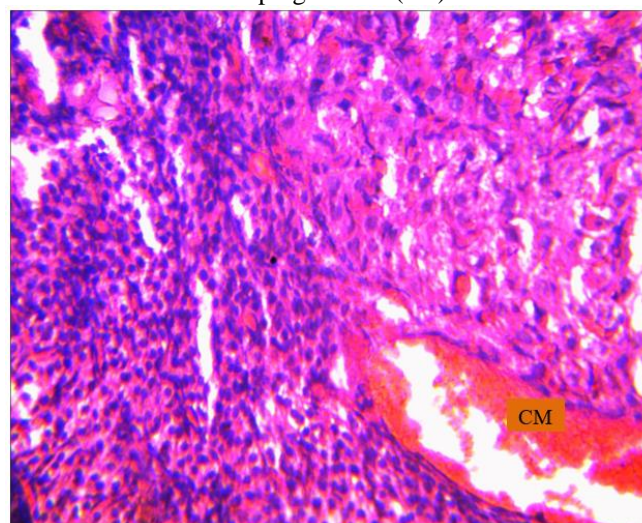


Plate 2: Effect of carvedilol (0.09 mg/kg) on the ovary at x100

Photomicrograph showing an ovary with a severely congested medullar (CM).

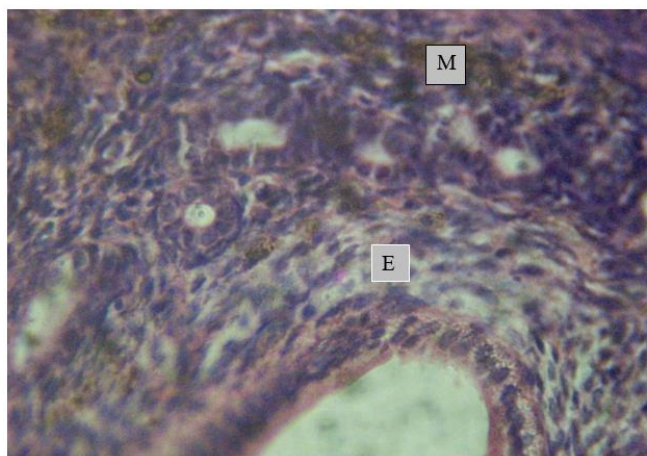


Plate 3: Effect of 0.5 ml distilled water (control) on the uterus at x100.
Photomicrograph showing normal endometria (E) and myometrium (M).

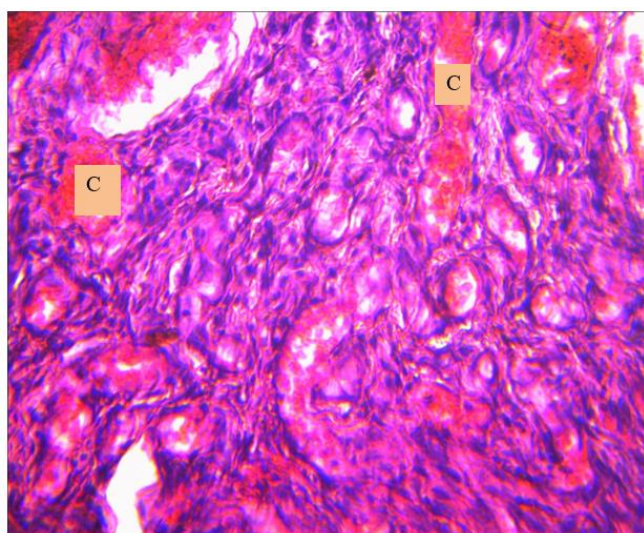


Plate 4: Effect of carvedilol (0.09 mg/kg) on the uterus at x100
Photomicrograph showing marked congestion (C) of the endometrium.

DISCUSSION

The estrous cycle study revealed that carvedilol caused a significant change in the duration of a phase of the estrous cycle. Contrary report was given by [15] in *Portulaca oleracea* extracts treated rats. This suggests that the antiarrhythmic drug caused imbalances of the ovarian and extraovarian hormones, since it has been reported that imbalance in these hormones lead to irregularity in the ovarian functions and duration of the estrous cycle [16]. Treatment of rats with carvedilol caused significant increase in proestrous phase of the estrous cycle which probably indicates that the maturation of the follicles in the preovulatory phase was delayed *vis-a-vis* leading to non-maturation of the Graafian follicles. Similar result was reported by [17] in alcohol treated rats. The ovarian photomicrographs of the carvedilol treated rats presented with congested (hemorrhagic) ovarian medulla which could be due to deep venous thrombosis.

This is similar to the result obtained by [18] in Sumithion treated rats.

The uterine photomicrographs of the carvedilol treated rats presented with marked congestion of the endometrial which could also be due to deep venous thrombosis. Similar result was reported by [19] in their work on the morphometric evaluation of endometrial blood vessels.

It can therefore be concluded that carvedilol probably has anti-fertility effect with some deleterious effects on the ovaries and uteri at histological level in female Wistar rats. However, the effect of carvedilol on human reproductive function is unknown; nevertheless, considering these findings in animal model, it is recommended that women should be cautious about taking this antiarrhythmic agent because of its likely antifertility effect as well as the ovarian and uterine deleterious effects.

Conflict of Interest

We vehemently declare that there is no conflict of interests in this research work.

REFERENCES

- [1] Ruffolo, R.R., Hieble, J.P., Brooks, D.P., Feuerstein, G.Z., Nichols, A.J. Drug receptors and control of the cardiovascular system: Recent advances. *Prog Drug Res* 1991; 36: 117-360.
- [2] Matsui, H., Morishima, I., Numaguchi, Y., Toki, Y., Okumura, K., Hayakawa, T. Protective effect of carvedilol against doxorubicin-induced cardiomyopathy in rats. *Life Sci* 1999; 65: 1265-1274.
- [3] Feuerstein, G.Z., Bril, A., Ruffolo, R.R. Protective effects of carvedilol in the myocardium. *Am J Cardiol*. 1997; 80: 41-4 5.
- [4] Feuerstein, G.Z., Hamburger, S.A., Smith, E.F., Bril, A., Ruffolo, R.R. Myocardial protection with carvedilol. *J Cardiovasc Pharmacol* 1992; 19: 138-1 41.
- [5] Yue, T.L., McKenna, P.J., Gu, J.L., Cheng, H.Y., Ruffolo, R.E., Feuerstein, G.Z. Carvedilol, a new vasodilating beta adrenoceptor blocker antihypertensive drug, protects endothelial cells from damage initiated by xanthine-xanthine oxidase and neutrophils. *Cardiovasc Res* 1994; 28: 400-406.
- [6] Yue, T.L., Cheng, H.Y., Lysko, P.G., McKenna, P.J., Gu, R. et al. Carvedilol, a new vasodilator and beta adrenoceptor antagonist, is an antioxidant and free radical scavenger. *J Pharmacol Exp Ther* 1992; 263: 92-98.
- [7] Kramer, J.H., Weglicki, W.B. A hydroxylated analog of the beta-adrenoceptor antagonist, carvedilol, affords exceptional antioxidant protection to postischemic rat hearts. *Free Radic Biol Med* 1996; 21: 813-825.
- [8] Lin, H.C., Huang, Y.T., Wei, H.C., Yang, Y.Y., Lee, T.Y., Wang, Y.W., Hou, M.C., Lee, S.D. Hemodynamic effects of one week of carvedilol administration on cirrhotic rats. *J Gastroenterol* 2006; 41(4): 361-368.
- [9] Heba, M., Mahmoud, A.M., Abo, Y., Ali, A., Abo, S. Protective effect of carvedilol on paracetamol-induced hepatotoxicity; role of modulation inflammation and lipid peroxidation. *Int J Pharm* 2017; 13 (1): 33-43.
- [10] Rashidi, F., Mahmood, K.M., Ranjbar, R., Najafzadeh, V.H. The effects of caffeine and carvedilol on skeletal system of rat embryo in prenatal period. *Afr J Pharm Pharmacol* 2012; 6 (29): 2229-2234.
- [11] Oyedeji, K.O., Abidoye, A.O., Shallangwa, M.M.1, Zachariah, R. Effect of carvedilol on reproductive parameter in male Wistar rats. *J Pharm Sci Res* 2019; 11(12): 3749-3753.
- [12] Marcondes, F.K., Bianchi, F.J., Tanno, A.P. Determination of the estrous cycle phases of rats: some helpful considerations. *Braz J Bio* 2002; 62 (4a): 609 – 614
- [13] Long, J.A., Evans, H.M. The estrous cycle in the rat and its associated phenomena. *Memo Uni Calif* 1922; 6: 1-148.
- [14] Mandl, A.M. The phases of the oestrous cycle in the adult white rat. *J Exptl Bio* 1951; 28: 576-5 84.
- [15] Oyedeji, K.O., Bolarinwa, A.F. Effects of extracts of *Portulaca oleracea* on reproductive functions in female albino rats. *Afr J Biomed Res* 2010; 13: 213-218.

- [16] Circosta, C., Sanogo, R., Occhiuto, F. Effects of *Calotropis procera* on estrous cycle and on estrogenic functionality in rats. *Farmacologia* 2001; 56: 373-378.
- [17] Oyedeji, K.O., Bolarinwa, A.F., Azeez, A.A. Effect of effect of methanolic extract of *Vernonia amygdalina* on reproductive parameters in male rats. *Asian J Pharm Clin Res* 2013; 6 (2): 1-4.
- [18] Mohammed, O.A., Amen, S.B.B. Testicular histopathological alterations in rats treated with Sumithion* NP 25/2.5 EC, Insecticide. *J Biol Sc* 2007; 7(3): 520-525.
- [19] Divya, M., Alka, M.M., Ramadas, N., Suneet, K., Sharada, R., Muktha, R.P., Poornima, B. Morphometric evaluation of endometrial blood vessels. *Indian J Path Microbio* 2008; 51 (3): 346-350.