

Effect of Losartan (Angiotensin II Antagonist) on Reproductive Function in Female Wistar Rats

Oyedemi K.O.*¹, Akaduchieme C.H.¹, Oderinde gbenga²

¹Department of Physiology, College of Medicine and Health Sciences, Afe Babalola University, Ado-Ekiti, Nigeria

²Department of Anatomy, College of Medical Sciences, Ahmadu Bello University, Zaria.

Abstract

Aim: This study was designed to investigate the effect of losartan on reproductive function in female Wistar rats.

Methods: Sixteen female rats (120 – 160 g) were used for the estrous cycle and histopathological studies. Losartan (1.43 mg/kg) was administered orally on daily basis for 21 and 50 days respectively for the estrous cycle and histological studies. Estrous cycle was carried out using the technique of Marcondes *et al.*, histologies of the ovaries and uteri were also carried out. Data were analysed using descriptive statistics and student's t-test at $p=0.05$.

Results: Treatment of rats for 21 days with losartan (1.43 mg/kg) produced no significant ($p>0.05$) changes in all the different phases of estrous cycle relative to their respective controls, as well as induced no pathological effects on the ovarian and uterine tissues in the rats.

Conclusion: It can therefore be concluded that losartan probably has no effect on fertility as well as exhibited non-deleterious effect on the reproductive organs of female Wistar rats.

Keywords: Losartan, Proestrous, Estrous, Ovaries, Rats.

INTRODUCTION

Losartan is an angiotensin II receptor antagonist drug used mainly to treat high blood pressure (hypertension). Losartan may also delay progression of diabetic nephropathy and is associated with a positive clinical outcome in that regard. It is a suitable pharmacological agent for the reduction of renal disease progression in patients with type 2 diabetes, hypertension, and microalbuminuria or proteinuria [1].

Losartan has been reported to have a protective effect in mice with chronic viral myocarditis induced by coxsackievirus B3 [2]. Its additive effect in (mREN-2) 27 transgenic rats has been reported [3]. Acute peripheral administration of losartan has been reported to decrease striatal dopamine levels in rats [4]. It has been reported that losartan reduced ensuing chronic kidney disease and mortality after acute kidney injury in mice [5]. The inhibitory effect of losartan on increased leucocyte entrapment in retinal microcirculation of diabetic rats has also been reported [6]. Losartan attenuates renal interstitial fibrosis and tubular cell apoptosis in a rat model of obstructive nephropathy [7] as well as inhibits collagen I synthesis and improves the distribution and efficacy of nanotherapeutics in tumors [8]. Its effects on haematological and biochemical parameters in male Wistar rats have also been reported [9]. However, due to scanty information from literature on the effect of losartan on reproductive parameters in female rats, this study therefore aims at investigating the effect of this antihypertensive agent on these aforementioned parameters in female rats.

MATERIALS AND METHODS

Experimental Animals

Adult female rats weighing between 120 g – 160 g bred in the Pre-Clinical Animal House of the College of Medicine and Health Sciences, Afe Babalola University were used. They were housed under standard laboratory conditions and had free access to feed and water; they were

acclimatized for two weeks to laboratory conditions before the commencement of the experiments. All experiments were carried out in compliance with the recommendations of Afe Babalola University Ethics Committee on guiding principles on care and use of animals.

Drug

Angiotensin II receptor antagonist (Losartan) tablets (TEVA UK, Ltd.) were bought from Danax Pharmacy, Ibadan, Nigeria.

Losartan (50 mg) was dissolved in 10 ml of distilled water to give a concentration of 5.0 mg/ml.

The dosage of losartan used in this study was in accordance with that reported by the manufacturer.

Experimental Design

Study on Estrous Cycle

Six matured female rats showing at least three regular 4 – 5 day cycles were used for this study. Vaginal lavages (smears) were examined microscopically every day at a constant interval of 6.30 – 7.30 a.m. for 21 days before and after treatments with the antihypertensive drug. The smears were classified into one of the phases of the estrous cycle using the Marcondes technique [10]. Vaginal secretion was collected with a plastic pipette filled with 10 μ L of normal saline (NaCl 0.9 %) by inserting the tip into the rat's vagina, but not deeply. Vaginal fluid was placed on glass slide. One drop was collected with a clean tip from each rat. Unstained material was observed under a light microscope, without the use of condenser lens, with 10 and 40 x objective lenses. Three types of cells could be recognized: round and nucleated ones are epithelial cells; irregular ones without nucleus are the cornified cells; and the little round ones are the leucocytes. The proportion (preponderance) among them was used for the determination of estrous cycle phases [11, 12]. The duration of the estrous cycle was determined. In this study, the experimental animals also served as the control. The first 21 days served as the control days, while the last 21

days served as the treatment days. Each of the 6 rats for this estrous cycle study received 1.43 mg/kg of losartan.

Histopathological Study

In another set of experiment, ten matured female rats divided into two equal groups (five animals per group) received the following treatment of the antihypertensive agent and control orally per day for fifty days as follows:

Group I rats received 0.5 ml/100 g of distilled water as the control group.

Group II rats received 1.43 mg/kg of losartan.

On the 51st day, all the rats were sacrificed by an overdose of diethyl ether. The ovaries and uteri were dissected out, cleaned of fat and immediately fixed in Bouin's fluid.

Histological preparation of tissues

After weighing the ovaries and uteri, they were immediately fixed in Bouin's fluid for 12 hours and the Bouin's fixative was washed from the samples with 70 % alcohol. The tissues were then cut in slabs of about 0.5 cm transversely and the tissues were dehydrated by passing through different grades of alcohol: 70 % alcohol for 2 hours, 100 % alcohol for 2 hours, and finally 100 % alcohol for 2 hours. The tissues were then cleared to remove the alcohol, the clearing was done for 6 hours using xylene. The tissues were then infiltrated in molten paraffin wax for 2 hours in an oven at 57°C, thereafter the tissues were embedded. Serial sections were cut using rotary microtome at 5 microns (5µm). The satisfactory ribbons were picked up from a water bath (50 -55°C) with microscope slides that had been coated on one slide with egg albumin as an adhesive and the slides were dried in an oven. Each section was deparaffinized in xylene for 1 minute before immersed in absolute alcohol for 1 minute and later in descending grades of alcohols for about 30 seconds each to hydrate it. The slides were then rinsed in water and immersed in alcoholic solutions of hematoxylin for about 18 minutes. The slides were rinsed in water, and then differentiated in 1 % acid alcohol and then put inside a running tap water to blue and then counterstained in alcoholic eosin for 30 seconds and rinsed in water for a few seconds, before being immersed in 70 %, 90 % and twice in absolute alcohol for 30 seconds each to dehydrate the preparations. The preparations were cleared of alcohol by dripping them in xylene for 1 minute. Each slide was then cleaned, blotted and mounted with DPX and cover slip, and examined under the microscope. Photomicrographs were taken at x40 and x100 magnifications.

Statistical Analysis

The mean and standard error of mean (S.E.M.) were calculated for all values. Comparison between the control and the treated group was done using student's t-test. Differences were considered statistically significant at $p < 0.05$.

RESULTS

Treatment of rats for 21 days with losartan (1.43 mg/kg) produced no significant ($p > 0.05$) changes in all the

different phases of estrous cycle (Proestrous, estrous, metestrous and diestrous) relative to their respective controls (Fig. 1).

Treatment of rats with losartan (1.43 mg/kg) for 50 days produced no pathological effects on the ovaries (with no matured follicles seen), which is similar to what was observed in the control rats (Plates 1 and 2).

Treatment of rats with losartan (1.43 mg/kg) for 50 days produced no pathological effects on the uteri (with a considerable development of the endometrial glands), which is similar to what was observed in the control rats (Plates 3 and 4).

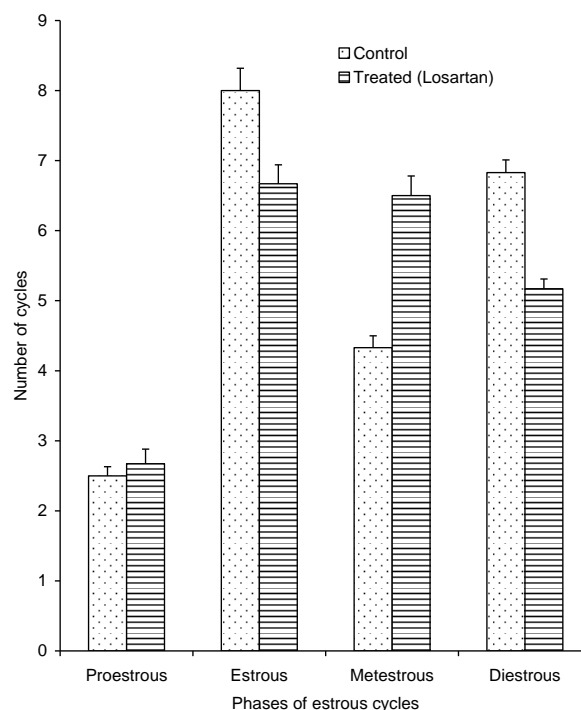


Fig. 1: Effect of 21 days treatment with losartan on estrous cycle (n = 6, * $p < 0.05$)

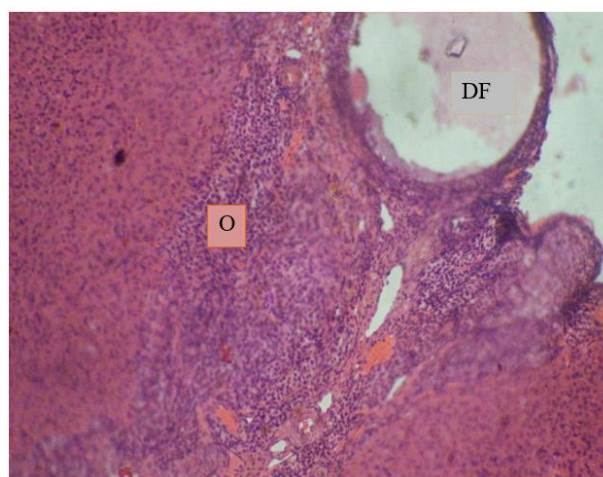


Plate 1: Effect of 0.5ml distilled water (control) on the ovary at x100.

Photomicrograph showing a normal ovary (O) with a developing follicle (DF).

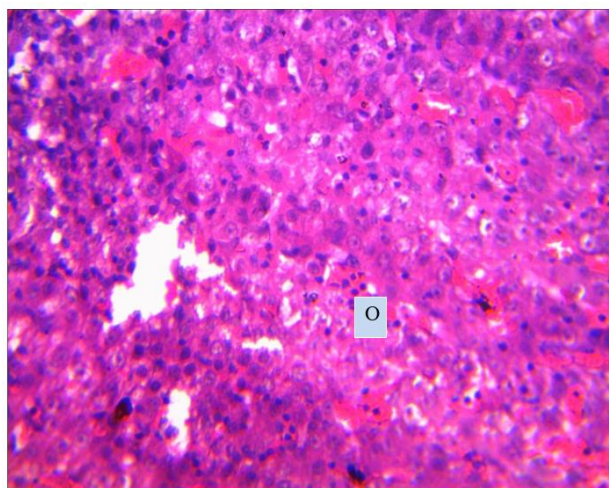


Plate 2: Effect of losartan (1.43 mg/kg) on the ovary at x100
Photomicrograph showing an ovary (O) with no pathologic lesion present.

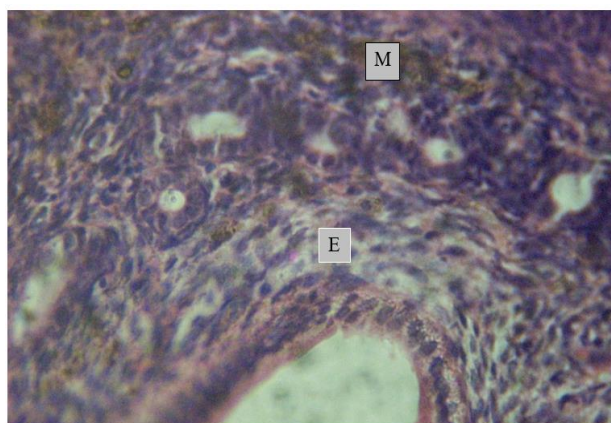


Plate 3: Effect of 0.5 ml distilled water (control) on the uterus at x100.
Photomicrograph showing normal endometria (E) and myometrium (M).

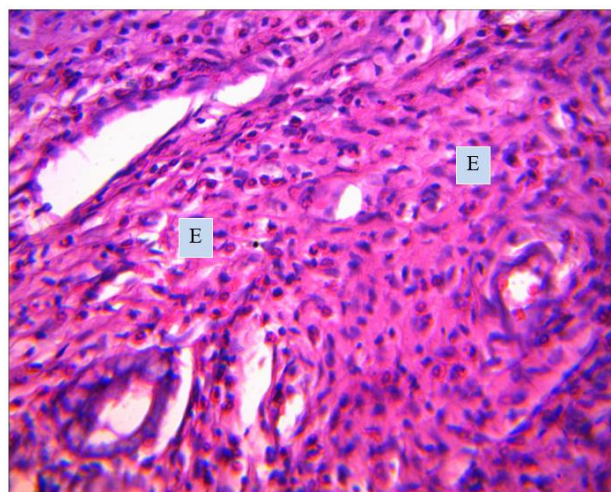


Plate 4: Effect of losartan (1.43 mg/kg) on the uterus at x100
Photomicrograph showing endometrial (E) layer with no pathologic lesion seen.

DISCUSSION

The estrous cycle study revealed that losartan produced no significant changes in the duration of all the phases of the estrous cycle. Similar report was given by [13] in *Portulaca oleracea* extracts treated rats. This suggests that the antihypertensive drug did not cause imbalance of the ovarian and extraovarian hormones, since it has been reported that imbalance in these hormones lead to irregularity in the ovarian functions and duration of the estrous cycle [14]

The ovarian photomicrographs of the losartan treated rats showed no pathologic lesion present which suggests the non-toxic effect of the drug on the ovaries at histological level. Similar results were reported by [13] in *Portulaca oleracea* treated rats.

The uterine photomicrographs of losartan treated rats presented with no pathologic lesion which probably indicate the non-toxic effect of the drug on the uteri at histological level. Similar results were reported by [15] in *Allium sativum* extract treated rats.

It can therefore be concluded that losartan probably has no effect on fertility as well as exhibited non-deleterious effect on the reproductive tissues of female Wistar rats.

Conflict of Interest

We vehemently declare that there is no conflict of interests in this research work.

REFERENCES

- [1] Boersma C, Atthobari J, Gansevoort RT, et al. "Pharmacoeconomics of angiotensin II antagonists in type 2 diabetic patients with nephropathy: implications for decision making". *Pharmacoeconomics* 2006; 24 (6): 523-535.
- [2] Zhang YY, Li JN, Xia HH, et al. Protective effects of losartan in mice with chronic viral myocarditis induced by coxsackievirus B3. *Life Sci* 2013; 92 (24-26): 1186-1194.
- [3] Richer C, Bruneval P, Ménard J, Giudicelli JF. Additive effects of enalapril and losartan in (mREN-2) 27 transgenic rats. *Hypertension* 1998; 31 (2): 692-698.
- [4] Mendelsohn FA, Jenkins TA, Berkovic SF. Effects of angiotensin II on dopamine and serotonin turnover in the striatum of conscious rats. *Brain Res* 1993; 613: 221-229.
- [5] Cheng SY, Chou YH, Liao FL, et al. Losartan reduces ensuing chronic kidney disease and mortality after acute kidney injury. *Sci Reports* 2016; 6: 34265.
- [6] Mori F, Hikichi T, Nagaoka T, et al. Inhibitory effect of losartan, an AT1 angiotensin II receptor antagonist, on increased leucocyte entrapment in retinal microcirculation of diabetic rats. *Br J Ophthalmol* 2002; 86: 1172-1174.
- [7] He P, Li D, Zhang B. Losartan attenuates renal interstitial fibrosis and tubular cell apoptosis in a rat model of obstructive nephropathy. *Molecular Medicine Reports* 2014;10: 638-644.
- [8] Diop-Frimpong B, Chauhan VP, Krane S, Boucher Y, Jain RK. Losartan inhibits collagen I synthesis and improves the distribution and efficacy of nanotherapeutics in tumors. *Proc Natl Acad Sci* 2011; 108 (7): 2909-2914.
- [9] Oyedeki KO, Okeke OE, Talabi YJ, Oyawale G. Effect of losartan (angiotensin II antagonist) on haematological and biochemical parameters in male Wistar rats. *J Pharm Sci Res* 2018; 10 (5): 995-998.
- [10] Marcondes FK, Bianchi FJ, Tanno AP. Determination of the estrous cycle phases of rats: some helpful considerations. *Braz J Bio* 2002; 62 (4a): 609 - 614
- [11] Long JA, Evans HM. The estrous cycle in the rat and its associated phenomena. *Memo Uni Califor* 1922; 6: 1-148.
- [12] Mandl AM. The phases of the oestrous cycle in the adult white rat. *J Exptal Bio* 1951; 28: 576-5 84.

- [13] Oyedeji KO, Bolarinwa AF. Effects of extracts of *Portulaca oleracea* on reproductive functions in female albino rats. Afr J Biomed Res 2010; 13: 213-218.
- [14] Circosta C, Sanogo R., Occhiuto F. Effects of *Calotropis procera* on estrous cycle and on estrogenic functionality in rats. Farmaco 2001; 56: 373-378.
- [15] Raji LO, Fayemi OE, Ameen SA, Jagun AT. The effects of aqueous extract of *Allium sativum* (Garlic) on some aspects of reproduction in the female albino rats. Global Vet 2012; 8 (4): 414-420.