

Effect of Diclofenac on Reproductive Function in Female Wistar Rats

Oyedeji K.O.*¹, Kpaduwa P.C.¹

¹Department of Physiology,
College of Medicine and Health Sciences,
Afe Babalola University, Ado-Ekiti, Nigeria. .

Abstract

Aim: This study was designed to investigate the effect of diclofenac on reproductive function in female Wistar rats.

Methods: Fifteen female rats (120 – 160 g) were used for the estrous cycle and histopathological studies. Diclofenac (1.43 mg/kg) was administered orally on daily basis for 21 and 50 days respectively for the estrous cycle and histological studies. Estrous cycle was carried out using the technique of Marcondes *et al.*, histologies of the ovaries and uteri were also carried out. Data were analysed using descriptive statistics and student's t-test at $p=0.05$.

Results: Treatment of rats for 21 days with diclofenac (1.43 mg/kg) produced significant ($p<0.05$) increments in the estrous and metestrous phases as well as a significant ($p<0.05$) reduction in the proestrous phase of the estrous cycle relative to their respective controls. The histopathological study presented with ovarian medullar that is congested (hemorrhagic) and oedematous.

Conclusion: It can therefore be concluded that diclofenac probably has pro-fertility effect with deleterious effect on the ovaries at histological level in female Wistar rats.

Keywords: Diclofenac, Proestrous, Estrous, Ovaries, Rats.

INTRODUCTION

Diclofenac (a phenylacetic acid derivative) is a nonsteroidal anti-inflammatory drug (NSAID) used to treat pain and inflammatory diseases such as gout. It is taken by mouth, rectally in a suppository, used by injection, or applied to the skin. Improvements in pain last for as much as eight hours [1]. It competes with arachidonic acid for binding to cyclo-oxygenase (COX), resulting in decreased formation of prostaglandins. This decrease effect at least partly explains the mechanism of action of the drug [2, 3].

The preemptive analgesic effect of diclofenac in experimental rats has been reported [4]. Its haematological and biochemical effects in *Rattus norvegicus* have been reported [5]. Investigation of possible cardiac side effect of diclofenac in exercise-treated rats has been reported [6]. Its Pharmacokinetics in rats intoxicated with CCL₄ and in the regenerating liver has been reported [7]. The pharmacokinetic-pharmacodynamic modeling of the antinociceptive effect of diclofenac in the rats has also been reported [8]. However, due to scanty information from literature on the effect of diclofenac on reproductive parameters in female rats, this study therefore aims at investigating the effect of this NSAID on these aforementioned parameters in female rats.

MATERIALS AND METHODS

Experimental Animals

Adult female rats weighing between 120 g – 160 g bred in the Pre-Clinical Animal House of the College of Medicine and Health Sciences, Afe Babalola University were used. They were housed under standard laboratory conditions and had free access to feed and water; they were acclimatized for two weeks to laboratory conditions before the commencement of the experiments. All experiments were carried out in compliance with the recommendations

of Afe Babalola University Ethics Committee on guiding principles on care and use of animals.

Drug

Diclofenac tablets (Shalina Laboratories Pvt. Ltd., India) were bought from Danax Pharmacy, Ibadan, Nigeria.

Diclofenac (50 mg) was dissolved in 10 ml of distilled water to give a concentration of 5.0 mg/ml.

The dosage of diclofenac used in this study was in accordance with that reported by the manufacturer.

Experimental Design

Study on Estrous Cycle

Five matured female rats showing at least three regular 4 – 5 day cycles were used for this study. Vaginal lavages (smears) were examined microscopically every day at a constant interval of 4.30 – 5.30 p.m. for 21 days before and after treatments with the NSAID. The smears were classified into one of the phases of the estrous cycle using the Marcondes technique [9]. Vaginal secretion was collected with a plastic pipette filled with 10 μ L of normal saline (NaCl 0.9 %) by inserting the tip into the rat's vagina, but not deeply. Vaginal fluid was placed on glass slide. One drop was collected with a clean tip from each rat. Unstained material was observed under a light microscope, without the use of condenser lens, with 10 and 40 x objective lenses. Three types of cells could be recognized: round and nucleated ones are epithelial cells; irregular ones without nucleus are the cornified cells; and the little round ones are the leucocytes. The proportion (preponderance) among them was used for the determination of estrous cycle phases [10, 11]. The duration of the estrous cycle was determined. In this study, the experimental animals also served as the control. The first 21 days served as the control days, while the last 21 days served as the treatment days. Each of the 5 rats for this estrous cycle study received 1.43 mg/kg of diclofenac.

Histopathological Study

In another set of experiment, ten matured female rats divided into two equal groups (five animals per group) received the following treatment of the NSAID and control (orally) per day for fifty days as follows:

Group I rats received 0.5 ml/100 g of distilled water as the control group.

Group II rats received 1.43 mg/kg of diclofenac.

On the 51st day, all the rats were sacrificed by an overdose of chloroform. The ovaries and uteri were dissected out, cleaned of fat and immediately fixed in Bouin's fluid.

Histological preparation of tissues

After weighing the ovaries and uteri, they were immediately fixed in Bouin's fluid for 12 hours and the Bouin's fixative was washed from the samples with 70 % alcohol. The tissues were then cut in slabs of about 0.5 cm transversely and the tissues were dehydrated by passing through different grades of alcohol: 70 % alcohol for 2 hours, 100 % alcohol for 2 hours, and finally 100 % alcohol for 2 hours. The tissues were then cleared to remove the alcohol, the clearing was done for 6 hours using xylene. The tissues were then infiltrated in molten paraffin wax for 2 hours in an oven at 57°C, thereafter the tissues were embedded. Serial sections were cut using rotary microtome at 5 microns (5µm). The satisfactory ribbons were picked up from a water bath (50 -55°C) with microscope slides that had been coated on one slide with egg albumin as an adhesive and the slides were dried in an oven. Each section was deparaffinized in xylene for 1 minute before immersed in absolute alcohol for 1 minute and later in descending grades of alcohols for about 30 seconds each to hydrate it. The slides were then rinsed in water and immersed in alcoholic solutions of hematoxylin for about 18 minutes. The slides were rinsed in water, and then differentiated in 1 % acid alcohol and then put inside a running tap water to blue and then counterstained in alcoholic eosin for 30 seconds and rinsed in water for a few seconds, before being immersed in 70 %, 90 % and twice in absolute alcohol for 30 seconds each to dehydrate the preparations. The preparations were cleared of alcohol by dripping them in xylene for 1 minute. Each slide was then cleaned, blotted and mounted with DPX and cover slip, and examined under the microscope. Photomicrographs were taken at x40 and x100 magnifications.

Statistical Analysis

The mean and standard error of mean (S.E.M.) were calculated for all values. Comparison between the control and the treated group was done using student's t-test. Differences were considered statistically significant at $p < 0.05$.

RESULTS

Treatment of rats for 21 days with diclofenac (1.43 mg/kg) produced significant ($p < 0.05$) increments in the estrous and metestrous phases as well as a significant ($p < 0.05$) reduction in the proestrous phase of the estrous cycle relative to their respective controls (Figure 1).

Treatment of rats with diclofenac (1.43 mg/kg) for 50 days presented with medullary areas that are congested and oedematous, contrary to what was observed in the control rats (Plates 1 and 2).

Treatment of rats with diclofenac (1.43 mg/kg) for 50 days produced no pathological effects on the uteri, which is similar to what was observed in the control rats (Plates 3 and 4).

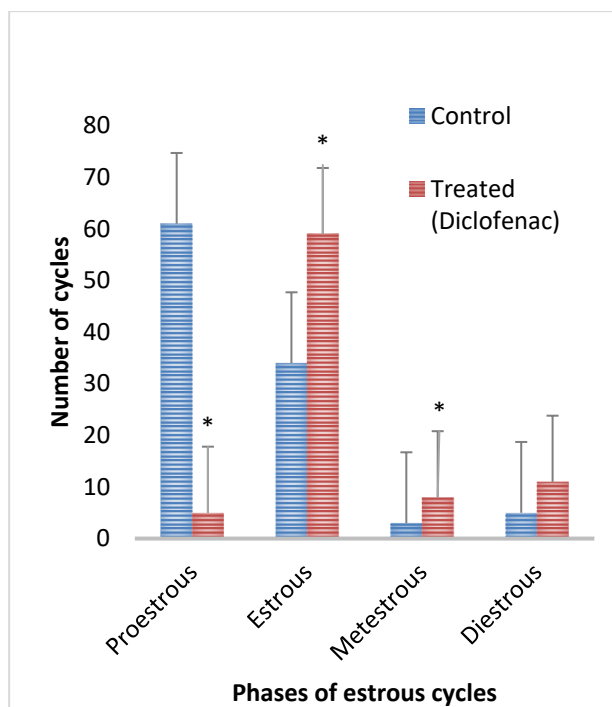


Figure 1: Effect of 21 days treatment with diclofenac on estrous cycle (n = 5, $*p < 0.05$)

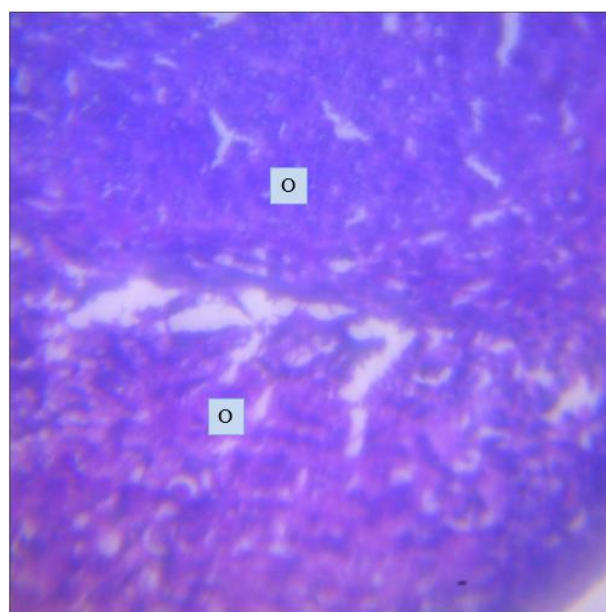


Plate 1: Effect of 0.5 ml/100 g distilled water (control) on the ovary at x400.

Photomicrograph showing a normal ovary (O) with no visible lesions seen.

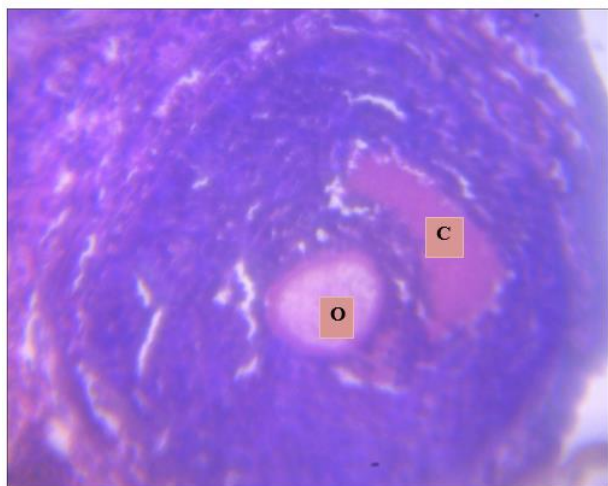


Plate 2: Effect of diclofenac (1.43 mg/kg) on the ovary at x400. Photomicrograph showing an ovary with a congested (C) and oedematous (O) medullary area.

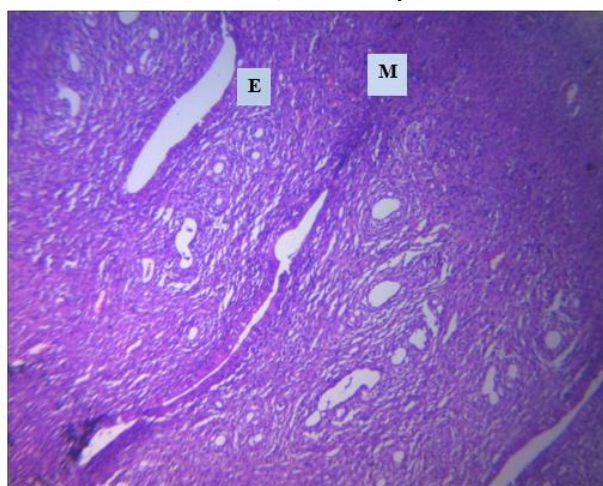


Plate 3: Effect of 0.5 ml/100 g distilled water (control) on the uterus at x400.

Photomicrograph showing normal endometria (E) and myometrium (M) no visible lesions seen.

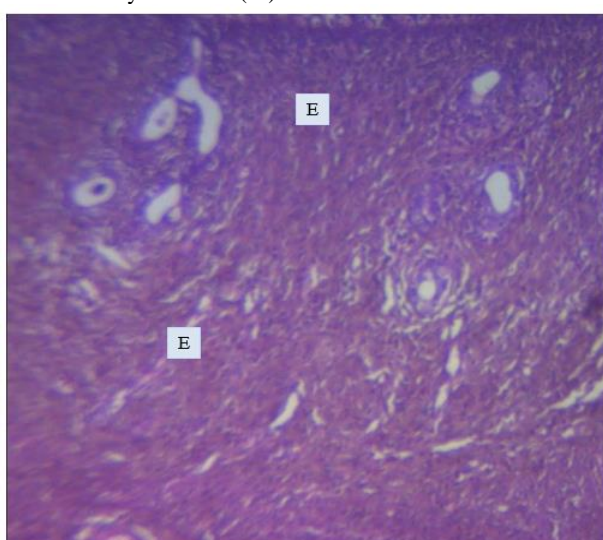


Plate 4: Effect of diclofenac (1.43 mg/kg) on the uterus at x400. Photomicrograph showing endometrial (E) layer with no pathologic lesions present.

DISCUSSION

The estrous cycle study revealed that diclofenac caused significant changes in the duration of different phases of the estrous cycle. Contrary report was given by [12] in *Portulaca oleracea* extracts treated rats. This suggests that the NSAID caused imbalances of the ovarian and extraovarian hormones, since it has been reported that imbalance in these hormones lead to irregularity in the ovarian functions and duration of the estrous cycle [13]. Treatment of rats with diclofenac caused significant decrease in proestrous phase of the estrous cycle which probably indicates that the maturation of the follicles in the preovulatory phase was hastened leading to maturation of the Graafian follicles. Contrary result was reported by [14] in alcohol treated rats. Treatment of rats with diclofenac caused significant increase in estrous phase of the estrous cycle which suggests the availability of matured Graafian follicles and would lead to ovulation. Similar result was reported by [15] in alcohol treated rats. Also, treatment of rats with diclofenac caused significant increase in metestrous phase of the estrous cycle which probably indicates the availability of matured Graafian follicles. Similar result was given by [16] in tetracycline treated rats.

The ovarian photomicrographs of the diclofenac treated rats presented with congested (hemorrhagic) ovarian medulla which could be due to venous thrombosis. This is similar to the result obtained by [17] in Sumithion treated rats. It also presented with oedematous ovarian medulla. It has been reported that there were five pathophysiologic causes of oedema which can be due to: (i) increased hydrostatic pressure (ii) reduced oncotic pressure (iii) lymphatic obstruction (iv) sodium retention or (v) inflammation [18]. Hence, the oedema induced by this drug might be caused by any of the aforementioned causes. Similar result was reported by [19] in mercury vapour treated rats.

The uterine photomicrographs of the diclofenac treated rats presented with no pathologic lesions which probably indicate the non-toxic effect of the drug on the uteri at histological level. Similar results were reported by [20] in *Allium sativum* extract treated rats.

It can therefore be concluded that diclofenac probably has pro-fertility effect with deleterious effect on the ovaries at histological level in female Wistar rats. However, the effect of drug on human reproductive function is unknown; nevertheless, considering these findings in animal model, it is recommended that women with infertility problems could take diclofenac for infertility therapeutic purpose.

Conflict of Interest

We vehemently declare that there is no conflict of interests in this research work.

REFERENCES

- [1] Diclofenac (2018). Drugs.com. Retrieved 22 December 2018.
- [2] Small RE. Diclofenac sodium. J Clin Pharmacol. 1989; 8 (8): 545-558.
- [3] Vane JR, Botting RM. Mechanism of action of anti-inflammatory drugs. Scand J Rheumatol - Suppl. 1996; 102: 9-21.

- [4] Hasani AS, Soljakova M, Jakupi MH, Ustalar-Ozgen SZ. Preemptive analgesic effect of diclofenac: experimental study in rats. *M.E.J. Anesth.* 2011; 21 (3): 355-360.
- [5] Orinya OA, Adenkola AY, Ogbe RJ. Haematological and biochemical studies on the effect of diclofenac sodium on Wistar *Rattus norvegicus*. *Int J Biol Chem Sci.* 2016; 10 (5): 2231-2242.
- [6] Erdal T, Sefa L. Investigation of possible cardiac side effects of diclofenac in exercise-treated rats. *Biomed Res.* 2017; 28 (17): 7675-7678.
- [7] Reyes-Gordillo K, Muriel P, Castañeda-Hernández G, Favari L. Pharmacokinetics of diclofenac in rats intoxicated with CCL₄, and in the regenerating liver. *Biopharmaceut & Drug Disposit.* 2007; 28 (8): 415-422.
- [8] Torres-López JE, López-Muñoz FJ, Castañeda-Hernández G, Flores-Murrieta FJ, Granados-Soto V. Pharmacokinetic-pharmacodynamic modeling of the antinociceptive effect of diclofenac in the rat. *J Pharmacol Exptal Therap.* 1997; 282 (2): 685-690.
- [9] Marcondes FK, Bianchi FJ, Tanno AP. Determination of the estrous cycle phases of rats: some helpful considerations. *Braz J Bio.* 2002; 62 (4a): 609 – 614.
- [10] Long JA, Evans HM. The estrous cycle in the rat and its associated phenomena. *Memo Uni Califor.* 1922; 6: 1-148.
- [11] Mandl AM. The phases of the oestrous cycle in the adult white rat. *J Exptal Bio.* 1951; 28: 576-5 84.
- [12] Oyedeji KO, Bolarinwa AF. Effects of extracts of *Portulaca oleracea* on reproductive functions in female albino rats. *Afr J Biomed Res.* 2010; 13: 213-218.
- [13] Circosta C, Sanogo R, Occhiuto F. Effects of *Calotropis procera* on estrous cycle and on estrogenic functionality in rats. *Farmacol.* 2001; 56: 373-378.
- [14] Oyedeji KO, Bolarinwa AF, Azeez, AA. Effect of effect of methanolic extract of *Vernonia amygdalina* on reproductive parameters in male rats. *Asian J Pharm Cli Res.* 2013; 6 (2): 1-4.
- [15] Oyedeji KO, Bolarinwa AF, Fashina AM. Effect of alcohol consumption on hematological and reproductive parameters in female albino rats. *IOSR J Dent Med Sci.* 2013; 3 (5):76-79.
- [16] Oyedeji KO, Bolarinwa AF, Afolabi OA. Effect of tetracycline on haematological and reproductive parameters in female albino rats. *Asian J Pharm and Clin Res.* 2013; 6 (2): 227-229.
- [17] Mohammed OA, Amen SBB. Testicular histopathological alterations in rats treated with Sumithion* NP 25/2.5 EC, Insecticide. *J Biol Sc.* 2007; 7(3): 520-525.
- [18] Kumar, Abbas, Fausto (1999): *Pathologic Basic of Disease*, 7th edition China: Elsevier Saunders, 122.
- [19] Altunkaynak BZ, Akgül N, Yahyazadeh A, Altunkaynak ME, Turkmen AP, Akgül HM, Ünal B. Effect of mercury vapor inhalation on rat ovary: stereology and histopathology. *J Obstet Gynaecol Res.* 2016; 42 (4): 410-416.
- [20] Raji LO, Fayemi OE, Ameen SA, Jagun AT. The effects of aqueous extract of *Allium sativ um* (Garlic) on some aspects of reproduction in the female albino rats. *Global Vet.* 2012; 8 (4): 414-420.