

# Lasers in Oral and Maxillofacial Surgery- A Review

S. Srivastava<sup>1\*</sup>, V. Ebenezer<sup>2</sup> and R. Balakrishnan<sup>3</sup>

Sree Balaji Dental College and Hospital,  
Velachery Rd, VGP Rajesh Nagar, Pallikaranai, Chennai, Tamil Nadu 600100

\* swastika5srivastava@gmail.com

## Abstract:

LASERS are more common in treating oral and maxillofacial surgery, because of their efficacy and portability. Lasers have revolutionized dental treatment over the decades of the twentieth century. Theodore Maiman 1960 invented the ruby laser, and since then in dental practice laser is one of the most captivating technologies. They are used in periodontal therapy, oral surgical procedures, and implant treatment. Further research is necessary to make LASER part of the dental armamentarium. This article provides insight into the uses of lasers in Oral & Maxillofacial Surgery.

**Keywords:** Lasers, Applications, Oral and Maxillofacial surgery, Review

## INTRODUCTION:

“Light Amplification by Stimulated Emission of Radiation” is an acronym for “LASER”. A laser converts light or electrical energy into a pointed or focused high-energy beam. LASER was first invented by Theoder Maiman in 1960 and later introduced into dentistry by Goldner et al in 1965. Laser characteristics include coherent, collimated, monochromatic light beams. In 1970 by Strong et al, malignant and premalignant lesions were excised using carbon dioxide lasers whereas Kaplan removed benign tumors and superficial oral cancers using argon lasers <sup>[1]</sup>.

A laser is a monochromatic, collimated, coherent, and intense beam of light produced by the stimulated emission of radiation from a light source. Lasers are classified based on active mediums such as gas, liquid, solid, and semi-conductor, which identifies the type of emitted laser beam. Visible beams (Argon laser) and invisible beams [CO<sub>2</sub> (Carbon Dioxide Laser), Ho:YAG (Holmium Yttrium Aluminium Garnet), Er: YAG (Erbium substituted: Yttrium Aluminium Garnet), Er-Cr: YSGG (Erbium, Chromium Doped Yttrium Scandium Gallium Garnet), ND: YAG (Neodymium-Doped Yttrium Aluminium Garnet), Diode (Gallium Arsenide) (GaAs)] are used in dentistry <sup>[2]</sup>.

Low-level laser therapy (LLLT) has therapeutic effects without inducing heat because of its anti-inflammatory, biostimulant, and regenerative effects. The laser can be used in a continuous or pulsed mode through contact or noncontact application on tissues. Based on the diode laser photothermal effect, the oral mucosal lesions are removed with an excision technique, or by ablation/vaporization procedures <sup>[3]</sup>.

This article provides insight into the uses of lasers in Oral & Maxillofacial surgical procedures.

## DISCUSSION:

The first LASER, MASER (Microwave Amplification by Stimulated Emission of Radiation) was introduced by Theodore H. Maiman in 1960. Second LASER was Neodymium LASER (Snitzer,1961).Carbon Dioxide LASER was introduced by Lobene & Fing, in 1966 <sup>[4]</sup>. Components of a laser include an active medium, an external energy source, and an optical resonator (Figure 1)

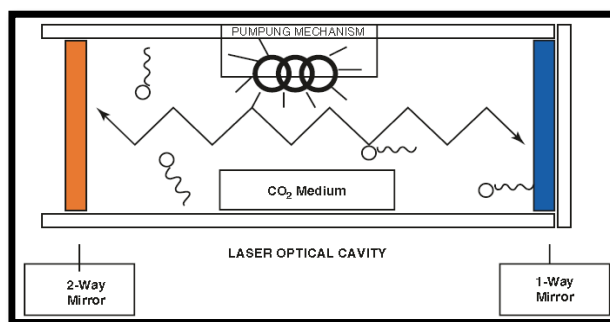


Figure 1: Components of laser

## Classification of lasers <sup>[4]</sup>

On the basis of output energy:

- Low output, soft or therapeutic eg. Low output diodes
- High output, hard, or surgical eg.CO<sub>2</sub>, Nd:YAG,Er:YAG

On basis of the state of gain medium:

- Solid state eg.Nd:YAG, Er:YAG, Er,Cr:YAG
- Gaseous eg. HeNe, Argon,CO<sub>2</sub>
- Excimer eg. ArF, KrCl
- Diode eg. GaAIAs

On the basis of oscillation mode:

- Continuous wave eg. CO<sub>2</sub>, Diodes
- Pulsed wave eg. Nd: YAG, Er: YAG

## Applications of lasers in oral and maxillofacial surgery

Three categories of application of lasers are as follows <sup>[4]</sup>:

1. Incisional/excisional procedures
2. Vaporization (tissue ablation) procedures
3. Surgical hemostasis

### 1) Removal of oral mucosal lesions

#### Oral leukoplakia

A randomized clinical trial was conducted to compare the pain, swelling, and post-operative complications after leukoplakia excision using a carbon dioxide laser and cold knife and they concluded that carbon dioxide lasers showed minimum pain and swelling compared to cold knife excision.

Photodynamic therapy (PDT) is an advanced laser technology used in the excision of oral leukoplakia which shows no damage to collagenous tissue structures. PDT is economical and shows minimal pain <sup>[5]</sup>.

### *Lichen planus*

In symptomatic patients, diode laser (940nm) shows effective treatment in relieving oral lichen planus. Another study shows carbon dioxide laser was used in excising the lesion which confirms the histopathological diagnosis. Follow-up sessions of the patient for about 1 year resulted in improved oral mucosa [6].

### *Gingival melanin pigmentation*

Simsek et al compared the procedures using diode and Er: YAG laser in treating gingival melanin pigmentation (GMP) regarding effectiveness, post-operative pain, requirement, and time needed for the procedure. Their results showed diode lasers are way more effective in consuming time than Er: YAG [6].

## 2) Oral benign lesions

### *Mucocele*

Mucocele is a lesion involving minor salivary glands commonly seen in the lower lip and buccal mucosa. A study was done to compare the excision of mucosa using a scalpel and carbon dioxide laser. It resulted that carbon dioxide laser showed better results and better wound healing than scalpel excision [7].

### *Ranula*

Ranula is the formation of mucous after trauma to the sublingual gland from the arrest of sublingual ducts. Lai et al reported treating ranula with carbon dioxide laser shows less or no recurrent rate [7].

### *Epulis fissuratum*

Epulis fissuratum is a pseudo tumor commonly seen in patients using ill-fitting dentures. A study reveals that using carbon dioxide lasers in patients under anti-thrombotic therapy shows no postoperative complications [7].

## 3) Frenectomy

The labial frenum is a fold of oral mucosal membrane which extends from the lips to the alveolar gingival mucosa. A study described that the labial frenectomy procedure was done using a conventional surgical technique and Nd: YAG laser. It resulted that Nd: YAG laser showed suture less with minimized trans-operative bleeding and surgical time than conventional surgical technique [4].

## 4) Ankyloglossia (tongue tie)

A study was done to compare Er: YAG and diode lasers in order to review the discomforts in the patients with treating ankyloglossia. It resulted that Er: YAG laser was very efficient than the diode laser because it performs by applying topical anesthesia [4].

## 5) Dental implantology

Carbon dioxide and Er: YAG laser can be used only at low power. Using a laser in the second stage of implant surgery results in minimum trauma and post-operative pain.

A major advantage of using a laser in the second stage of implant surgery is that impression can be made immediately due to its hemostatic effects. Also, tissue shrinkage is less so the margins will remain the same [5].

## 6) Oral cancer

The use of lasers in tumor surgery has advantages like remote application, precise cutting, hemostasis, low cicatrization, reduced postoperative pain, and swelling, and can be combined with endoscopic, microscopic, and robotic surgery.

CO<sub>2</sub> and Er: YAG lasers are mainly absorbed by water, resulting in a minimal penetration depth and fast heating, with effective removal of soft and hard tissue. Nd: YAG lasers are used for the excision of cancer in a focused mode as well as for the removal of precancerous lesions in a defocused mode [8].

## 7) Laser Biostimulation

Biostimulation may be useful for improving healing within the oral cavity Gamaleya 1977. Positive results in the treatment of recurrent aphthous stomatitis with soft lasers Korytny 1978.

High therapeutic efficiency and shortening of disease duration when a mucosal disease such as acute herpetic stomatitis, exudative erythema multiforme, and gingivitis was treated in children with low energy lasers Lutsyl 1981 [9].

## Recent Advances

The Waterlase system is a revolutionary dental device that uses laser-energized water to cut or ablate soft and hard tissue. Periowave, a photodynamic disinfection system utilizes nontoxic dye (photosensitizer) in combination with low-intensity lasers enabling singlet oxygen molecules to destroy bacteria [10].

## Precautions before and during Irradiation [4]

- Use protective glasses for eye protection.
- Prevent inadvertent toxic irradiation.
- Protect the patient's eyes, throat, and oral tissues.
- Use wet gauze packs to avoid shiny metal surface reflection.
- Ensure high-speed evacuation to capture the laser plume.

Laser	Wavelength	Indications
Argon	488 nm, 514 nm	Pigmented lesions, Vascular anomalies, Plastic surgery
Diode	620-900 nm	Periodontal surgery, PDT, Soft laser therapy
CO <sub>2</sub>	10,600 nm	Soft-tissue procedures
Nd: YAG	1,064 nm	Soft-tissue procedures, Periodontal surgery, Pigmented lesions
Ho :YAG	2,100 nm	Arthroscopic surgery, soft tissue surgery
Er,Cr: YSGG	2780 nm	Bone surgery, Periodontal surgery, Cavity preparations
Er: YAG	2944 nm	Bone surgery, Skin resurfacing

**Table 1: Different Types of Lasers used in oral surgery<sup>[4]</sup>**

**Literature**

Study type	Author	Year	Sample size	Laser type	Result
RCT	Lopez-jornet <sup>[11]</sup>	2013	48	CO2 laser	Minimal pain and swelling
RCT	Simsek <sup>[12]</sup>	2012	20	Diode and Er: YAG laser	Satisfactory depigmentation
RCT	Agha-Hosseini <sup>[13]</sup>	2012	57	CO2 laser	Effective in treating Lichen Planus
Case report	Monteiro <sup>[14]</sup>	2012	1	CO2 laser	Gold standard in epulis fissuratum excision
Case report	Asnaashari <sup>[15]</sup>	2013	1	Diode laser	Removal of the whole lesion in one session

**Table 2: Studies reporting the use of lasers in oral surgery****Advantages**

- Hemostatic effect which provides a clear operating field.
- Reduces post-operative swelling and pain.
- Increased surgical procedure accuracy.
- Suture-less procedures.
- Enhance faster wound healing.

**Drawbacks**

- Scattered and reflected laser beams lead to a health hazard.
- Expensive procedure.
- Technique sensitive.

**CONCLUSION:**

The emergence of lasers with different wavelengths and their widespread application in oral lesion management may influence treatment outcomes in patients. Laser technology progress has enabled oral & maxillofacial surgeons to manage untreatable lesions that produced poor results. Because of its less bleeding and less post-operative pain, professionals are giving priority to practicing LASER surgeries. The treatment outcome is based on the different wavelengths and techniques used during the procedure <sup>[4]</sup>. Continuous improvements in laser technology may bring about a revolutionary change in managing oral lesions in the future.

**REFERENCES:**

1. Asnaashari M, Zadsirjan S. Application of Laser in Oral Surgery. *J Lasers Med Sci* 2014;5(3):97-107.
2. Sulewski JG. Historical survey of laser dentistry. *Dent ClinNorth Am* 2000;44(4):717-52.
3. Asnaashari M, Mohebi S, Paymanpour P. Pain reduction using low-level laser irradiation in single-visit endodontic treatment. *J Lasers Med Sci* 2011;2(4):139-43.
4. Lal KA, Parthiban J, Sargunar BA, Prakash CA, Anandh B. Usefulness of Laser in Oral and Maxillofacial Surgery. *Biomedical & Pharmacology Journal*. 2015;8:271-7.
5. Neville B.W, Damm D.D, Allen C.M, Bouquot J. *Oral and Maxillofacial Pathology*:third edition. Pg.390,398-399,388-391,397,406,454
6. Catone GA, Alling CC, *Laser Applications in Oral and maxillofacial surgery*.Pg: 98-111
7. RamanupamTripathy ,SatyabrataPatnaik, ACOFS VOL II ISSUE I F.W. Neukam, F. Stelzle / *Physics Procedia* 5:91–100 (2010).
8. Bello-Silva MS, de Freitas PM, Aranha AC,Lage-Marques JL, Simoes A, de Paula Eduardo C. Low- and high-intensity lasers in the treatment of herpes simplex virus infection. *Photomed Laser Surg*. 28(1):135-9 (2010)
9. Walsh LJ. The current status of low level laser therapy in dentistry. Part 2 Hard tissue applications. *Australian Dent. J.* 1997; 42:5.pgs 302-06.
10. Walsh LJ. The current status of laser applications in dentistry.*Aust Dent J* 48:146-55 (2003).
11. Lopez-Jornet P, Camacho-Alonso F. Comparison of pain and swelling after removal of oral leukoplakia with CO2 laser and cold knife: a randomized clinical trial. *Med Oral Patol Oral Cir Bucal* 2013; 18(1):e38-44.
12. Simsek Kaya G, Yapici Yavuz G, Sumbullu MA, Dayi E. A comparison of diode laser and Er:YAG lasers in the treatment of gingival melanin pigmentation. *Oral Surg Oral Med Oral Pathol Oral Radiol* 2012; 113(3):293-9.
13. Agha-Hosseini F, Moslemi E, Mirzaii-Dizgah I. Comparative evaluation of low-level laser and CO2 laser in treatment of patients with oral lichen planus. *Int J Oral Maxillofac Surg* 2012;41(10):1265-9.
14. Monteiro LS, Mouzinho J, Azevedo A, Camara MI, Martins MA, La Fuente JM. Treatment of epulis fissuratum with carbon dioxide laser in a patient with antithrombotic medication. *Braz Dent J* 2012; 23(1):77-81.
15. Asnaashari M, Azari-Marhabi S, Alirezaei S, Asnaashari N. Clinical Application of 810nm Diode Laser to Remove Gingival Hyperplastic Lesion. *J Lasers Med Sci* 2013; 4(2):96-8.