

# Analysis of the Occipital Condyl

M.Mahamutha Affshana, Dr. Yuvraj.

Saveetha dental collage and hospitals ,ponamallae, Tamilnadu

## Abstract

**Aim:**The aim of the present study is to analyze the occipital condyle morphometrically.

**Objective:**The human occipital condyle is the unique bony structure connecting the cranium and the vertebral column. The progress in neuroimaging techniques has increased interest for aggressive craniovertebral surgery. Such surgery requires the knowledge regarding anatomical aspects of the craniovertebral junction.

**Background:**The occipital condyles are undersurface protuberances of the occipital bone in vertebrates, which function in articulation with the superior facets of the atlas vertebra.The articular surfaces of the condyles are convex from before backward and from side to side, and look downward and lateralward.

**Methods And Materials:**occipital condyles of dry skulls were used for this study. parameters were measured, including length, width and height of occipital condyle, the distances between the occipital condyle and hypoglossal canal, as well as some important condyle-related angles.

**Reason:**the occipital condyle may present various shapes, length, width, and orientation, requiring a careful radiological analysis before craniovertebral junction surgery.

## INTRODUCTION

The occipital condyles are undersurface protuberances of the occipital bone in vertebrates, which function in articulation with the superior facets of the atlas vertebra.

The condyles are oval or reniform (kidney-shaped) in shape, and their anterior extremities, directed forward and medialward, are closer together than their posterior, and encroach on the basilar portion of the bone; the posterior extremities extend back to the level of the middle of the foramen magnum.

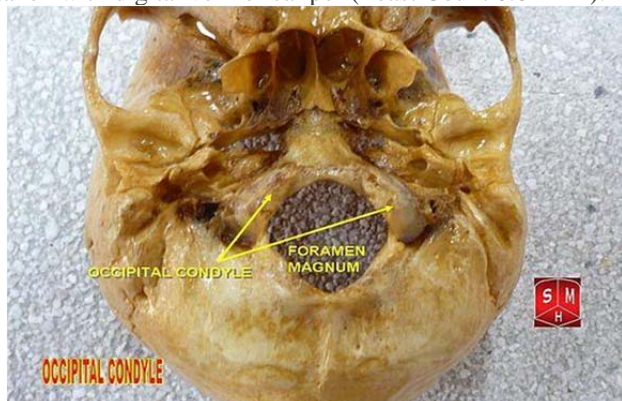
The articular surfaces of the condyles are convex from before backward and from side to side, and look downward and lateralward.

To their margins are attached the capsules of the atlanto-occipital joints, and on the medial side of each is a rough impression or tubercle for the alar ligament.

At the base of either condyle the bone is tunnelled by a short canal, the hypoglossal canal.

## MATERIAL AND METHODS:

The morphometric analysis was performed on 50 dried skulls 50 occipital bones of South Indian subjects The study was conducted in Saveetha dental collage and hospital,ponnamalle,Tamilnadu.All the measurements taken with digital vernier caliper (Least Count 0.01 mm).



## THE METRIC STUDY

It includes 6 parameters as length,width,height and distances related to occipital condyl(table 1). The measures for each parameters was performed by two reserchers and mean was taken to minimise. The height was measured at the center of the condyl which is present at the midpoint of the largest anteroposterior axis of the occipital condyl.

## RESULTS:

The results obtained from the present study are shown in Table 2. The mean length, width and height of the measured occipital condyle were found to be 23.5 mm (right) and 23.75 mm (left) for the length, 13.58 mm (right) and 13.62 mm (left) for the width and 9.64 mm (right) and 9.5 mm (left) for the height. The mean anterior and posterior intercondylar distances were found to be 20.64 mm and 41.4 mm respectively.

**Table (1):**

| Measured parameters |  |
|---------------------|--|
| 1-                  | The length of occipital condyle (right and left)   |
| 2-                  | The width of occipital condyle (right and left)  |
| 3-                  | The height of occipital condyle (right and left)   |
| 4-                  | Anterior intercondylar distance (distance between the anterior tips of the right and left occipital condyles)              |
| 5-                  | Posterior intercondylar distance (distance between the posterior tips of the right and left occipital condyles)            |
| 6-                  | Distances between the anterior tips of the occipital condyles (right and left) and the anterior midline of foramen magnum. |

Table 2:

| Measured parameters              | Side | Mean (mm) | S.D  | Range       | T. test |
|----------------------------------|------|-----------|------|-------------|---------|
| Length of O.C                    | Rt   | 23.5      | 2.53 | 18 – 31     | 0.49    |
|                                  | Lt   | 23.75     | 2.50 | 18.3 - 29.4 |         |
| Width of O.C                     | Rt   | 13.58     | 1.82 | 9.5 – 18    | 0.11    |
|                                  | Lt   | 13.62     | 1.71 | 10.2 - 16.8 |         |
| Height of O.C                    | Rt   | 9.64      | 1.41 | 6 – 14      | 0.44    |
|                                  | Lt   | 9.5       | 1.71 | 6 – 13      |         |
| Anterior intercondylar distance  |      | 20.64     | 2.86 | 11.5 - 25.5 |         |
| Posterior intercondylar distance |      | 41.4      | 3.48 | 35.5 - 48.5 |         |

**DISCUSSION:**

The occipital condyle width was found to range from 9.5 to 18 mm and the mean is 13.58 mm in right and 13.62 in left. This measured width is comparable with the results obtained by Kizilkanat<sup>17</sup> who reported the width as 13.1 mm, but away from the results obtained by Muthukumar et al<sup>16</sup> and Naderi et al<sup>9</sup> who reported the width as 14.72 mm and 10.6 mm respectively. The height of the occipital condyle was found to range from 6 to 14 mm and the mean is 9.6 mm in right and 9.5 mm in left. This measured height is approximate to the result obtained by Naderi et al<sup>9</sup> who reported the height as 9.2 mm and more than the result obtained by Oliver<sup>5</sup> who reported the height as 8.8 mm. The occipital condyles were found to converge ventrally. The anterior and posterior intercondylar distances were found to be 20.64 and 41.4 mm respectively. These measured distances are comparable to the results obtained by Naderi et al<sup>9</sup> who reported these distances as 21 and 41.6 mm respectively and away from the results obtained by Kizilkanat<sup>17</sup> who reported them as 22.6 and 44.2 mm respectively. This wide difference between the anterior and posterior intercondylar distances leads the occipital condyle to have different anterior and posterior angles. The anteroposterior orientation and narrow intercondylar space would require a more bony removal.<sup>15</sup>

**CONCLUSION:**

The extent of bony resection of the occipital condyle can be anticipated by the available recent radiological techniques by using the mentioned morphometric parameters.

**REFERENCES:**

- Williams PL, Bennister LH, Berry MM, Collins P, Dyson M, Dussek JE and Ferguson MWJ: "Gray's anatomy" 38th ed., Churchill Livingstone. New York, Edinburgh and London, 1995, pp. 371-373.
- Al-Mefty O, Borba LA, Aoki N, Angtuaco E and Pait TG: The transcondylar approach to extradural non-neoplastic lesions of the craniovertebral junction. *J Neurosurg* 1996; 84: 1-6.
- Vishteh AG, Grawford NR, Melton S, Ferguson KL, Geldmacher TR, Dickman CA, Sonntag VKH, Spetzler RF: Stability of the craniovertebral junction after unilateral occipital condyle resection: Abiomechanical study (Abstract). *Neurosurg* 1998; 43: 675.
- Corruccini RS: An examination of the meaning of cranial discrete traits for human skeletal biological studies. *Am J Phys Anthropol* 1974; 40: 425-446.
- Oliver G: Biometry of the human occipital bone. *J Anat* 1975; 120: 507-518.
- Guidotti A: Morphometrical consideration on occipital condyles. *Anthropol. Anz* 1984; 42: 117-119.
- Bestianini A, Guidotti A, Hauser G and Destefano GF: Variations in the method of the division of the hypoglossal canal in sienese skulls of known age and sex. *Acta Anat* 1985; 123: 21-24.
- Wen HT, Rhoton AL, Katsuta T and de Oliveira E: Micro-surgical anatomy of the transcondylar, supracondylar and paracondylar extension of the far-lateral approach. *J Neurosurg* 1997; 87: 555-585.
- Naderi S, Korman F, Citak G, Guvencer M, Arman C, Senoglu M, Tetik, S and Arda MN: Morphometric analysis of human occipital condyle. *Clin Neurol Neurosurg* 2005; 107(3): 191-199.
- Salas E, Sekhar CN, Ziyal I, Caputy AJ and Wright DC: Variations of the extreme lateral craniocervical approach: Anatomical study and clinical analysis of 69 patients. *J Neurosurg (spine 2)* 1999; 90: 206-209.
- Heros RC: Lateral suboccipital approach for vertebral and vertebrobasilar artery lesions. *J Neurosurg* 1986; 64: 559-562.
- George B, De-Matons C and Cophignon J: Lateral approach to the anterior portion of the foramen magnum. *Surg Neurol* 1988; 29: 484-490.
- Bertalanffy H and Seeger W: The dorsolateral, suboccipital, transcondylar approach to the lower clivus and anterior portion of the craniocervical junction. *Neurosurg* 1991; 29: 815-821.
- Tedeschi H and Rhoton ALJR: Lateral approaches to the petroclival region. *Surg Neurol* 1994; 41: 180-216.
- Dowd GC, Zeiller S and Awasthi D: Far- lateral transcondylar approach: Dimensional anatomy. *Neurosurg* 1991; 45: 95-99.
- Muthukumar N, Swaminathan R, Venkatesh G and Bhanumathy SP: A morphometric analysis of the foramen magnum region as it relates to the transcondylar approach. *Acta Neurochirurgica* 2005; 147(8): 889-895.
- Kizilkanat E: Morphometry of the hypoglossal canal, occipital condyle and foramen magnum. *Neurosurgery Quarterly* 2006; 16(3): 121-125.
- Bozbuga M, Oztürk A, Bayraktar B, Ari Z, Sahinoglu K and Polat G: Surgical anatomy and morphometric analysis of the occipital condyles and foramen magnum