

Delayed Onset -Sensorineural Hearing Loss Following Trauma

Dr. S.Murugesan¹, Dr. Shanti², Dr.Fathima³

¹Professor and HOD, Department of otorhinolaryngology,
SreeBalaji Medical College and Hospital

²Senior Resident, Department of otorhinolaryngology,
SreeBalaji Medical College and Hospital

³Junior resident, Department of otorhinolaryngology,
SreeBalaji Medical College and Hospital

Abstract

Hearing loss is common after head trauma. Head injury may cause Temporal bone fracture, concussion injury, disruption of intralabyrinthine fluids. In many cases of sensorineural hearing loss, cause is not found.

We are reporting a case of delayed onset sensorineural hearing loss in a child with trauma to occipital region 2 weeks back. We performed all investigations but cause could not be found. We treated the patient with oral, intravenous and intra tympanic steroids. Patient's hearing improved significantly and is on regular follow up.

Key words: sensorineural hearing loss, intravenous steroids, intratympanic steroids.

INTRODUCTION

Sensorineural hearing loss is the hearing loss caused by damage to the inner ear or the acoustic nerve. It attributed to many causes like trauma, presbycusis (age related), noise induced damage, ototoxic drugs, meniere's disease, hereditary disease and viral infections.

Transverse temporal bone fractures are more commonly associated with inner ear involvement and sensorineural hearing loss. Trauma may cause round window or oval window membrane rupture causing perilymph leak and sensorineural hearing loss. Labyrinthine concussion can cause cochlear hearing loss.

Prompt evaluation of patient, early diagnosis and early treatment improves the prognosis. The main aim in treating the cases of sensorineural hearing loss is not only to find the cause but to revert the pathological lesions at the earliest as most cases are due to oedema and are reversible. Blunt injuries cause concussion and oedema of cochlea causing sensorineural hearing loss. In our case, we could not find the etiology and pathogenesis for the delayed onset (2 weeks after trauma) but patient recovered completely with oral, intravenous and intratympanic steroids.

DISCUSSION

Hearing loss after head trauma is well-known phenomenon¹. In 1939 Grove² reported an incidence of 32.6% of sensorineural hearing loss and suggested that bleeding in the inner ear was the cause whereas Uffenorde³ stated that stretching of the fibers of the cochlear nerve in the internal auditory canal brought on the hearing loss after head injury. Similar results were reported by Gurdijan⁴, Fradis and Podoshi⁵ and M R Abd al Hady⁶ Griffiths.

According to Schuknecht and Davison⁷, auditory symptoms following head injury can be grouped according to the classification of labyrinthine damages which are: (a). Longitudinal fracture of temporal bone (b). Transverse fracture of temporal bone (c). Labyrinthine concussion. Labyrinthine concussion may be described as perceptive deafness and vertigo resulting from a blow to the head without fracture of bony labyrinth capsule. The underlying pathology was thought to be due to injury to the utricle and saccule. It is speculated that high-pressure waves caused by a blow to the head is directly transmitted to the cochlea by bone conduction⁸. The diagnosis of labyrinthine concussion mainly relies on audiometric tests⁸. There is no specific treatment for labyrinthine concussion⁸.

Evaluation usually begins with a careful history regarding onset, duration, associated symptoms, vestibular involvement, trauma, ototoxic medication. Examination of ear, pure tone audiometry, Impedance audiometry is done. In patients having history of trauma, CT scan is done to rule out temporal bone fractures. Anatomic defects such as a Mondini dysplasia or enlarged vestibular aqueduct may be seen which can account for a sudden hearing loss.

Treatment can be based upon etiology. If no definitive or treatable etiology is found, treatment is done as in Idiopathic sudden sensorineural hearing loss.

Oral corticosteroid therapy is among the few treatment modalities that have gained acceptance and proved to be effective in selected studies and most importantly when compared to placebo in 2 randomized controlled trials^[9]. Corticosteroids are anti-inflammatory agents. The mechanism of action presumed to be the reduction of cochlear and auditory nerve inflammation.^[10] Corticosteroids modify the body's immune response to

diverse stimuli and decrease inflammation by reversing increased capillary permeability and suppressing PMN activity.

In a randomized controlled study, intratympanic injection of dexamethasone is shown to effectively improve hearing in patients with severe or profound ISSNHL after treatment failure with standard therapy and is not associated with major side effects.^[11] Similar results were reported in yet another recent study.^[12] When used intratympanically, the concentration of the drug at its site of action (inner ear) will be higher and its side effects will be minimized.

A prospective study by Battaglia et al indicated that a greater percentage of patients with ISSNHL recover following combination therapy with high-dose prednisone taper (HDPT) and intratympanic dexamethasone (IT-Dex) than do those treated with HDPT alone. It was also found that the likelihood of hearing recovery was higher when combination therapy was administered within 7 days of the onset of ISSNHL.^[13]

Clinically, the success rate of Intratympanic steroid therapy in patients with SHL is variable in the literature and the available studies are limited to retrospective and non-controlled prospective ones. Randomized controlled trials are needed to better establish the effectiveness of Intratympanic steroid therapy in the treatment of patients with SHL.

CASE REPORT

A 10 year boy presented in our outpatient department with history of trauma in right occipital region 2 weeks back and Right ear blocking sensation since 1 day. The boy was travelling in bus for school when due to sudden brake, he hit the iron rod of window. The blow was at right occipital region. No history of altered sensorium, loss of consciousness, vomiting, facial weakness, CSF leak, ear bleed, tinnitus or giddiness. On reaching school, he was given pain killers and advised rest. No other active management was done. 1 day before presenting to us, he had right ear blocking sensation. Patient also gave history of self-cleaning 1 day back.

On examination, patient was conscious, oriented, of average built and nutrition. His pinna, preauricular, postauricular region was normal. Right External auditory canal showed blood clot in posterior wall with congestion of surrounding area probably due to self-inflicted injury. Tympanic membrane was normal. Rest of the examination was normal. Tuning fork test was done which showed Rinne's test positive in both ears. Weber's test was lateralized to left ear and Absolute bone conduction was reduced in right ear. Facial nerve examination, vestibular function and Cranial nerve examination were normal.

Pure tone audiometry was done. It revealed 72 db sensorineural hearing loss in Right ear (in 500Hz, 1000Hz, 2000 Hz, 4000Hz and 8000Hz) with a downsloping curve. Left ear showed hearing within normal limits.

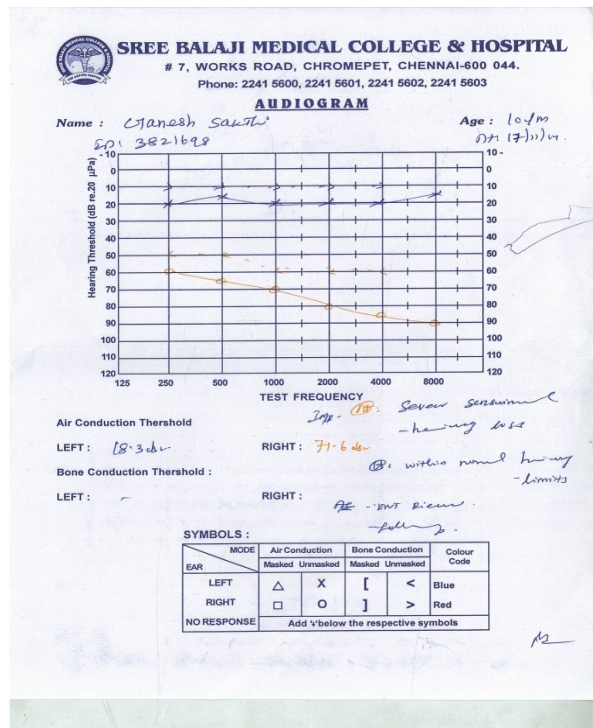


Figure 1: Pure tone audiometry on the day of presentation, showing right ear severe sensorineural hearing loss.

Impedence audiometry showed normal curve and acoustic reflex present on both sides.

Patient was admitted in ENT ward. CT scan of both temporal bones was done to rule out temporal bone fracture. MRI brain was done following a neurological opinion. Both were normal. All blood parameters were within normal limits.

We started him on intravenous Steroids – Inj Solumedrol (methyl prednisolone) 40mg in 50 ml normal saline given as slow i.v infusion over half an hour, thrice a day for 2 days followed by intratympanic steroids along with oral steroids.

On Day 1, Intratympanic steroids – Inj. Dexamethasone (24mg/ml) was injected in postero-inferior quadrant of right tympanic membrane under endoscopic vision. Only 0.4ml could be injected as it filled the middle ear. The child was placed in supine position for next 30 minutes. Similar injections were repeated every 4th day. 5 intra tympanic injections were given in 2 weeks. Oral steroids (prednisolone- 1mg/kg) was given for 2 weeks. Patient had symptomatic improvement on 2nd day and patient was discharged on 3rd day. The intratympanic injections were given as OPD procedure.

After 3 weeks, PTA was done. PTA showed remarkable improvement in hearing with hearing within normal range in both ears. Tuning fork tests confirmed the result with weber's test centralized and Absolute bone conduction was same as examiner.

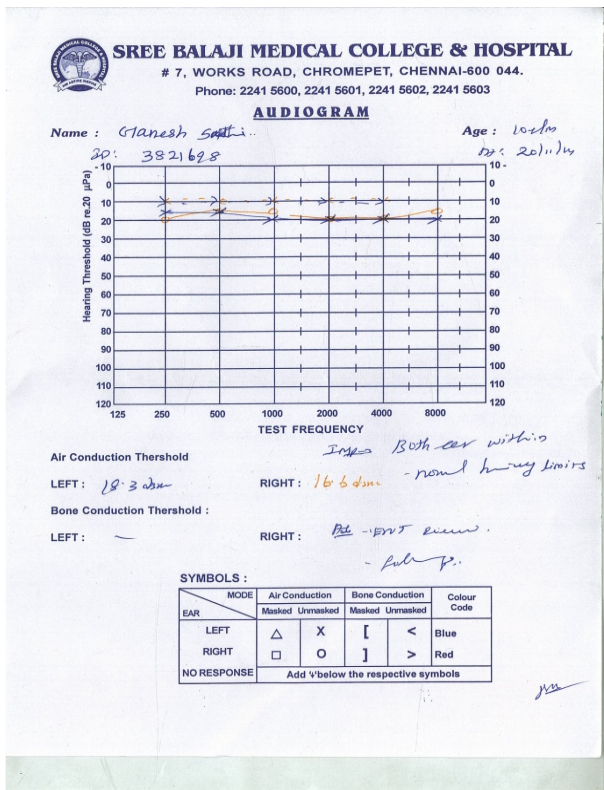


Figure 2: Pure tone audiometry after 3 weeks, showing hearing within normal limits.

CONCLUSION

Our patient did not presented with hearing loss or any other symptom of inner ear involvement like giddiness or tinnitus. Etiopathogenesis of sensorineural hearing loss in our case is still unclear as we could not locate any etiology though patient gave history of trauma. The most probable cause in our case is concussion and oedema of inner ear mainly cochlea. Further it also emphasizes the importance of thorough clinical examination including tuning fork tests in all cases of trauma as the patient presented only with blocking sensation in right earbut was diagnosed on the basis of history, tuning fork test and pure tone audiometry. Treatment with oral, intravenous and intratympanic steroids reverted his hearing back to normal and the patient is on follow up till now. Since this is a single case report, we will have to wait for further research in this area.

REFERENCES

1. Segal S, Eviatar E, Berenholz L, Kessler A, Shlamkovitch N. Dynamics of sensorineural hearing loss after head trauma. *OtolNeurotol* 2002; 23: 312-5.
2. Grove W.E, Skull fractures involving the ear. *Laryngoscope* 1939; 69: 833-870.
3. Uffenorde W: Histologishe Befunde. *Beiter Z AnatphysiolPatholTherapOhrens* 1924; 21: 282-285
4. Gurdjian ES: Studies on Acute cranial and intracranial injuries. *AnnSurg* 1933 : 327-367.
5. Podoshin L., Fradis M: Hearing loss after Head Injury. *Archotolaryngol* 1975; 101: 15- 18
6. M.R.Abd AL-HADY .O Shehata et al. *The Journal of Laryngology and Otology* Vol 104 December 1990: 927-936
7. Harold F.Schuknecht and Roderick C.Davison,, Deafness and Vertigo from Head Injury, *AMA Archives of Otolaryngology* 1956: 513-528
8. Ulug T, Ulubil SA. Contralateral labyrinthine concussion in temporal bone fractures. *J Otolaryngol* 2006; 35: 380-3.
9. Wilson WR, Byl FM, Laird N. 1980. The efficacy of steroids in the treatment of idiopathic sudden hearing loss. A double-blind clinical study. *Arch Otolaryngol* 106: 772-6
10. Wei BP, Muribu S, O'Leary S. Steroids for idiopathic sudden sensorineural hearing loss. *Cochrane Database Syst Rev.* Jan 25 2006; CD003998.
11. Ho HG, Lin HC, Shu MT, Yang CC, Tsai HT. Effectiveness of intratympanic dexamethasone injection in sudden deafness patients as salvage treatment. *Laryngoscope.* Jul 2004; 114(7): 1184-9.
12. Gouveris H, Selivanova O, Mann W. Intratympanic dexamethasone with hyaluronic acid in the treatment of idiopathic sudden sensorineural hearing loss after failure of intravenous steroid and vasoactive therapy. *EurArchOtolaryngol.* Feb 2005; 262(2): 131-4.
13. Rauch SD, Halpin CF, Antonelli PJ, Babu S, Carey JP, et al. 2011. Oral vs intratympanic corticosteroid therapy for idiopathic sudden sensorineural hearing loss: a randomized trial. *JAMA : the journal of the American Medical Association* 305: 2071-9
14. Battaglia A, Burchette R, Cueva R. 2008. Combination therapy (intratympanic dexamethasone + high-dose prednisone taper) for the treatment of idiopathic sudden sensorineural hearing loss. *Otology & neurotology : official publication of the American Otological Society, American Neurotology Society [and] European Academy of Otolology and Neurotology* 29: 453-60