

# Calcorrugoscopy-Oral Fingerprinting-A Study

Prema Sivakumar<sup>1</sup>, Dr. Gheena Sukumaran<sup>2</sup>,

<sup>2</sup>Reader, Department of Oral Pathology,

<sup>1,2</sup>Saveetha Dental College, Poonnamallee bypass road, Chennai -600056

## Abstract:

A descriptive, hospital based study of dental diagnostic casts was conducted to evaluate the prevalence of different palatal rugae patterns in South Indian population. This study was conducted with a sample size of 61 casts, so that a statistical analysis of the of most predominant rugae patterns, lengths, any variant between male and female population can be delineated. The palatal vault height and the canine to canine length of the respective casts were also measured and correlated to the rugae pattern and direction. Palatoscopy has been a recent development in forensic odontology. Each person has a unique pattern of rugae that may just undergo an increase with length with age, owing to the underlying developing palate.

**Keywords:** Forensics, Palatal Rugoscopy, Palatoscopy, Rugae.

## INTRODUCTION:

Calcorrugoscopy is the macroscopic analysis of the rugae patterns present on patient casts made of dental stone. Palatal rugae( fig. 1) are transverse folds of mucosa present over the palate, which is recorded in maxillary arch impression, and can be viewed in the maxillary cast fabrication. These are formed from the lateral membrane of the incisive papilla in the 3<sup>rd</sup> month of intra-uterine life, and are found in the anterior third of the hard palate, and are placed transversely on either side of the mid-palatine raphe, in the mid-sagittal plane[1].It was described first by Winslow in 1753[2] and then by Allen in 1889[3], and the latter emphasized its use as a method of identification for an individual. Like how or fingerprints are unique, the rugae are also unique and may increase in length but will be oriented in the same way throughout the lifetime of a person[4]. It also aids in enhancing taste reception on the dorsum of the tongue and in swallowing[5]. Rugoscopy is an important area of study that is of relevance in anthropology, comparative anatomy, genetics, forensic odontology, prosthodontics and orthodontics [10].This method is effective because, it can be employed in cases where:

- A person is edentulous and can't be identified with the aid of teeth[8] or
- In cases of trauma or incineration(no fingers), when other tissues get damaged, the rugae will remain protected by the surrounding structures(insulated by tongue and buccal pad of fat) due to their internal location[6,7].
- It can be used at times of disasters, for identification of the victims[9].
- For a reliable ante-mortem identification because of its uniqueness, stability and post mortem resistance.

## MATERIALS AND METHODS:

The patient diagnostic casts were collected from the out-patient clinics of Saveetha Dental College, Chennai(Fig. 3). The exclusion criteria was damaged casts, and casts on which rugae patterns were not visible i.e, without any discrepancies or voids in the anterior 2/3rds. The casts were assessed and measured using a digital verniercaliper calibrated to 0.0 mm(fig 4), and the measurements taken down on to a proforma designed for this research which

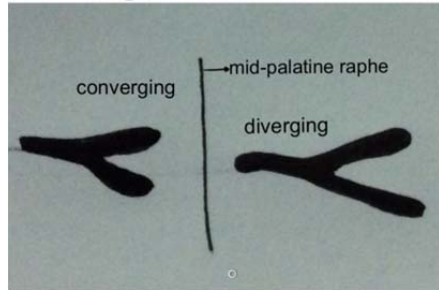
consisted of tabular columns for recording observations. The different observations so made were:

- Sex of person,
- on the right and left sides separately,
  - The number of rugae,
  - The lengths of rugae(only primary and secondary) were measured where: Primary- > 5mm,Secondary- 3-5mm, Fragmentary-less than 3mm.
  - Unification, where there is a bifurcation or a trifurcation, whether it is of a converging or diverging type(while measuring the length, the longest distance was noted).(fig. 2)
  - The predominant shapes of the rugae were sorted according to Thomas and Kotze classification[11], as linear, circular, wavy and curved.(fig. 2)
- The predominant direction(with respect to angle with perpendicular to the mid palatine raphe) was determined: Forward(positive angle), backward(negative angle) and Straight(zero degree angle).(fig 2.)
- The Palatal Vault height was measured ( from the deepest point on the palate until the palatal side of cervical line of the molar), and it was split into three types:
  - Type 1-shallow: 0-5 mm.
  - Type 2-medium: 6-10 mm.[16]
  - Type 3-high: above 10 mm.
- Intercanine distance was measured from the deepest point in the cervical line of a canine palatally, and was categorised into 4 groups: 10-15mm, 15-20 mm, 20-25mm, above 25mm.

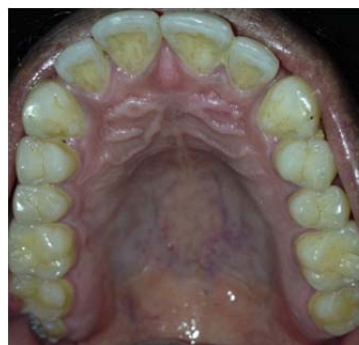


Fig 1- Palatal Rugae

### Unification

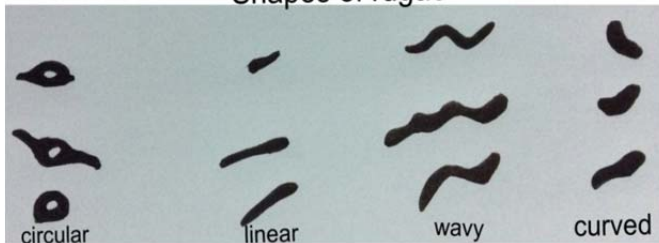


(a)



(b)

### Shapes of rugae



(c)

Fig.2 depicting: Unification Direction (a), direction (b) shapes of rugae(c).




Fig 3. Some of the casts used in the research.




Fig 4. The rugae highlighted on the cast and measured using digital caliper.

### RESULTS:

#### Predominant shape:

The most predominant shape was found to be curved(40.98%), followed by wavy(37.70%), followed by straight(21.31%).In both the sides, males had more curved rugae and females had more wavy rugae.(Fig 5, 6, 7 and Table 1)

Table 1: Predominant shape

Shape	Total	Males	Females
T-Curved	25	14	11
T-Linear	13	8	5
T-Wavy	23	11	12
Right	Total	Males	Females
R-Curved	23	12	11
R-Linear	13	9	4
R-Wavy	25	12	13
Left	Total	Males	Females
L-Curved	26	15	11
L-Linear	15	10	5
L-Wavy	20	8	12

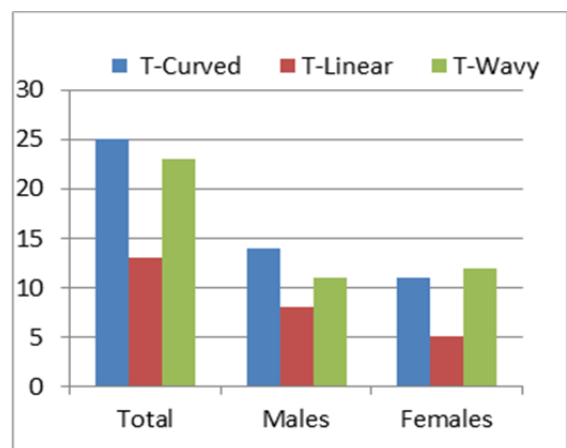


Fig 5. Overall predominant shape.

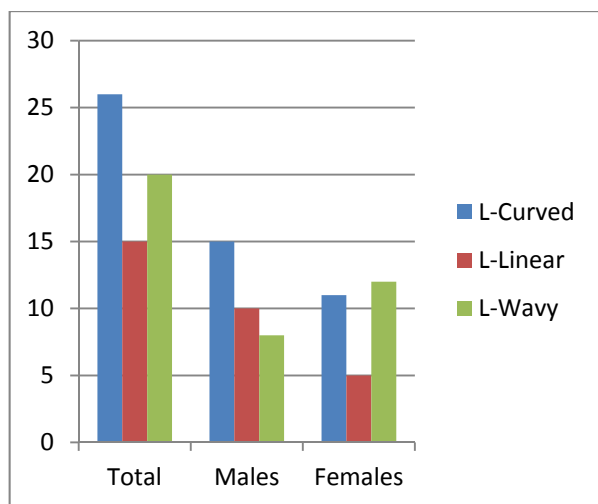


Fig 6. Predominant shape in the left side

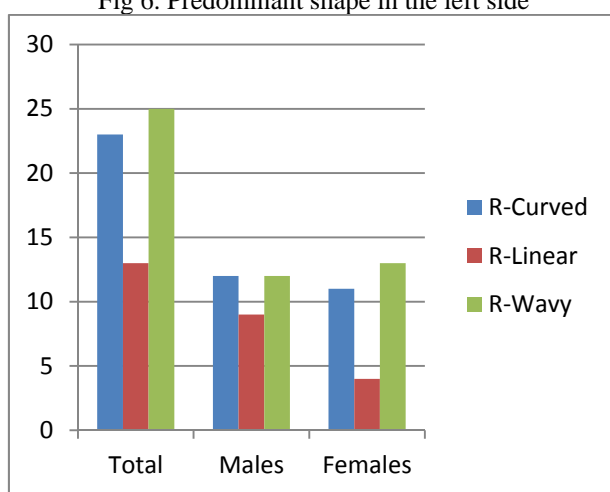


Fig 7. Predominant shape in the right side.

**Predominant direction:**

The most predominant direction was forward, and was more prevalent in men. In the right side, Forward was prominent in men, straight in men and backward in women. In the left side Forward was prominent in women, backward in men, and straight in men. (Table 2, Fig 8)

Table 2: Predominant shape

Direction	Total	Males	Females
T-Forward	36	20	16
T-backward	10	6	4
T-straight	15	7	8
R-Forward	25	14	11
R-backward	17	8	9
R-Forward & backward	4	2	2
R-straight	15	9	6
L-Forward	34	16	18
L-backward	11	8	3
L-Forward & backward	2		2
L-Forward & straight	3	1	2
L-straight	11	8	3

\*T-total, R-Right, L-Left

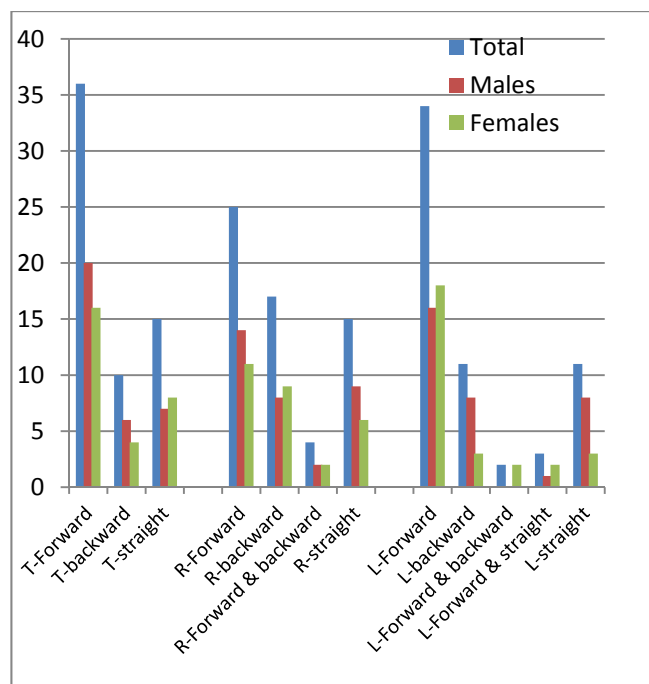


Fig 8. Predominant Direction

**Total number of rugae:**

Females had more number of rugae when compared to males both on the right(6.286-F, 6.152-M) and the left side(6.071-F, 5.848-M).(refer Fig 9, and Tables 3,4 and 5)

Table 3: Total number of rugae

Side	Male	Female
Right	203	176
Left	193	170
Right - Mean	6.152	6.286
Left- Mean	5.848	6.071

Table 4: Distribution of Primary, Secondary and Fragmentary Rugae among samples(Right Side)

Classification	Total number of Rugae			Number of samples		
	Total	Female	Male	Total	Female	Male
Primary	230	126	104	61	28	33
Secondary	50	29	21	33	19	14
Fragmentary	62	21	41	30	13	17

Table 5: Distribution of Primary, Secondary and Fragmentary Rugae among samples(Left Side)

Classification	Total number of Rugae			Number of samples		
	Total	Female	Male	Total	Female	Male
Primary	276	127	149	61	28	33
Secondary	48	27	21	33	19	14
Fragmentary	40	16	24	22	10	12

Table 6: Mean lengths of primary rugae (in mm)

Side	Gender	P-1	P-2	P-3	P-4	P-5	P-6	P-7	P-8
Right	Male	9.15	9.72	10.09	9.81	10.05	10.97	9.87	
	Female	9.33	9.95	9.91	9.64	11.21	10.56	-	
Left	Male	10.13	10.39	10.77	10.88	8.14	8.53	14.9	12.3
	Female	9.55	9.11	10.75	9.65	9.52	10.97	17.95	

\*P-Primary

Table 7: Mean lengths of secondary rugae.

Side	Gender	S1	S2	S3
Right	Male	4.17	3.83	4.01
	Female	4.23	4.06	3.41
Left	Male	4.02	4.54	4.56
	Female	4.12	3.76	3.54

\*s-secondary

Table 8: Average of Mean lengths of primary and secondary rugae.

Particulars	Male	Female
Primary-Right	9.95	10.1
Primary left	10.75	11.07
Secondary-Right	4	3.9
Secondary-Left	3.95	3.81

Palatal vault	Type	Total	Male	Female	Shape	Direction
0-5	Shallow	0	-	-	-	-
6-10	Medium	2	1	1	Curved	forward 1,backward 1
Above 10	High	59	32	27	curved 23,wavy 23,linear 13	forward 35,straight 15,backward 9

Table 9: Palatal vault heights correlated with shape and direction.

Table 10: Inter-canine Distance correlated with shape and direction.

ICD (in mm)	Male	Female	Remarks
10-15	1	-	wavy & forward
5-20	-	1	Linear & straight
20-25	17	17	PD backward 4, forward 23 ,straight 7 & curved 11 ,linear8 , wavy 15
above 25	15	10	PD backward6 , forward 12, straight 7 & curved 14,linear 4, wavy 7

Table 11: Unification- Right

Unification	No.of unifications	No.of samples with unification			Average
		Total	Male	Female	
Converging	25	19	12	7	31%
Diverging	13	10	6	4	16%

(Average: No.of samples with unification/ Total number of samples)

Table 12:Unification- Left

Unification	No.of unifications	No.of samples with unification			Average
		Total	Male	Female	
Converging	15	15	6	9	25%
Diverging	56	43	20	23	92%

(Average: No. of samples with unification/ Total number of samples)

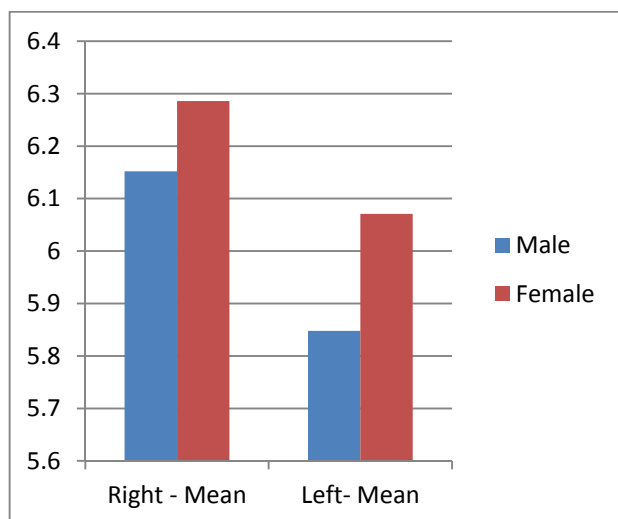


Fig 9. Total no. of rugae

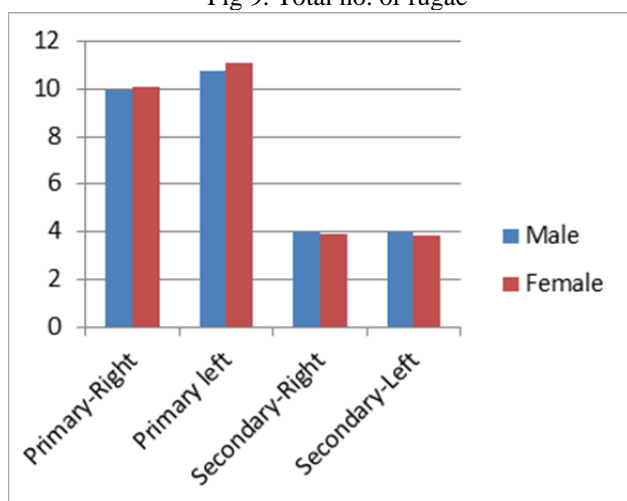


Fig 10. Average of mean lengths of primary and secondary rugae.

**Length of rugae:**

There was not much of a difference in lengths of primary and secondary rugae in males and females.(Fig 10, Tables 6,7 and 8)

**Palatal Vault height:**

There was no sample with shallow type of palatal vault. The medium Vault was seen in common association with Curved, forward and backward rugae. The high type(96.72%) of palatal vault was associated with curved, wavy and forwardly oriented rugae.(Table 9)

**Inter canine distance:**

A majority of the samples came under the 20-25mm category(55.73%) majorly associated with wavy forwardly directed rugae followed by the above 25 category (40.98%) commonly associated with curved, forwardly directed rugae.(Table 10)

**Unification:**

In the right side, converging pattern was prominent, with males at a majority, and in the right side, Diverging pattern was more prominent, with females at a majority.(Table 11 and 12)

**DISCUSSION:**

The results of the research did co-incide with other studies, such as the one by Kapali et al[13](Australian Dental Journal) as the prevalence of curvy and wavy rugae patterns was more than that of straight and circular patterns. For a major part of the research, the males and females, didn't have a big difference in the mean lengths of their rugae. But on an average the females had more number of rugae. And diverging unification pattern showed a significant prominence on the left side. The general predominance of direction was Forward. Identification of a dead person is a very difficult task, because the corpse undergoes decomposition. Rugae are symmetrical in other animals, unlike humans, where it is asymmetrical. As every coin has another side, this method too has its own pros and cons. Studies have proved that, with time, orientation changes by 28% and pattern changes by 32%. [13]. It becomes numerous and less defined with age[12]. And it is a very well-known fact that prosthetic appliances lead to a loss of palate characteristics. Secondary rugae also decrease with orthodontic treatment [14].Even so, this method of palatal rugoscopy will prove to be a potential method of identification, though this part of forensic odontology is still at its infancy.

**CONCLUSION:**

This study was done to look for variations in the rugae patterns. In this study, the main focus was on the primary and secondary rugae, it would be much better if fragmentary rugae are also included in the evaluation methods, to obtain better results. Though this is a questionable identification technique, it is still viable because the general configuration of rugae never changes and comparison can be done with the individual characteristics[14].Researches have to be conducted in larger sample sizes, encompassing various geographical areas, for better statistically significant results, for which records are a necessity. Private practitioners don't often keep proper records of their patients, so this necessitates the responsibility to maintain proper dental records to help in forensic identification[15].

**REFERENCES:**

- [1] Sivaraj A. Significance of palatal rugae in orthodontics. J Orofac Res 2013;3:202-9.
- [2] Winslow JB. Expositio anatomica structurae corporis humani. Tomi quarti pars second, francofurti et lipsia. 1753;227.
- [3] Allen H. The palatal rugae in man. Proc. Acad. Nat. Sci. 2<sup>nd</sup> ed. Philadelphia; 1889. pp 254-72.
- [4] Hermosilla VV, San Pedro VJ, Cantin LM, Suazo GI, Ruga P. Systematic analysis of its shape and dimensions for use in human identification. Int J Morphol 2009;27:819-25.
- [5] Gandikota C, Venkata YP, Challa P, Juvvadi SR, Mathur A. Comparative study of palatal rugae pattern in class II, division 1 and class I individuals. J Pharm Bioallied Sci 2012;4 Suppl 2:S358-63.
- [6] Paliwal A, Wanjari S, Parwani R. palatal Rugoscopy: Establishing identity. J Forensic Dental Sci 2010;2:27-31.
- [7] Nayak P, Acharya AB, Padmini AT, Kaveri H. Differences in the palatal rugae shape in two populations of India. Arch Oral Biol 2007;52:977-82.
- [8] Caldas, I. M.; Magalhaes, T.; Afonso, A. Establishing identity using cheiloscopy and palatoscopy. Forensic Science International, v. 165, n. 1, p. 1-9, 2007.

- [9] Manjunath S, Bakkannavar SM, Kumar PG, Bhat VJ, Prabhu N, Kamath A, Babu RYP. Palatal rugae patterns among the Indians at Manipal India.
- [10] Kerr DA, Ash MM, Millard HD. Textbook of Oral Diagnosis(6<sup>th</sup> ed), CV Mosby Company, St Louis, Toronto, London 1983.
- [11] Thomas cJ, Kotze TJ. The palatal ruga pattern in six southern human populations, part I:A description of the populations and a method for its investigation. J Dent Assoc S Afr 1983;38:547-53.
- [12] Barbieri AA, Scoralick RA, Marote I, Moraes MEL, Naressi SCM, Daruge E.The palatine rugoscopy as Human identification Method in Patients treated with Palatal Disjunction. Elsevier Editorial System™ for Forensic International Manuscript Draft.
- [13] Kapali S, Townsend G, Richards L, Parish T. Palatal rugae patterns in Australian Aborigines and Caucasians. Australian Dental Journal 1997;42: (2) : 129-33.
- [14] Goncalves AF, Diamantino F, Pestana D, Palmela PC.The medico-legal importance of establishing human identity by palatal rugoscopy:evaluation of the immutability and individuality of palatal rugae under the influence of ante-mortem orthodontic treatment.
- [15] Kamala R, Gupta n, bansal A, Sinha A. Palatal Ruage Pattern as an aid for personal identification:A forensic study. Journal of Indian academy of Oral Medicine and Radiology, July-September2011;23(3):173-178.
- [16] Verma KG, Verma P, Bansal N, Basavaraju S, Sachdeva SK, Khosa R. Correlation of palatal rugoscopy with gender, palatal vault height and ABO Blood groups in three different Indian populations.