

# A Review Article on Melanoma

Prabhat Das, \* Nitin Deshmukh, Narendra Badore, Chetan Ghulaxe, Pankaj Patel

GRY Institute of Pharmacy, Borawan, MP – 451228.

## INTRODUCTION [30,17]

Skin cancer is the most common form of human cancer . The most common warning sign of skin cancer is a change in the appearance of the skin, such as a new growth or a sore that will not heal. The term "skin cancer" refers to three different conditions. From the least to the most dangerous, they are:

### 1) Basal cell carcinoma (or basal cell carcinoma epithelioma): [17]

The most common type of skin cancer, a disease in which the cancer cells resemble the basal cells of the epidermis, the outer layer of the skin.it is also called carcinoma epithelioma.

### 2) Squamous cell carcinoma:-

Cancer that begins in squamous cells -- thin, flat cells that look under the microscope like fish scales. Squamous cells are found in the tissue that forms the surface of the skin, the lining of hollow organs of the body, and the passages of the respiratory and digestive tracts. Squamous cell carcinomas may arise in any of these tissues. The word "squamous" came from the Latin squama meaning "the scale of a fish or serpent."

### 3) Melanoma:-

The two most common forms of skin cancer are basal cell carcinoma and squamous cell carcinoma. Together, these two are also referred to as nonmelanoma skin cancer. Skin cancer is also known as skin neoplasia. Melanoma is generally the most serious form of skin cancer because it tends to spread (metastasize) throughout the body quickly.

## MELANOMA [30, 12]

Melanoma is a malignant tumor of melanocytes. Such cells are found predominantly in skin, but are also found in the bowel and the eye. Melanoma is one of the less common types of skin cancer, but causes the majority (75%) of skin cancer related deaths. Melanocytes are normally present in skin, being responsible for the production of the dark pigment melanin. Despite many years of intensive laboratory and clinical research, early surgical resection of thin tumors still gives the greatest chance of cure. Melanoma is the most serious type of skin cancer. It begins in skin cells called melanocytes.Melanocytes are the cells that make melanin, which gives skin its color. Melanin also protects the deeper layers of the skin from the sun's harmful ultraviolet (UV) rays. [12]

When people spend time in the sunlight, the melanocytes make more melanin and cause the skin to tan. This also happens when skin is exposed to other forms of ultraviolet light (such as in a tanning booth). If the skin receives too much ultraviolet light, the

melanocytes may begin to grow abnormally and become cancerous. This condition is called melanoma.

Around 60,000 new cases of invasive melanoma are diagnosed in the United States each year, more frequently in males and in Caucasians. It is more common in Caucasian populations living in sunny climates than in other groups, or in those who use tanning salons. According to a WHO report about 48,000 melanoma related deaths occur worldwide per year. The treatment includes surgical removal of the tumor, adjuvant treatment, chemo- and immunotherapy, or radiation therapy.

## HISTORY [29,30]

The history of melanoma is described as an evolved situation of events. When dating back to the first time melanoma was found by surgery, the time was the year 1787. During this time, the person that discovered it, John Hunter, did not know what it was specifically. He had never seen anything like it. He quoted it as a cancerous fungous. He took out the tumor and they placed it in the Hunterian Museum which is located in the Royal College of Surgeons in England. Around 1968, they discovered that the tumor showed signs of metastatic melanoma, which is a melanoma that affects the internal organs. Metastatic melanoma tends to show up in the third stage. The lymph nodes get affected and then take over the internal organs usually starting with the liver and lungs. Melanoma was first called a disease by a man named Rene Laennec. The main history of melanoma starts here. In the history of melanoma, there were many lecture made by Rene in Paris around 1804-20. There were also writing and general educations about melanoma. The idea that advanced melanoma was untreatable was first described by Samuel Cooper is 1840. This still holds true today. As the stages increase with melanoma, the less chance of survival the melanoma patient has. [30]

Henry Lancaster also contributed in the history of melanoma as we know it today. He correlated that the sunlight intensity showed a very solid conformation that exposure to sunlight aids in the development of melanoma. The same exposure to tanning beds is just as likely to degrade and mutate skin cells. The degradation of skin cell DNA is directly linked to ultraviolet rays that the sun as well as the tanning bed emits. It is because of this that the melanoma can develop.

As the history of melanoma progresses, they find more ways to treat and remove the spots of cancer that pop up. As of now, there still exists no specific cancer cure for advancement of melanoma. There are many trial tests that are being preformed diligently but no solid evidence can prove effectiveness in each.

**CLASSIFICATION** [15,30]**1) Cutaneous Melanoma:-**

There are four major types of cutaneous melanoma:

**A) Superficial spreading melanoma:-**

Superficial spreading melanoma is the most common form of the disease, responsible for about 70% of cases. It generally originates in a pre-existing mole.

**B) Nodular melanoma:-**

Nodular melanoma is the second most common, responsible for 15 to 30% of cases. Nodular melanomas are more aggressive and usually develop more rapidly than superficial melanomas.

**C) Lentigo maligna:-**

Lentigo melanoma appears as large, flat lesions most commonly found on the faces of light-skinned women over the age of 50. This form of melanoma, responsible for about 4% to 10% of cases, has a lower risk of metastasis than other types.

**D) Acral lentiginous melanoma:-**

Acral lentiginous melanoma occurs on the palms, soles of the feet or beneath the nail beds. They account for only 2% to 8% of melanomas in fair-skinned patients, but up to 60% of melanomas in darker-skinned patients. Acral lentiginous melanomas are extremely aggressive and large, with an average diameter of three centimeters.

**2) Mucosal Melanoma:-**

Mucosal melanomas are rare, making up only about 1% of all diagnosed melanoma cases. This disease occurs in mucosal tissue, which lines body cavities and hollow organs. The most common sites for mucosal melanoma are the head and neck region (including the nasal cavity, mouth and esophagus), as well as the rectum, urinary tract and vagina. Mucosal melanomas can be very hard to detect, and even when diagnosed and treated, the outlook is poor.

**3) Ocular melanoma:-**

Because the eyes contain melanocytes, or pigment-producing cells, they can be susceptible to melanoma. Read more about the two types of ocular melanoma:

**a) Uveal Melanoma:-**

Uveal melanoma is a cancer (melanoma) of the eye involving the iris, ciliary body, or choroid (collectively referred to as the uvea). Tumors arise from the pigment cells (melanocytes) that reside within the uvea giving color to the eye. These melanocytes are distinct from the Retinal pigment epithelium cells underlying the Retina that do not form melanomas.

**b) Conjunctival:-**

Melanoma Malignant melanoma of the conjunctiva presents as a raised, pigmented or nonpigmented lesion that appears in adult life. Conjunctival melanomas may be associated with primary acquired melanosis (75%).

**CAUSES** [16, 18, 20]

Sunlight is the main environmental agent that causes melanoma. However, the exact wavelengths of sunlight that cause melanoma are unknown. Research has shown that people with certain risk factors are more likely than others to develop melanoma. A risk factor is anything that increases a person's chance of developing a disease. Still, many get this disease with no known risk factors.

**The following are established risk factors for melanoma:-****1) Dysplastic moles:-**

Dysplastic moles (nevi) are common, and many people have a few of these abnormal moles. The risk of melanoma is greatest for people who have a large number of dysplastic nevi. The risk is especially high for people with a family history of both dysplastic nevi and melanoma.

**2) Fair skin:-**

Melanoma occurs more frequently in people who have fair skin that burns or freckles easily (these people also usually have red or blond hair and blue eyes) than in people with dark skin. Caucasians get melanoma far more often than do black people, probably because light skin is more easily damaged by the sun.

**3) Personal history of melanoma or other skin cancers:-**

People who have been treated for melanoma have a high risk of a second melanoma. Some people develop more than two melanomas. People who had one or more of the common skin cancers (basal cell carcinoma or squamous cell carcinoma) are at increased risk of melanoma.

**4) Family history of melanoma:-**

Melanoma sometimes runs in families. Having two or more close relatives who have had this disease is a risk factor. About 10 percent of all patients with melanoma have a family member with this disease. When melanoma runs in a family, a doctor should check all family members regularly.

**5) Weakened immune system:-**

People whose immune system is weakened by certain cancers, by drugs given following organ transplantation, or by HIV are at increased risk of developing melanoma.

**6) Severe, blistering sunburns:-**

People who have had at least one severe, blistering sunburn as a child or teenager are at increased risk of melanoma. Because of this, doctors advise that parents protect children's skin from the sun. Such protection may reduce the risk of melanoma later in life. Sunburns in adulthood are also a risk factor for melanoma.

**7) Ultraviolet (UV) radiation:-**

Experts believe that much of the worldwide increase in melanoma is related to an increase in the amount of time people spend in the sun. This disease is also more common in people who live in areas that get large amounts of UV radiation from the sun.

In the United States, for example, melanoma is more common in Texas than in Minnesota, where the sun is not as strong. UV radiation from the sun causes premature aging of the skin and skin damage that can lead to melanoma. Artificial sources of UV radiation, such as sunlamps and tanning booths, also can cause skin damage and increase the risk of melanoma. Doctors encourage people to limit their exposure to natural UV radiation and to avoid artificial sources.

**SIGNS AND SYMPTOMS OF MELANOMA [11,15]**

Often, the first sign of melanoma is a change in the size, shape, color, or feel of an existing mole. Most melanomas have a black or blue-black area. Melanoma also may appear as a new, black, abnormal, or "ugly-looking" mole.

**1) Asymmetry:-**

The shape of one half does not match the other.

**2) Border:-**

The edges are often ragged, notched, blurred, or irregular in outline; the pigment may spread into the surrounding skin.

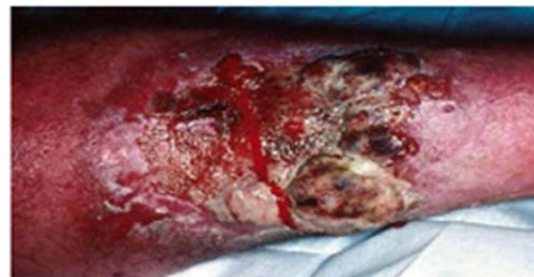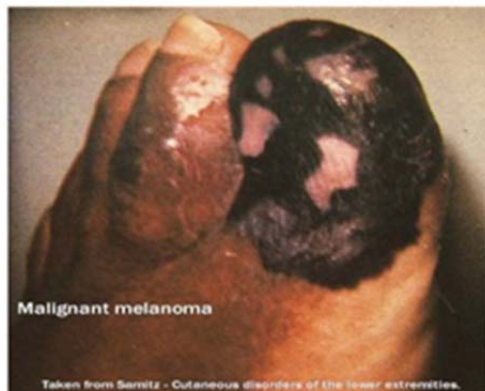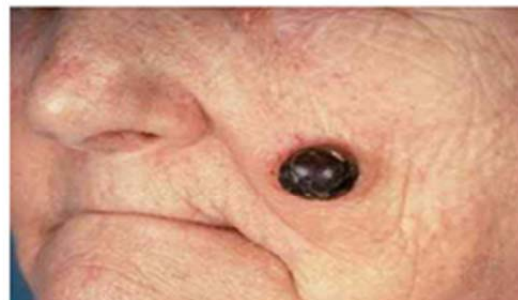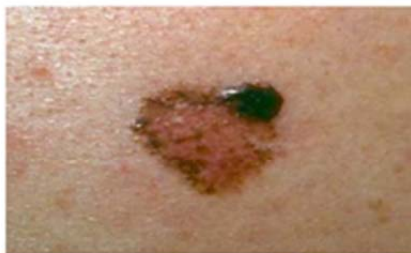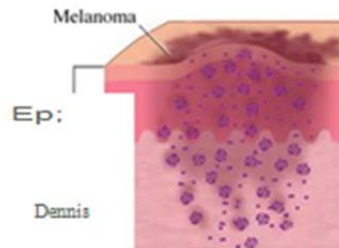
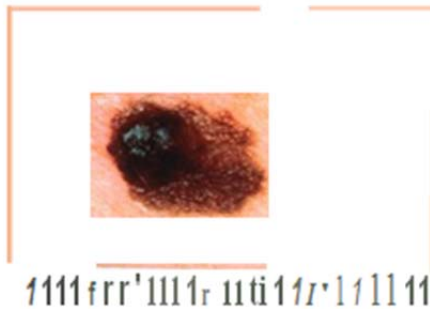
**3) Color:-**

The color is uneven. Shades of black, brown, and tan may be present. Areas of white, gray, red, pink, or blue also may be seen.

**4) Diameter:-**

There is a change in size, usually an increase. Melanomas are usually larger than the eraser of a pencil (5 mm or 1/4 inch).

Melanomas can vary greatly in the ways they look. Many show all of the ABCD features. However, some may show changes or abnormalities in only one or two of the ABCD features. Early melanomas may be found when a pre-existing mole changes slightly--such as forming a new black area. Other frequent findings are newly formed fine scales or itching in a mole. In more advanced melanoma, the texture of the mole may change. For example, it may become hard or lumpy. Although melanomas may feel different and more advanced tumors may itch, ooze, or bleed, melanomas usually do not cause pain.



**DIAGNOSIS** [19,21]

If you notice a mole that looks unusual or that has grown or changed color or shape in the last few months, you should tell your doctor. If your doctor also thinks the mole looks suspicious, he or she will refer you to a dermatologist (a physician who specializes in diseases of the skin). The dermatologist may do a biopsy. The dermatologist will remove a small piece of the mole or the entire mole. A pathologist (another special doctor) then looks at the sample under a microscope to check for cancer cells.

If the mole turns out to be melanoma, your dermatologist will need to find out more about the disease, based on:

- How thick the tumor is
- How far it may have spread

This process is called staging. Staging the melanoma is a very important step because the choice of treatment has a lot to do with the stage of the melanoma.

To find out how thick the melanoma is, the dermatologist or a surgeon will remove the entire tumor along with some skin around it (if this wasn't already done during diagnosis). At the same time, or in a later step, the surgeon may do a procedure called a sentinel lymph node (SLN) biopsy.

This will help your doctor find out whether, and where, the melanoma has spread. Other tests may also play a role in staging. These include:

**1) Blood tests:-**

A new blood test can predict if a deadly skin cancer, malignant melanoma, has metastasized or spread. The test detects the presence of TA-90, a glycoprotein that can stimulate an immune response. In the early stages of disease, TA-90 is found in immune complexes in the blood, and these complexes can be detected using a sophisticated type of assay. This information can be used to predict survival in patients with early-stage melanoma, according to researchers.

**2) chest x-rays:-**

This test may be done to help determine whether melanoma has spread to the lungs.

**3) CT (computed tomography):-**

The CT scan is a type of x-ray test that produces detailed, cross-sectional images of your body. Unlike a regular x-ray, CT scans can show the detail in soft tissues (such as internal organs). This test can help tell if any lymph nodes or organs such as the liver are enlarged, which might be due to the spread of melanoma.

**4) MRI (magnetic resonance imaging):-**

Like CT scans, MRI scans give detailed images of soft tissues in the body. But MRI scans use radio waves and strong magnets instead of x-rays. The energy from the radio waves is absorbed by the body and then released in a pattern formed by the type of body tissue and by certain diseases. A computer translates the pattern into a very detailed image of parts of the body. A contrast material might be injected, just as with CT scans, but is used less often.

**5) PET scan (positron emission tomography scan):-**

For a PET scan, you receive an injection of glucose (a form of sugar) that contains a radioactive atom. The amount of radioactivity used is very low. Because cancer cells in the body are growing rapidly, they absorb large amounts of the radioactive sugar. A special camera can then create a picture of areas of radioactivity in the body. The picture is not finely detailed like a CT or MRI scan, but it can provide helpful information about your whole body.

This test can be useful to see if the cancer has spread to lymph nodes. PET scans are also useful when your doctor thinks the cancer has spread but doesn't know where. Doctors find it most useful in people with advanced stages of melanoma. It is not very helpful in people with early stage melanoma.

After all traces of the tumor have been removed, you may see an oncologist, a cancer specialist. If the melanoma has spread to other areas or if there is a good chance the melanoma might come back, the oncologist may prescribe additional treatment.

**TREATMENT** [13,14,27]

After diagnosis and staging, the doctor develops a treatment plan to fit each patient's needs. Treatment for melanoma depends on the extent of the disease, the patient's age and general health, as well as other factors.

People with melanoma are often treated by a team of specialists, which may include a dermatologist, surgeon, medical oncologist, and plastic surgeon. The standard treatment for melanoma is surgery; in some cases, doctors may also use chemotherapy, biological therapy, or radiation therapy. The doctors may decide to use one treatment method or a combination of methods.

**Methods of Treatment:-****1) Surgery:-** [14]

Surgery to remove (excise) a melanoma is the standard treatment for this disease. It is necessary to remove not only the tumor but also some normal tissue around it in order to minimize the chance that any cancer will be left in the area.

The width and depth of surrounding skin that needs to be removed depends on the thickness of the melanoma and how deeply it has invaded the skin. In cases in which the melanoma is very thin, enough tissue is often removed during the biopsy, and no further surgery is necessary. If the melanoma was not completely removed during the biopsy, the doctor takes out the remaining tumor. In most cases, additional surgery is performed to remove normal-looking tissue around the tumor (called the margin) to make sure all melanoma cells are removed. This is necessary, even for thin melanomas. For thick melanomas, it may be necessary to do a wider excision to take out a larger margin of tissue.

If a large area of tissue is removed, a skin graft may be done at the same time. For this procedure, the doctor uses skin from another part of the body to replace the

skin that was removed.

Lymph nodes near the tumor may be removed during surgery because cancer can spread through the lymphatic system. If the pathologist finds cancer cells in the lymph nodes, it may mean that the disease has spread to other parts of the body.

Surgery is generally not effective in controlling melanoma that is known to have spread to other parts of the body. In such cases, doctors may use other methods of treatment, such as chemotherapy, biological therapy, radiation therapy, or a combination of these methods. When therapy is given after surgery (primary therapy) to remove all cancerous tissue, the treatment is called adjuvant therapy. The goal of adjuvant therapy is to kill any undetected cancer cells that may remain in the body.

## 2) Chemotherapy:-

Chemotherapy is the use of drugs to kill cancer cells. It is generally a systemic therapy, meaning that it can affect cancer cells throughout the body. In chemotherapy, one or more anticancer drugs are given by mouth or by injection into a blood vessel (intravenous). Either way, the drugs enter the bloodstream and travel through the body. Chemotherapy is usually given in cycles: a treatment period followed by a recovery period, then another treatment period, and so on. Usually a patient has chemotherapy as an outpatient (at the hospital, at the doctor's office, or at home). However, depending on which drugs are given and the patient's general health, a short hospital stay may be needed.

One method of giving chemotherapy drugs currently under investigation is called limb perfusion. It is being tested for use when melanoma occurs only on an arm or leg. In limb perfusion the flow of blood to and from the limb is stopped for a while with a tourniquet. Anticancer drugs are then put into the blood of the limb. The patient receives high doses of drugs directly into the area where the melanoma occurred. Since most of the anticancer drugs remain in one limb, limb perfusion is not truly systemic therapy.

## 3) Biological therapy:-<sup>[27]</sup>

Biological therapy (also called immunotherapy) is a form of treatment that uses the body's immune system, either directly or indirectly, to fight cancer or to lessen side effects caused by some cancer treatments. Biological therapy is also a systemic therapy and involves the use of substances called biological response modifiers (BRMs). The body normally produces these substances in small amounts in response to infection and disease. Using modern laboratory techniques, scientists can produce BRMs in large amounts for use in cancer treatment. In some cases, biological therapy given after surgery can help prevent melanoma from recurring. For patients with metastatic melanoma or a high risk of recurrence, interferon- $\alpha$  and interleukin-2 (also called aldesleukin) may be recommended after surgery

## 4) Radiation therapy:-

In some cases, radiation therapy (also called radiotherapy) is used to relieve some of the symptoms caused by melanoma. Radiation therapy is the use of high-energy rays to kill cancer cells. Radiation therapy is a local therapy; it affects cells only in the treated area. Radiation therapy is most commonly used to help control melanoma that has spread to the brain, bones, and other parts of the body.

## DRUGS USED FOR TREATMENT OF MELANOMA <sup>[30,24,26]</sup>

### Synthetic Drugs

#### 1) 5-fluorouracil:-

This compound is an antimetabolite that inhibit DNA synthesis and tumoricidal. It is employed in 5 % concentration in an ointment.<sup>[12]</sup>

#### 2) Interferon:-

Three classes of interferons are recognized.alpha produced by neutrophils,beta produced by fibroblast and gamma produced by lymphocytes.

#### 3) Carmustine:-

Carmustine or BCNU (= "bis-chloronitrosourea") is a mustard gas- related  $\alpha$ -chloronitrosourea compound used as an alkylating agent in chemotherapy.

#### 4) Dacarbazine:-

Dacarbazine (da-KAR-ba-zeen) (brand names DTIC, DTIC-Dome; also known as DIC or Imidazole Carboxamide) is an antineoplastic chemotherapy drug used in the treatment of various cancers, among them malignant melanoma, Hodgkin lymphoma, sarcoma, and islet cell carcinoma of the pancreas.

Dacarbazine is a member of the class of alkylating agents, which destroy cancer cells by adding an alkyl group (CnH2n+1) to its DNA.

#### 5) cisplatin:-

Cisplatin, cisplatinum, or cis-diamminedichloroplatinum(II) (CDDP) is a platinum-based chemotherapy drug used to treat various types of cancers, including sarcomas, some carcinomas (e.g. small cell lung cancer, and ovarian cancer), lymphomas, and germ cell tumors.

### Other synthetic drugs used in the treatment of melanoma include:-

Hydroxyurea, Droxia, Hydrea, Mylocel, Aldesleukin, Proleukin Bleomycin, Blenoxane, Blanoxan, Bleolem, Cisplatin, Platinol-AQ, Blastolem, Tecnoplatin, Carbazine, DTIC-Dome, DTIC, Dactinomycin, Cosmegen, Lomustine, CeeNU, Docetaxel, Taxotere, Roferon-A, Procarbazine, Matulane, Natulan, Temozolomide, Temodar, Temodal.

### Latest drugs used for treatments for Melanoma:-

- 1) Dacarbazine
- 2) Cisplatin
- 3) Vinblastine
- 4) Carmustine
- 5) Tamoxifem

**Ayurvedic plants used in the treatment of melanoma:-**

- 1) Manjishtha (Rubiaceae)
- 2) Aabha Gugglu (bursaraceae)
- 3) Laksha Gugglu (solanaceae)
- 4) Ocium sanctum (lamiaceae)
- 5) podophyllum (barberidaceae)
- 6) Kaishore Gugglu
- 7) Gandhak Rasayan
- 8) Kanchnara Gugglu
- 9) Kaishore Gugglu
- 10) Bhallatak Phalmajja Churna
- 11) Trifala Gugglu
- 12) Tribang Bhasma
- 13) Shilajatu Vati

**REFERENCE**

1. E. Elizabeth Patton, et. al., Genetic and environmental melanoma models in fish, *Pigment Cell & Melanoma Research*, Volume 23, Issue 3, 2010, page no.314–337
2. Landi Maria Teresa, et. al., Genome-wide association studies of pigmentation and skin cancer, *Pigment Cell & Melanoma Research*, Volume 23, Issue 5, 2010, page no. 587–606.
3. E. Elizabeth Patton, et. al., p53 prevents progression of nevi to melanoma predominantly through cell cycle regulation, *Pigment Cell & Melanoma Research*, Volume 23, Issue 3, 2010, page no. 314–337.
4. John T. Lee et. al., A Potent Inhibitor of the B-Raf V600E Oncogene, Selectively Inhibits V600E-positive Melanomas, *Pigment Cell & Melanoma Research*, volume 23, issue 5, 2010, page no. 345-355.
5. Kyle A., et. al., Smad7 Restricts Melanoma Invasion by Restoring N-cadherin Expression and Establishing Heterotypic Cell-Cell Interactions In Vivo, *Pigment Cell & Melanoma Research*, 2010.
6. M. Bonnet, et. Al. Anti-melanoma efficacy of internal radionuclide therapy in relation to melanin target distribution, *Pigment Cell & Melanoma Research*, Volume 23, Issue 5, 2010, page no. e1–e11.
7. Melissa L., et.al., Sox proteins in melanocyte development and melanoma, *Pigment Cell & Melanoma Research*, Volume 23, Issue 4, 2010 Page no. 496– 513.
8. Nanao Horike, et. al., Downregulation of SIK2 expression promotes the melanogenic program in mice, *Pigment Cell & Melanoma Research*, 2010.
9. Kevin G. Chen, et.al., Involvement of ABC transporters in melanogenesis and the development of multidrug resistance of melanoma, *Pigment Cell & Melanoma Research* Volume 22, 2010, Issue 6, page no. 740–749.
10. Richard A. Sturm, et. Al., Genetics of human iris colour and patterns, *Pigment Cell & Melanoma Research*, Volume 22, Issue 5, 2009, page no. 544–562
11. Marianne Berwick, et. Al., Are tanning beds “safe”? Human studies of melanoma, *Pigment Cell & Melanoma Research*, Volume 21, Issue 5, 2008, page no. 517–519
12. ashton h, et. al, treatment of skin tumors with 5-fluorouracil br. *J dermatol*, ed. (1970);82 page no. 207-209.
13. Bertram g. katzung, basic & clinical pharmacology, 9<sup>th</sup> ed. Mcgraw hill, page no. 898
14. melmon & morrelis, clinical pharmacology, 4<sup>th</sup> ed. Mcgraw hill page no.1014- 1019
15. munson paul, principles of pharmacology, basic concepts and clinical application, chapman & hall page no. 1263-1264.
16. Abbasi NR, et al. Utility of lesion diameter in the clinical diagnosis of cutaneous melanoma. *Arch Dermatol*. 2008;page no.144:469-474.
17. Basal cell and squamous cell cancers: NCCN Medical Practice Guidelines and Oncology; Volume.1. 2009.
18. Brantsch KD, et al. Analysis of risk factors determining prognosis of cutaneous squamous-cell carcinoma: a prospective study. *The Lancet Oncology*. 2008 page no.:713-720.
19. Clinical practice guideline for melanoma: NCCN Medical Practice Guidelines and Oncology; Volume.2., 2009.
20. Eggermont AM, et al.: Adjuvant therapy with pegylated interferon alfa-2b versus observation alone in resected stage III melanoma: EORTC Melanoma, 2008, page no. 117-26.
21. Goodson AG, et al.. Strategies for early melanoma detection: Approaches to the patient with nevi. *J Am Acad Dermatol*. 2009 page no. 719-735.
22. Lange JR, Fecher LA, eds. *Abeloff's Clinical Oncology*. 4th ed. Philadelphia, Pa: Churchill Livingstone; 2008:chap 73.
23. Markovick SN, et al. Malignant melanoma in the 21st century, part 1: epidemiology, risk factors, screening, prevention, and diagnosis. *Mayo Clin Proc*. 2007, page no.364-380.
24. Suh KY, et, al., *Acad Dermatol, Review*, 2009 volume (3) page no.508-514
25. Vestergaard ME, et al. Treatment for Metastatic Ocular Melanoma, *NCI Cancer Bulletin*. 2006 volume (10).
26. Paek SC, et al. (2008). Cutaneous melanoma., *Fitzpatrick's Dermatology in General Medicine*, McGraw-Hill Medical, 7th ed., vol. 1, page no. 137-155
27. Mc Wang SQ, et al. (2001). Ultraviolet A and melanoma: A review. *Journal of the American Academy of Dermatology*, page no. 134-1157.