

# Bisphosphonate-Related Osteonecrosis of the Jaws [BRONJ]

**Dr. M.P.Santhosh Kumar** M.D.S.

*Reader, Department Of Oral and Maxillofacial Surgery*

*Saveetha Dental College and Hospital*

*162, Poonamallee High Road, Velappanchavadi, Chennai, Tamilnadu 600077*

**Sagunthala Ettikan**

*House Surgeon, Saveetha Dental College*

---

## Abstract

Bisphosphonates are antiresorptive agents used to treat many systemic disorders like multiple myeloma, paget's disease, osteoporosis, hypercalcaemia of malignancy and cancer metastasis. But the main adverse effect is the development of osteonecrosis of jaws. The objective of this article is to review the literature about chemistry, pharmacology and mechanism of action of bisphosphonates. Also literature is reviewed regarding etiopathogenesis, risk factors, prevention and treatment strategies for bisphosphonate related osteonecrosis of the jaws.

### *Conclusion:*

Patients receiving high doses of nitrogen containing BP intravenously are at high risk of BRONJ development than when oral bisphosphonates are used. Dentists must be aware of this condition and all dental preventive measures must be taken to avoid complications of BRONJ before and during BP therapy. Therefore dental examination and treatment of all dental diseases is highly recommended prior to BP administration. Moreover, all patients taking BPs have to be informed of the benefits and risks of treatment and should be educated about this condition and encouraged to maintain an excellent level of dental hygiene and care and regular dental visits. Conservative approach is sufficient in treating most of the cases of BRONJ.

## Keywords

***Bisphosphonate, Osteonecrosis, Jaw, Osteoporosis***

---

## INTRODUCTION

Bisphosphonates (BPs) are a group of synthetic pharmacological agents used as anti-osteoclastic, anti-resorptive agents in calcium metabolism disorders such as osteoporosis, multiple myeloma, Paget's disease and hypercalcaemia of malignancy and cancers that have metastasized to the bone[1]. The primary objectives of administering these drugs are to improve bone morphology, prevent bone destruction and pathologic fractures, and reduce pain associated with the metastatic bone disease whilst decelerating bone resorption [2-4] which significantly improves the quality of life of the affected patients. They have proven to reduce skeletal-related events in cancer patients and also vertebral and non-vertebral fractures in patients with osteoporosis.[5,6] But the biggest adverse reaction is development of osteonecrosis of the jaws. Even though patient's benefit of BP therapy is huge, various side effects may develop. Bisphosphonate-related osteonecrosis of the jaws (BRONJ) is among the most serious ones. Oncologic patients receiving high doses of BP intravenously are at high risk of BRONJ development. The purpose of this article is to discuss chemistry and pharmacology of bisphosphonates, and to review the literature about etiopathogenesis, risk factors, prevention and treatment strategies for BRONJ.

## Chemistry of bisphosphonates

Bisphosphonates are related to pyrophosphates [fig 1] and substituting a carbon atom for the oxygen atom in the backbone of the pyrophosphate molecule turns it into a bisphosphonate.[fig2] Bisphosphonates are rapidly bound to bone and can be removed only by acid dissolution, of which only osteoclasts have the capability. Their toxicity is selective to osteoclasts. The carbon atom further adds to bisphosphonate bone affinity by binding to hydroxyapatite crystals in bone, which is further enhanced to an irreversible binding if a hydroxyl group (OH) is added to the carbon's R-1 position [7,8] which is the cause for BRONJ. The R-2 position on this backbone carbon atom relates to potency and [8,9] Nitrogen atoms in the side chain in this position increase potency and efficacy.

BPs are classified into: non-nitrogen containing BPs (NNBP) and nitrogen containing BPs (NBP) depending on the presence or absence of nitrogen in their R2 group.[table1] However, Russell et al. [10] further divided the NBPs into Alkyl-amino and Heterocyclic NBPs based on the mode of action.

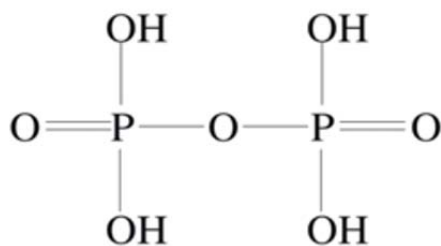


Fig1 Pyrophosphate

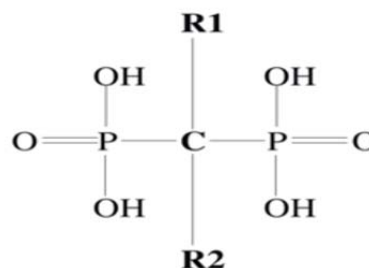


Fig 2 Bisphosphonate

Table 1 Classification of BPs

Type of BPS	Potency	Administration	Main indications
<b>Non nitrogen BPs</b>			
Etidronate	1	Oral	Osteoporosis, Paget's disease of bone
Clodronate	10	Oral/ Intravenous	Osteoporosis, Paget's disease of bone
Tiludronate	10	Oral	Paget's disease of bone
<b>Nitrogen BPs</b>			
Pamidronate	100	Intravenous	Osteolytic bone metastases of breast cancer and osteolytic lesions of multiple myeloma, Paget's disease of bone
Alendronate	500	Oral	Osteoporosis, paget's disease of bone
Ibandronate	1000	Oral, Intravenous	osteoporosis
Risedronate	2000	Oral, Intravenous	Osteoporosis, Paget's disease of bone, osteolytic lesions of multiple myeloma, hypercalcemia of malignancy
Zoledronate	10000	Intravenous	Osteolytic lesions of multiple myeloma and metastases from solid tumors, hypercalcemia of malignancy

### Pharmacology of Bisphosphonate

Clinically, both the NNBP and NBP are used as antiresorptive agents but the NNBP are known to be less potent and thus are mainly used in management of osteoporosis whereas the heterocyclic NBPs are the most potent BPs used in severe bone resorption cases like in malignancies. Orally administered BPs may induce recurrent ulcers with burning sensation and blisters in the oral cavity, erosive oesophagitis, oesophageal stenosis, uveitis, gastric ulcerations and abdominal pain [11-13]. However, more serious effects such as BRONJ, is seen most commonly after intravenous NBPs such as pamidronate and zoledronate [14]. The half-life of bisphosphonates is approximately 10 years, and therefore prolonged use of this drug causes substantial drug accumulation within the skeleton.

### Mechanism of action of Bisphosphonates

Bisphosphonates are anti-resorptive, anti-angiogenic and anti tumoricidal agents. Its therapeutic effect also causes adverse side effects like BRONJ. Cancer proliferation in bone is caused by the cancer's elaboration of receptor activator nuclear Kappa-b ligand (RANKL), which normally activates the receptor activator nuclear Kappa-b (RANK) receptors on the osteoclast cell membrane to actively resorb bone and create resorption cavities into which the cancer proliferates [7]. The mechanism of bisphosphonate toxicity to bone is due to death of

osteoclasts.[15,16] Non-nitrogen containing BPs are taken up by the osteoclasts and trigger intracellular mechanisms leading to apoptosis. This is bisphosphonates' drug effect which is also their therapeutic effect. Nitrogen containing BPs cause toxicity on osteoclasts which is by interruption of the Mevalonate branch pathway, [fig 3]which is vital to the survival of osteoclasts because it produces isoprenoid lipids [16,17]. The specific point in this pathway is primarily the inhibition of the farnesyl synthetase enzyme, which after several downstream synthetic steps results in geranylgeranyl proteins, which comprise part of the isoprenoid lipids [16]. Bisphosphonates also inhibit differentiation of osteoclasts and stimulates osteoblasts to produce osteoclast-inhibiting factor [18]. Therefore, the net result is reduced numbers of osteoclasts and reduced bone resorption. Bisphosphonates inhibit protein prenylation in cancer cells and also reduce adhesion, invasion, and viability of cancer cells and may activate gamma delta T cells, which have tumoricidal activity [19]. In vitro, zoledronic acid inhibits angiogenesis mediated through basic fibroblast growth factor and may induce apoptosis of endothelial cells [20]. Antiangiogenic activity may also occur through lowering circulating levels of vascular endothelial growth factor and platelet-derived growth factor, both of which are proangiogenic. In osteoporosis, the bisphosphonates also inhibit osteoclast-mediated bone resorption, which reduces the gradual reduction in bone mass with ageing and menopause in women.

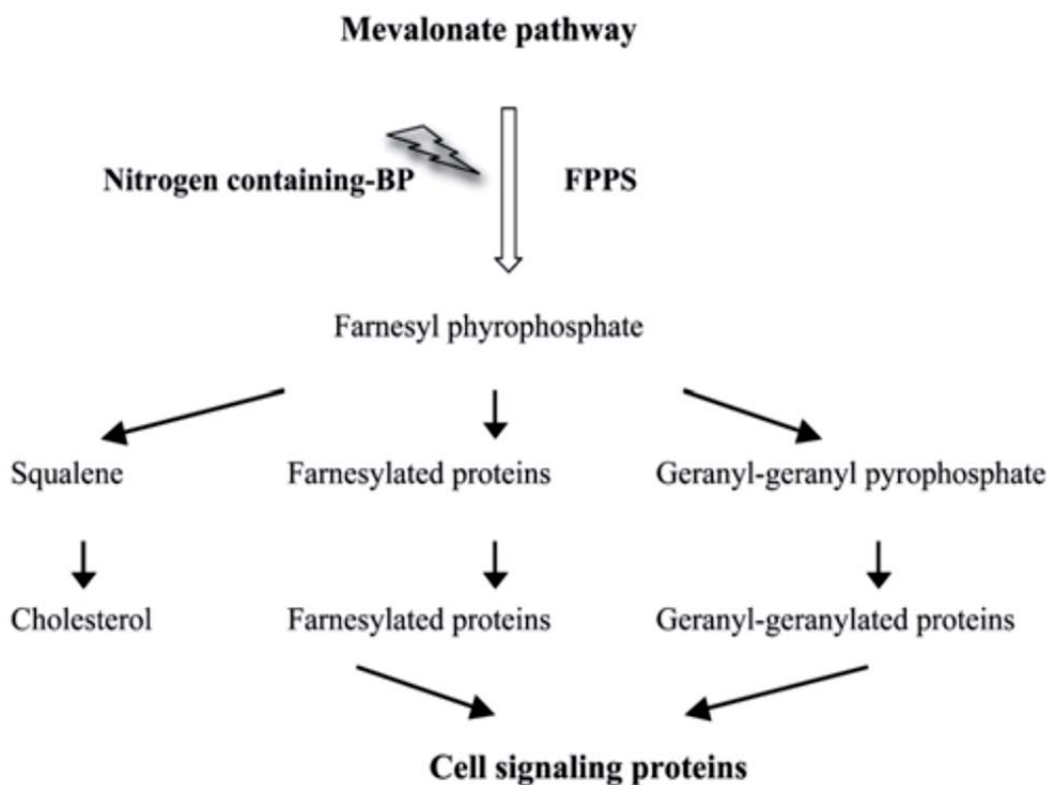


Fig 3

### Etiopathogenesis of BRONJ

Osteonecrosis of jaw caused by bisphosphonates was first reported by Marx in 2003.[21] The exact mechanism is not known, but due to certain unique conditions in jaws, they occur in jaws than in other bones of the body. (1) the jaw bones are separated from the oral environment from a very thin mucosa which is easily breached (2) the oral cavity is filled with bacteria and the jaws are often involved in infection through either the periodontal ligament or the pulp, (3) dentoalveolar surgery is a common procedure (eg, extractions, periodontal surgeries, apicoectomies) in which bone is exposed to a bacteria-rich environment, and (4) the rate of turnover of the jawbones is higher than that for the long bones.[22] When BPs accumulate bone turnover becomes low, whereas infection or surgery requires increased bone turnover for healing, thus it does not occur. The lingual plate/mylohyoid area is also a common site for spontaneously occurring BRONJ.

Even if BRONJ seems to be a primarily bone condition, some studies showed a toxic effect of bisphosphonates (BP) on the oral epithelium with inhibition of normal soft tissue healing. Because epithelialisation is an essential step in post intervention wound healing, it has been hypothesized that the soft tissue of the oral mucosa could be a key factor in BRONJ development. Moreover, a relevant role has been advocated for the antiangiogenic effect of BP, particularly for the possible failure of healing processes with exposure of bone, which could then become necrotic. Other factors likely involved in the BRONJ etiopathogenesis are the anatomic site, bacterial infection, diabetes, smoking, concurrent medications, and genetic predisposition.

### Risk factors for BRONJ

Nitrogen containing BPs [zoledronate], cumulative dose of BPs, duration of BP therapy [longer duration], dentoalveolar surgery [especially extraction and other surgeries like implant placement, periodontal and apical surgery], trauma [surgical or prosthetic], infection, Old age, intravenous preparations [zoledronate, pamidronate], comorbid conditions [diabetes mellitus], concomitant medications [thalidomide, systemic corticosteroids] and genetic factors. Approximately 25% of BRONJ cases develop spontaneously, whereas 75% of cases are initiated by a dental pathologic condition or surgical procedure [23], including tooth extractions, periodontal surgery, untreated periodontal inflammation, abscessed teeth, failed root canal fills, and apical surgery.

### DIAGNOSIS AND CLINICAL PRESENTATION

The definition of BRONJ put forth by the American Association of Oral and Maxillofacial Surgeons is "exposed bone in the maxilla or mandible that fails to heal within eight weeks in a patient receiving or who has received a systemic bisphosphonate and who has not received local radiation therapy to the jaws" [9,24].

It takes approximately 6 months of intravenous bisphosphonates or 3 years [156 continuous weeks] of oral bisphosphonates to place a patient at risk for BRONJ. The difference is due to low lipid solubility of oral bisphosphonates of 0.63% and clinically exposed bone does not appear until after a 3-year exposure, with the incidence and severity increasing with each additional year of drug use. Publications have estimated a wide incidence range for intravenous bisphosphonate-induced osteonecrosis from as

little as 0.8% [25] to as much as 30% [26]; for oral aminobisphosphonate-induced osteonecrosis the incidence has been reported to be between 0.007% and 0.01% [7], with a median for intravenous bisphosphonates at 8% and for oral bisphosphonates at 0.015%.

Diagnosis of BRONJ is primarily based on patient history and clinical examination. Only maxilla and mandible are susceptible to this condition, when compared to other bones of the skeleton. It is common in mandible than maxilla by a ratio of 2:1 BRONJ always begins in the alveolar bone, where it may extend to the inferior border or rami of the mandible or into the zygoma or maxillary sinus walls about the maxilla. This development is caused by the greater bone turnover rate and greater reliance on osteoclast-mediated remodeling in the alveolar bone, which results from the pressure and tension forces placed on the alveolar bone by occlusion, denture wearing, periodontal inflammation, failing root canal fills, abscesses, and surgical trauma. More over the turnover of alveolar bone is 10-fold greater than in the long bones. It occurs commonly in areas with thin mucosa overlying bony prominences, such as tori, bony exostoses, and the mylohyoid

ridge. Signs and symptoms that may occur before the development of clinically detectable BRONJ include pain, tooth mobility, mucosal swelling, erythema, ulceration, and the development of sinus tracts, paresthesia. Chronic maxillary sinusitis secondary to BRONJ with or without an oral-antral fistula may be the presenting symptom in patients who have maxillary bone involvement. The exposed necrotic bone may be extensive or relatively small that belies a greater amount of necrotic bone beneath. Pain is more likely with greater amounts of exposed bone and when infection sets in. Patients may have other Bisphosphonate-related osteonecrosis of the jaws symptoms, which are bred by the infection, such as trismus, halitosis and recurrent abscesses, sinusitis with or without oro-antral fistula. The most frequent micro-organisms found on the exposed bone are Actinomyces, Viellonella, Eikenella, and Moraxella species, all of which are most sensitive to penicillin.

Early radiographic signs of a widened periodontal ligament space and sclerosis of the lamina dura attest to alveolar bone as the starting point of BRONJ. In extensive cases, regions of mottled bone or sequestra formation are seen, the osteolytic changes may extend till lower border of mandible resulting in pathologic fracture.

#### Differential diagnosis

Osteomyelitis, osteoradionecrosis, benign sequestration of the lingual plate, necrotizing periodontitis, necrotizing stomatitis, herpes zoster infection of jaw bones.

#### MANAGEMENT

The goal of management for patients at risk for developing BRONJ or who have active disease is to preserve the quality of life through controlling pain, managing infection, and preventing the development of new areas of necrosis. Therapy of BRONJ is generally difficult and should be adjusted to individual patient's needs based on the general medical status, the stage of BRONJ and life expectancy. An

algorithm for management has been given by AAOMS based on stage of the disease. [table 2]

**Table 2 Staging And Management Of BRONJ**

Stage	Clinical presentation	Management
At risk	No exposed bone	Patient education
1	Asymptomatic exposed bone with little soft tissue inflammation	Patient education; antibacterial rinses; careful follow-up
2	Exposed bone with pain, and usually with associated surrounding soft tissue inflammation or infection	Patient education; antibacterial rinses; antibiotics; superficial debridement of bone to dislodge loose fragments and smooth rough contours; careful follow up
3	Exposed bone with pain and usually with associated soft tissue inflammation or infection; may see osteolysis extending to the inferior border of mandible or pathologic fracture; may see extraoral fistula	Patient education; antibacterial rinses; antibiotics; palliative surgery; careful follow-up

\* 0.12% chlorhexidine digluconate mouth wash

\* Follow-ups for asymptomatic patients should occur every 2 to 3 months, and every 1 to 2

weeks until the acute symptoms have resolved for stage 2 and 3 disease.

\* Commonly used antibiotics include penicillin, amoxicillin, cephalexin, clindamycin, metronidazole, or first-generation fluoroquinolones.

#### INTRAVENOUS BISPHOSPHONATE-INDUCED OSTEONECROSIS

The osteonecrosis induced by intravenous bisphosphonates is generally more extensive, more severe, more unresponsive to discontinuation of the drug, and less responsive to surgical debridement, occurs in a shorter time, and incidence rate is very high because there is 64 fold increase in bioavailability of the drug when given through intravenous route than oral route.

#### Preventive measures before I.V. BP therapy

Teeth that are nonrestorable, abscessed, have failing root canal fills, or are periodontally unsalvageable should be extracted first followed by periodontal care to arrest periodontal inflammation, salvage treatable teeth, and educate patients regarding self-maintenance. Restorative and prosthodontic procedures can be carried out before and during intravenous bisphosphonate therapy. New implant placement and adult orthodontics are contraindicated.

#### Preventive measures during I.V. BP therapy

Once a patient has received four to six doses of an intravenous bisphosphonate, there is significant suppression of bone turnover in the alveolar bone, which makes bone healing unpredictable and risky for osteonecrosis. During this phase of intravenous bisphosphonate therapy, avoiding invasive oral surgical procedures, including tooth extractions, dental implant placements, adult orthodontics periodontal surgery, ridge augmentation grafts, and apical surgeries. [27]Non-invasive restorative procedures like crowns, bridges and dentures can be carried out safely. Teeth that are nonrestorable are better treated, with a root

canal fill and crown amputation than with extraction and teeth with mobility are best splinted if possible and failing root canal fills should be reinstrumented and refilled as opposed to extracted or treated by apical surgery. If extraction is unavoidable, patients should be informed of the risks of BRONJ and a consent form should be obtained.

#### **Treatment of I.V. BRONJ**

The goal of treatment is to prevent or alleviate pain, reduce infections, and stabilize the progression of exposed bone. Patients should be informed that exposed bone is likely to be permanent and requires ongoing monitoring and medications, self maintenance for control; in some cases, a bony resection may be necessary. Patient must be made to understand that bisphosphonate has been beneficial to them by containing their metastatic cancer despite the osteonecrosis. Patients without pain are treated with only a 0.12% chlorhexidine (Peridex) 30-mL swish-and-spit regimen three times daily. If pain and infection are present, penicillin VK, 500 mg, four times daily is added to the 0.12% chlorhexidine regimen. If a patient is penicillin allergic, levofloxacin 500 mg, once daily is the best alternative. Other alternatives are doxycycline 100mg daily, or zithromycin 250mg daily. In uncontrollable cases metronidazole can be added. Majority of them can be managed by this protocol, only a very few require resection and reconstruction.[23]

#### **ORAL BISPHOSPHONATE-INDUCED OSTEONECROSIS**

Its prevalence rate is very less than I.V.induced osteonecrosis, takes more time to occur and its clinical expression is also less extensive and more responsive to surgery, and its risk of development can be assessed and stratified by a simple blood test. [28]It is a morning fasting serum C-terminal telopeptide (CTX), which measures an octapeptide fragment released from type I bone collagen when an osteoclast resorbs bone and is an index of bone turnover.[29] Values

less than 100 pg/mL represent high risk, values between 100 pg/mL and 150 pg/mL represent moderate risk, and values more than 150 pg/mL represent minimal or no risk.

#### **Prevention of oral BRONJ**

Concomitant use of certain drugs like methotrexate, prednisone, H2 blocking drugs [Ranitidine] with oral bisphosphonates may increase the risk of BRONJ because of increased absorption of the bisphosphonate. A patient who has taken an oral bisphosphonate for less than 3 years can be treated as any other normal patient. Extractions, periodontal procedures, restorative procedures can be done in such patients. In a patient with a history of oral bisphosphonate therapy exceeding 3 years, CTX test are recommended and values more than 150 pg/mL indicates that invasive procedures can be accomplished with anticipation of healing; however, values less than 150 pg/mL indicate a potential healing compromise that may result in osteonecrosis. In such cases, a temporary discontinuation of the drug called 'Drug Holiday' is recommended for 4-6 months, with repeat CTX which may normally show an increase in levels of 20-25 pg/mL. Studies have shown that even extended drug holidays from oral bisphosphonates of up to 5 years have not resulted in

an increased incidence of osteoporosis-related fractures [30,31].

#### **Treatment of oral BRONJ**

The initial therapy for oral bisphosphonate induced osteonecrosis is prevention of pain with the use of 0.12% chlorhexidine 30-mL swish-and-spit regimen three times daily, CTX test, advise drug holiday, antibiotics if there is pain and infection. The antibiotics are same as for the I.V. BRONJ. After 6 months drug holiday, CTX levels may rise to 150 pg/mL, thus necrotic lesion of bone may resolve spontaneously without debridement. Other cases may require sequestration/debridement of necrotic bone and primary closure. Very few cases may require resection and reconstruction. As long as CTX levels are kept above 150 pg/mL by prescribing non-bisphosphonate drugs, recurrences may not occur.

HBO therapy, topical application of platelet rich plasma, Nd:Yag laser biostimulation, systemic administration of teriparatide, a form of synthetic parathormone [32-34], have been tried as new treatment modalities successfully. Short-term discontinuation of BPs do not offer benefit, whereas long-term discontinuation may be beneficial in stabilizing established sites of BRONJ, reducing the risk for new areas of BRONJ to develop, and reducing clinical symptoms [9].The benefits of therapy must be carefully weighed against risks for fracture, cancer progression, and hypercalcemia. At some institutions, the recommendation is to use intravenous bisphosphonates in patients who have cancer for 2 years and to discontinue the drug if the patient is experiencing remission or a stable state, with the option to continue or restart therapy if disease worsens or symptoms progress.[35]

#### **CONCLUSION**

BRONJ as a side-effect of BP therapy is a relatively rare complication but may have a huge impact on the quality of life of the affected patients. Dentists must be aware of this condition and about its prevention and treatment strategies. Patients receiving high doses of nitrogen containing BP intravenously are at high risk of BRONJ development. Oral administration causes significantly lower risk of BRONJ. Increased duration of administration of BPs is also an important factor for development of BRONJ. Conservative approach is sufficient in treating most of the cases of BRONJ. In some cases surgery may be the treatment option.[36] When making the decision to perform surgical procedures for the treatment of BRONJ, the deal between benefit and potential risks according to clinical circumstances of each patient should be considered.

But complete resolution of the condition is often not possible. All dental preventive measures must be taken to avoid complications of BRONJ before and during BP therapy. Therefore dental examination and treatment of all dental diseases is highly recommended prior to BP administration. Moreover, all patients taking BPs have to be informed of the benefits and risks of treatment and should be educated about this condition and encouraged to maintain an excellent level of dental hygiene and care and regular dental visits.[37] Reduction of symptoms and infectious complications is the aim of BRONJ

management. Success of the treatment depends on close cooperation of the dentist, physician and the patient.

#### REFERENCES

- Fleisch H: Bisphosphonates: mechanisms of action. *Endocr Rev* 1998, 19:80–100.
- Reid IR, Miller P, Lyles K, Fraser W, Brown JP, Saidi Y, Mesenbrink P, Su G, Pak J, Zelenak K, Luchi M, Richardson P, Hosking D: Comparison of a single infusion of zoledronic acid with risedronate for Paget's disease. *N Engl J Med* 2005, 353:898–908.
- Hillner BE, Ingle JN, Berenson JR, Janjan NA, Albain KS, Lipton A, Yee G, Biermann JS, Chlebowski RT, Pfister DG: American society of clinical oncology guideline on the role of bisphosphonates in breast cancer. American society of clinical oncology bisphosphonates expert panel. *J Clin Oncol* 2000, 18:1378–91.
- Petcu EB, Schug SA, Smith H: Clinical evaluation of onset of analgesia using intravenous pamidronate in metastatic bone pain. *J Pain Symptom Manage* 2002, 24:281–4.
- Liberian UA, Weiss SR, Broll J, et al. Effect of oral alendronate on bone mineral density and the incidence of fractures in postmenopausal osteoporosis. The Alendronate Phase III Osteoporosis Treatment Study Group. *N Engl J Med* 1995;333(22):1437–43.
- Black DM, Delmas PD, Eastell R, et al. Once-yearly zoledronic acid for treatment of postmenopausal osteoporosis. *N Engl J Med* 2007;356(18):1809–22.
- Marx RE, editor. Oral and intravenous bisphosphonate-induced osteonecrosis of the jaws: history, etiology, prevention, and treatment. Hanover Park (IL): Quintessence Publishing; 2006.
- Russell RGA, Croucher PI, Rogers MJ. Bisphosphonates: pharmacology, mechanisms of action and clinical uses. *Osteoporos Int* 1999; 9(Suppl 2):S66–80.
- American Association Oral Maxillofacial Surgeons. Position paper on bisphosphonate-related osteonecrosis of the jaws. *J Oral Maxillofac Surg* 2007;65(3): 369–76.
- Russell RGG, Watts NB, Ebetino FH, Rogers MJ: Mechanisms of action of bisphosphonates: similarities and differences and their potential influence on clinical efficacy. *Osteoporos Int* 2008, 19:733–59.
- Kharazmi M, Persson U, Warfvinge G: Pharmacovigilance of oral bisphosphonates: adverse effects manifesting in the soft tissue of the oral cavity. *J Oral Maxillofac Surg* 2012, 70(12):2793–7.
- Lanza FL, Hunt RH, Thomson AB, Provenza JM, Blank MA: Endoscopic comparison of esophageal and gastroduodenal effects of risedronate and alendronate in postmenopausal women. *Gastroenterology* 2000, 119:631–8.
- Abraham SC, Cruz-Correa M, Lee LA, Yardley JH, Wu TT: Alendronate-associated esophageal injury: pathologic and endoscopic features. *Mod Pathol* 1999, 12:1152–7.
- Fortuna G, Ruoppo E, Pollio A, Aria M, Adamo D, Leuci S, Orabona GD, Mignogna MD: Multiple myeloma vs. breast cancer patients with bisphosphonates-related osteonecrosis of the jaws: a comparative analysis of response to treatment and predictors of outcome. *J Oral Pathol Med* 2012, 41:222–8.
- Widler L, Knut JA, Marcus A, et al. Highly potent germinal bisphosphonates: from pamidronate disodium (Aredia) to zoledronic acid (Zometa). *J Med Chem* 2002;45:3721–38.
- Van Beek Er, Lowick CWGM, Papapoulos SE. Bisphosphonates suppress bone resorption by a direct effect on early osteoclast precursors without affecting the osteoclastogenic capacity of osteogenic cells: the role of protein geranylation in the action of nitrogen containing bisphosphonates on osteoclast precursors. *Bone* 2002;30:64–70.
- Glowacki J. Bisphosphonates and bone. *Orthopedic Journal at Harvard Medical School* 2005;7: 64–7.
- Santini D, Vespasiani Gentilucci U, Vincenzi B, et al. The antineoplastic role of bisphosphonates: from basic research to clinical evidence. *Ann Oncol* 2003;14(10):1468–76.
- Kunzmann V, Bauer E, Feurle J, et al. Stimulation of gammadelta T cells by aminobisphosphonates and induction of antiplasma cell activity in multiple myeloma. *Blood* 2000; 96(2):384–92.
- Wood J, Bonjean K, Ruetz S, et al. Novel antiangiogenic effects of the bisphosphonate compound zoledronic acid. *J Pharmacol Exp Ther* 2002;302(3):1055–61.
- Marx RE. Pamidronate (Aredia) and zoledronate (Zometa) induced avascular necrosis of the jaws: a growing epidemic. *J Oral Maxillofac Surg*. 2003; 61(10): 1238–9.
- Huja SS, Fernandez SA, Hill KJ, et al. Remodeling dynamics in the alveolar process in skeletally mature dogs. *Anat Rec A Discov Mol Cell Evol Biol* 2006;288(12):1243–9.
- Mellal A, Wiskott HW, Botsis J, et al. Stimulating effect of implant loading on surrounding bone: comparison in of three numerical models and validation by in vivo data. *Clin Oral Implants Res* 2004;15: 239–48.
- Ruggiero SL, Dodson TB, Assael LA, et al. American Association of Oral and Maxillofacial Surgeons position paper on bisphosphonate related osteonecrosis of the jaws: 2009 update. *J Oral Maxillofac Surg* 2009;67:2-12.
- Hoff A. Expert panel recommendation for prevention, diagnosis, and treatment of osteonecrosis of the jaws. *Oncology Drug Advisory Committee Meeting*. East Hanover, NJ, Novartis, March 4, 2005.
- Bamias A, Kastiris E, Bamaia C, et al. Osteonecrosis of the jaw in cancer after treatment with bisphosphonates: incidence and risk factors. *J Clin Oncol* 2005; 23:8580–7.
- Marx RE, Sawatari Y, Fortin M, et al. Bisphosphonate induced exposed bone (osteonecrosis/osteopetrosis) of the jaws: risk factors, recognition, prevention, and treatment. *J Oral Maxillofac Surg* 2005;63:1567–75.
- Marx RE, Cillo JE, Ulloa JJ. Oral bisphosphonate induced osteonecrosis: risk factors, prediction of risk using serum CTX testing, prevention, and treatment.
- Rosen HN, Moses AC, Garber J, et al. Serum CTX: a new marker of bone resorption that shows treatment effect more often than other markers because of low coefficient of variability and large changes with bisphosphonate therapy. *Calcif Tissue Int* 2000;66:100–3.
- Black Dm, Schwartz AV, Ensrud KE, et al. Effects of continuing or stopping alendronate after 5 years of treatment: the fracture intervention trial long term extension (FLEX). A randomized trial. *JAMA* 2006;296:2927–38.
- Bone HQ, Hosking D, Devogelar J-P, et al. Ten years experience with alendronate for osteoporosis in postmenopausal women. *N Engl J Med* 2004; 350:1189–99.
- Curi MM, Cossolin GS, Koga DH, et al. Treatment of avascular osteonecrosis of the mandible in cancer patients with a history of bisphosphonate therapy by combining bone resection and autologous platelet-rich plasma: Report of 3 cases. *J Oral Maxillofac Surg* 2007; 65(2):349–55.
- Vescovi P, Merigo E, Meleti M, et al. Nd:YAG laser biostimulation of bisphosphonate associated necrosis of the jawbone with and without surgical treatment. *Br J Oral Maxillofac Surg* 2007
- Harper RP, Fung E. Resolution of bisphosphonate-associated osteonecrosis of the mandible: possible application for intermittent low-dose parathyroid hormone [rhPTH(1-34)]. *J Oral Maxillofac Surg* 2007;65(3):573–80.
- Lacy MQ, Dispenzieri A, Gertz MA, et al. Mayo clinic consensus statement for the use of bisphosphonates in multiple myeloma. *Mayo Clin Proc* 2006;81(8):1047–5.
- Yoh Sawatari, Robert E. Marx, Bisphosphonates and Bisphosphonate Induced Osteonecrosis *Oral Maxillofacial Surg Clin N Am* 19 (2007) 487–98
- Salvatore L. Ruggiero, Sook-Bin Woo, Biophosphonate-Related Osteonecrosis of the Jaws *Dent Clin N Am* 52 (2008) 111–128