



Hepatoprotective Activity of Aqueous Leaf Extract of *Calotropis procera* a. (Asclepladaceae) in Paracetamol-Induced Liver Injury

*E.O. Agbaje and O. Ogunleye

Department of Pharmacology, Therapeutics & Toxicology

College of Medicine, University of Lagos

PMB 12003, Idi-Araba, Lagos-Nigeria.

Abstract

Liver injury is a major health problem that challenges not only healthcare professionals but also the pharmaceutical industry and drug regulatory agencies. The condition has been made more serious, since the available synthetic drugs to treat liver disorders also cause further damage to the liver. Hence, herbal drugs have become increasingly popular and their use is widespread. *Calotropis procera* is one of the plants that have been used locally as a hepatoprotective agent, therefore, the validation of the folkloric use constituted the main aim of the study, which explored the aqueous leaf extract.

Doses of 150, 400 and 800 mg/kg were administered to groups of animals one hour before dosing with 150 mg/kg paracetamol for 14 days. While the negative control received distilled water 10 ml/kg, the positive controls were treated with livolin 45 mg/kg and Vitamin C 200 mg/kg. Liver enzymes and serum biochemical parameters were assayed to evaluate the protective activity of the test agents.

The hepatotoxic effect of PCM was significantly ($p < 0.001$) reversed by Vitamin C and the three doses of plant extract; the effect which persisted even after cessation of therapy as recorded by the antioxidant and the liver enzymes, which was further underscored by the histopathological study. It could be concluded that *Calotropis procera* is hepatoprotective when ingested in low to moderate doses, which validated the folkloric use of the plant extract.

Keywords: *Calotropis procera*, Paracetamol, hepatoprotective, antioxidant.

INTRODUCTION

The liver, a vital organ of paramount importance is usually involved in the maintenance of metabolic functions and physiologic homeostasis of the organism, it is therefore exposed to exogenous and endogenous challenges, from xenobiotics, free radicals, food additives, pollutants, viral infections and alcohol; the factors which could overwhelm the natural protective mechanism of the liver to cause hepatic injury [1, 2]. More than 900 drugs have been implicated in causing liver injury, [3] and it is the most common reason for a drug to be withdrawn from the market. Drug-induced liver injury is responsible for 5 % of all hospital admissions and 50 % of all acute liver failures [4, 5].

Among the different and numerous drugs that are hepatotoxic is acetaminophen (paracetamol, PCM), which is usually well tolerated in prescribed dose but overdose results in drug-induced liver disease and acute liver failure worldwide [6].

Treatment of liver disorders is necessary, and must be done with proper and extensive care. There are a few conventional drugs that can stimulate liver function and offer hepatic protection or help in the regeneration of hepatic cells, but they have been found to be hepatotoxic at a particular dose range [7]. It therefore becomes imperative to evaluate natural compounds as effective alternatives.

Calotropis procera (CAP) is one of such plants that have been used in this environment for treating liver diseases. Its native range covers SW Asia (India, Pakistan, Afghanistan, Iran, Arabia and Jordan) and Africa (Somalia, Egypt, Libya, Algeria, Morocco, Mauritania, and Senegal). It is also found on the Caribbean islands, Thailand and Vietnam in S. America. It is a spreading shrub or small tree of about 4 m, exuding copious milky sap when cut or broken. Leaves are up to 15 cm long and 10 cm broad, with

a pointed tip, two rounded basal lobes and no leaf stalk; flowers waxy white, petals 5, purple-tipped inside and with a central purplish crown, carried in stalked clusters at the ends of the branches; fruit greyish-green, inflated, 8 to 12 cm long, containing numerous seeds with tufts of long silky hairs at one end [8]. It was reported that this plant contains flavonoids, alkaloids, cardiac glycosides, tannins, sterols and triterpenes [9] and numerous reports have been given about its medicinal uses. Among these are the antiinflammatory, antipyretic, analgesic, antimicrobial properties and larvicidal activity of the flowers [10, 11]; the latex of the plant was reported to possess analgesic and wound healing activity [12, 13], while, the roots have anti-fertility and anti-ulcer activities (Kamath and Rana, 2005; Basu *et al.*, 1997) [14, 15].

The present study was designed to evaluate the hepatoprotective activity of the aqueous leaf extract of *C. procera* using the paracetamol-induced hepatotoxicity model in rats.

MATERIALS AND METHODS

Plant Material

Fresh leaves of *Calotropis procera* were collected from Ikire in Osun state, through Mr. T.K. Odewo, and was authenticated at the Department of Botany and Microbiology, University of Lagos, Akoka, Lagos-State, Nigeria with voucher no LUH 3579.

Processing of plant material

The leaf of *Calotropis procera* was dried in an oven at a regulated temperature of 45 °C until the weight of the plant material was constant. The leaves were shredded by hand to tiny bits, resulting in coarse powder, which was extracted by boiling 120 g in 1800 ml distilled water on the hot plate for 30 min, and thereafter the mixture was kept for 24 h, while shaking intermittently to facilitate extraction. The extract was filtered using white cotton cloth and oven dried

at 45 °C. The extract was stored airtight in a sample bottle and kept refrigerated, until ready for use.

Animals used

Wistar albino rats of either sex weighing 100-160 g were procured from Laboratory Animal Centre, College of Medicine, University of Lagos, Idi-Araba, Lagos. They were housed in clean polypropylene cages under standard conditions of temperature 25 ± 2 °C and 12 h light/12 h dark cycle and fed with standard diet (growers pellet) from Nigeria Institute of Medical Research Yaba, Lagos, Nigeria, and clean drinking water. The animals were acclimatized for a period of two weeks before experimentation and all experimental procedures were carried out in compliance with the United States National Institute of Health (NIH) guide for care and use of Laboratory animals and recommendation of IASP Zimmerman [16].

Determination of free radical scavenging activity

The assay was conducted using 2,2-Diphenyl-1-1-picrylhydrazyl (DPPH) to measure the free radical scavenging activity of the plant samples using the methods proposed by early workers [17, 18]. An amount of 0.1 mM DPPH prepared in methyl alcohol was mixed with 3 ml each of methanol plant extracts ranging from 0.2-1 mg/ml. The reaction mixture was thoroughly vortexed and left in the dark at room temperature for 30 min. The absorbance of the resulting yellow coloured solution was then measured spectrophotometrically at 517 nm. An aliquot of 0.5 ml ascorbic acid and 0.5 ml garlic each was used as positive control/standard and deionized water used as blank. A decrease in absorbance of the reaction mixture indicates higher free radical scavenging activity. The scavenging ability of the extract was calculated using standard equation [19].

Phytochemical analysis

The extract suspended in distilled water at a concentration of 100 mg/kg was screened for tannins, flavonoids, cardiac glycosides, saponins and phlobatanins [20].

Model for Hepatoprotective properties of aqueous extract of *Calotropis procera* leaf.

The method earlier described [21] was modified and used in this study. The initial body weights of the animals were determined and animals were divided into seven groups (n = 10)

Group I: (negative control) administered with distilled water (10 ml/kg p.o.) once daily for a period of 14 days.

Group II: (paracetamol control), rats were treated with distilled water (10 ml/kg p.o.) followed by paracetamol (150 mg/kg p.o.) 1h later, once daily for a period of 14 days.

Group III: Vitamin C (200 mg/kg) followed by paracetamol (150 mg/kg p.o.) 1h later, once daily for 14 days.

Group IV: Livolin (45 mg/kg) followed by paracetamol (150 mg/kg) 1h later for 14 days.

Group V: Aqueous extract of *Calotropis procera* (150 mg/kg p.o.) and paracetamol (150 mg/kg p.o.) 1 h later, once daily for a period of 14 days.

Group VI: Aqueous extract of *C. procera* (400 mg/kg p.o.) and paracetamol (150 mg/kg p.o.) 1 h later, once daily for a period of 14 days.

Group V: Aqueous extract of *C. procera* (800 mg/kg) followed by paracetamol (150 mg/kg) 1 h later, once daily for 14 days.

After two weeks, drug treatment was terminated and rats were fasted for 24 h and thereafter weighed. Five rats were randomly selected from each group and humanely sacrificed, while the remaining five rats for reversibility test were kept for the next two weeks. After animal sacrifice, blood was collected into the plain, heparinized and EDTA bottles for analysis of hematological parameters and serum biochemical parameters.

TABLE 1: EFFECT OF AQUEOUS EXTRACT OF *CALOTROPIS PROCERA* ON ANTIOXIDANT ENZYMES AND MDA REACTIVITY IN LIVER SAMPLES OF PARACETAMOL TREATED RATS.

TREATMENT GROUP	GSH (U/mg pro)	SOD(U/mg pro)	CAT(U/mg pro)	MDA (U/mg pro)
Distilled water + Distilled water (10ml/kg)	0.19 ± 0.01 ^{aaa BBB VVV}	3.19 ± 0.14 ^{aaa BBB VVV}	22.08 ± 0.99 ^{aaa BBB VVV}	0.012 ± 0.00 ^{V BBB}
Distilled water (10ml/kg)+ Paracetamol(150mg/kg)	0.32 ± 0.002 ^{***VVV}	1.53 ± 0.08 ^{*** BBB VVV}	10.60 ± 0.59 ^{*** BBB VVV}	0.015 ± 0.00 ^{VVV BBB}
Vitamin C (200mg/kg)+ Paracetamol (150mg/kg)	0.09 ± 0.003 ^{*** aaa BBB}	2.51 ± 0.07 ^{*** aaa BBB}	17.38 ± 0.48 ^{*** aaa}	0.01±0.00 ^{* aaa BBB}
Livolin(45mg/kg) + Paracetamol(150mg/kg)	0.04 ± 0.002 ^{*** VVV}	1.96 ± 0.04 ^{*** aaa VVV}	13.55 ± 0.26 ^{*** aaa BBB VVV}	0.004 ± 0.0016 ^{*** aaa VVV}
150mg/kg of plant extract + Paracetamol (150mg/kg)	0.08 ± 0.004 ^{*** aaa BBB}	1.99 ± 0.06 ^{*** VVV aaa}	13.77 ± 0.42 ^{*** aaa VVV}	0.0078 ± 0.0048 ^{** aaa BB}
400mg/kg of plant extract + Paracetamol (150mg/kg)	0.15 ± 0.006 ^{*** aaa BBBVVV}	1.99 ± 0.04 ^{***VVV aaa}	13.76 ± 0.27 ^{*** aaa VVV}	0.0094 ± 0.0075 ^{* aaa BBB}
800mg/kg of plant extract + Paracetamol (150mg/kg)	0.08 ± 0.005 ^{*** aaa BBB}	2.29 ± 0.03 ^{*** aaa BBBV}	15.93 ± 0.16 ^{*** aaa BB}	0.01 ± 0.00 ^{*** aaa V B}
Livolin (45mg/kg) + Paracetamol (150mg/kg) R	0.068 ± 0.005	2.60 ± 0.22	18.02 ± 1.52 ^β	0.004 ± 0.0004 ^{BBB}
Distilled water (10ml/kg)+ Paracetamol (150mg/kg) R	0.060 ± 0.005	1.78 ± 0.17 [*]	12.32 ± 1.17 ^a	0.010 ± 0.0014 ^{**}
800mg/kg of the plant extract+Paracetamol (150mg/kg) R	0.086 ± 0.013	2.70 ± 0.41 ^β	18.32 ± 2.19 ^β	0.006 ± 0.0003 ^{BB a α}

Data are expressed as mean ± S.E.M (n=5). (*P<0.05, **P<0.01, ***P<0.001) vs. control; (^aP<0.05, ^{aa}P<0.01, ^{aaa}P<0.001) vs. paracetamol; (^βP<0.05, ^{BBB}P<0.01, ^{VVV}P<0.001) vs. livolin; (^VP<0.05, ^{VVV}P<0.01, ^{VVVV}P<0.001) vs. Vitamin C. (1-way ANOVA followed by Dunnett's multiple comparison test).

Data are expressed mean \pm S.E.M (n = 5) for reversibility study (R). (*P< 0.05, **P<0.01) vs. 800mg/kg of *calotropis procera* extract /Paracetamol); (^aP < 0.05, ^{aaa}P< 0.001) vs. Livolin; (^bP<0.05, ^{bb}P<0.01, ^{bbb} P<0.001) vs. distilled water/ paracetamol (1-way ANOVA followed by Dunnett's multiple comparison test).

The liver was excised from the animals and weighed; it was thereafter separately prepared for biochemical assay by rinsing in cold 0.15% KCl and stored in a sample bottle. Also, the specimens for histopathology were fixed in 10 % formalin.

Assessment of oxidative stress

Preparation of tissue antioxidant

The liver samples were rinsed with ice cold distilled water, followed by KCl solution (0.1%) and immediately stored at -20 °C until time for biochemical analysis. One gram of liver tissue homogenized in 10 ml ice-cold Tris-hydrochloride buffer was centrifuged and used for determination of lipid peroxidation (LPO), by measuring the release of malondialdehyde (MDA) [22] as well as the estimation of reduced glutathione enzyme (GSH) [23] SOD, and catalase [24,25].

Determination of key liver function biochemical markers

The serum was used to assay liver function biochemical markers including ALT, AST, ALP, albumin, total protein, cholesterol, and triglyceride using standard procedures.

Histopathological Study

The liver samples fixed in 10% formalin were processed for histopathology using standard methods [26, 27].

RESULTS

Paracetamol at 150 mg/kg caused significant (P<0.001) reductions in the levels of SOD, CAT and a significant (P<0.001) increase in malondialdehyde in rats when compared with negative control (distilled water). However, administration of Vitamin C, CAP and livolin significantly (P<0.001) reversed the effects of paracetamol on SOD, MDA and CAT (Table 1); the activity of the herbal drug compared effectively with livolin and Vitamin C, which was the same trend in the reversibility study.

On the other hand, there was no significant increase in the levels of Aspartate aminotransferase (AST), Alanine transaminase (ALT), cholesterol and Albumin (ALB) in paracetamol treated rats when compared with the negative control (distilled water) and the trend was sustained two weeks after drug withdrawal. However, the histopathologic study revealed there was damage to the liver of the rats treated with paracetamol compared to negative control (distilled water), while Vitamin C and different doses of plant extract rendered protection against paracetamol-induced toxicity. Livolin did not protect the organ (liver) from the toxicity induced by paracetamol as seen in the histopathology result **Table 3**. The effect of induced toxicity was partially reversed two weeks after drug withdrawal.

DISCUSSION

The present study was designed to explore the hepatoprotective effect of CAP in PCM-induced liver damage. Paracetamol is normally eliminated mainly as sulfate and glucuronide, but about 5% of the paracetamol is bioactivated by hepatic cytochrome P-450 to form a highly reactive and toxic metabolite N-acetyl-p-benzoquinone imine (NAPQI). The latter compound is normally detoxified by conjugation with reduced glutathione (GSH) to form mercaptopuric acid, which is excreted in the urine. Toxic overdose of PCM depletes hepatic GSH content so that free NAPQI binds covalently to cellular mitochondrial fatty acid β -oxidation and results in massive necrosis and apoptosis of hepatocytes [28, 29].

Liver damage is always associated with cellular necrosis, increase in tissue lipid peroxidation and depletion in the tissue GSH levels. In addition, serum levels of many biochemical markers like triglycerides, cholesterol, bilirubin, alkaline phosphatase, are elevated [30, 31].

In this study, PCM significantly (P<0.001) reduced the levels of SOD, CAT and significantly (P<0.001) increased the level of MDA, while the levels of serum biochemical parameters (ALT, ALB, AST, ALP, total protein and triglycerides) were insignificantly (P>0.05) increased compared to control group. The hepatotoxic effect of PCM was significantly (p<0.001) reversed by Vitamin C and the three doses of plant extract; the effect which persisted even after cessation of therapy. The hepatoprotective property of the leaf of CAP as recorded in the present study is in congruence with the reports of Setty *et al.*, 2007 and Chavda *et al.*, 2010, [32, 33] who reported a similar observation on the hydro-ethanolic extract of the flower and methanol extract of the root bark respectively on CCl₄-induced hepatotoxicity. While the herbal drug demonstrated antioxidant activity at the moderate dose of 150 mg/kg, high doses of 400 mg/kg and 800 mg/kg recorded pro-oxidant activity as shown by the histopathological study, where necrosis and inflammation were recorded. The latter observation may be due to presence of Vitamin C and E in the plant extract as established through the HPLC result (unpublished). Vitamin C has both antioxidant and pro-oxidant property [34, 36], while Vitamin E is best known for its antioxidant function [37]. The plant extract recorded superoxide scavenging activity, which suggests that it could also possibly protect the liver from PCM injury through activity on antioxidant enzymes, which prevents formation of free radicals and consequently inhibits lipid peroxidation. Thus, the hepatoprotection of the plant as recorded at moderate dose level, may be via antioxidation. Phytochemical screening revealed the presence of flavonoids in the herbal preparation; polyphenolic compounds such as flavonoids can protect the cells against emptying reduced glutathione via increasing the capability of antioxidant enzymes (such as CAT, SOD and glutathione peroxidase). Research showed that flavonoids, which act as antioxidant, free radical scavenging and antilipoperoxidant agents, are helpful for hepatoprotection. Furthermore, these compounds with antioxidant properties can counteract free

radicals in the environment and therefore avoid their destructive effects [38, 39]. Also identified in the extract of CAP are some elemental minerals such as zinc and nickel which also exert antioxidant effect. Furthermore, the DPPH

scavenging activity of the plant extract, which was recorded as 61.02/100 μg , being equivalent to 62.66% and 65% scavenging activity of Vitamin C and Garlic acid

TABLE 2: EFFECT OF AQUEOUS EXTRACT OF *CALOTROPIS PROCERA* ON SERUM BIOCHEMICAL PARAMETERS.

GROUP	AST (IU/L)	ALT(IU/L)	ALB(IU/L)	T.PROTEIN(IU/L)	CHOLESTEROL (mmol/L)	TRIG (mmol/L)	ALP(IU/L)
Distilled water + Distilled water (10ml/kg)	104.48 \pm 8.27	51.34 \pm 3.58	42.50 \pm 2.00	80.19 \pm 2.90 ^{xyzp}	2.40 \pm 0.14	0.98 \pm 0.18	265 \pm 35.74
Distilled water (10ml/kg) + Paracetamol (150mg/kg)	118.94 \pm 21.94	69.60 \pm 18.10	45.52 \pm 1.31 ^β	84.03 \pm 0.71 ^{xy}	2.46 \pm 0.19	0.86 \pm 0.14	158.83 \pm 7.26 ^α
Vitamin C (200 mg/kg) + Paracetamol (150mg/kg)	133.64 \pm 7.31	54.74 \pm 5.66	43.20 \pm 1.36	73.13 \pm 0.91 ^{*** α αβ}	2.56 \pm 0.16	0.74 \pm 0.04	222.40 \pm 19.96
Livolin(45mg/kg) + Paracetamol(150mg/kg)	97.20 \pm 16.46	53.30 \pm 16.46	38.22 \pm 4.51 ^α	80.19 \pm 2.90 ^{xy}	2.76 \pm 0.22	1.14 \pm 0.44	223.30 \pm 35.74
150mg/kg of plant extract + Paracetamol (150mg/kg)	119.50 \pm 14.42	56.96 \pm 3.40	41.44 \pm 1.61	41.44 \pm 1.61 ^{**}	2.28 \pm 0.05	0.85 \pm 0.14	275.05 \pm 29.20
400mg/kg of plant extract + Paracetamol (150mg/kg)	235.68 \pm 85.2 ^{αββxy}	54.48 \pm 3.64	44.02 \pm 2.78	44.02 \pm 2.78 ^{xyzp}	2.60 \pm 0.19	0.68 \pm 0.06	267.81 \pm 58.00
800mg/kg of plant extract + Paracetamol (150mg/kg)	102.78 \pm 7.92	46.78 \pm 2.22	43.72 \pm 1.36	43.72 \pm 1.36 ^{xy}	2.58 \pm 0.28	0.83 \pm 0.17	179.11 \pm 16.18
Livolin (45mg/kg) + Paracetamol (150mg/kg) R	192.15 \pm 11.71 [*]	17.33 \pm 7.75	42.80 \pm 3.66	82.73 \pm 2.22	1.44 \pm 0.09	0.70 \pm 0.04	182.18 \pm 7.70
Distilled water (10ml/kg) + Paracetamol (150mg/kg) R	134.42 \pm 35.18	37.16 \pm 9.09	28.66 \pm 5.85	61.28 \pm 14.56	1.25 \pm 0.30	0.72 \pm 0.11	122.90 \pm 30.23
800mg/kg of the plant extract+Paracetamol (150mg/kg) R	88.70 \pm 26.90 ^c	54.76 \pm 13.32	33.10 \pm 7.48	61.46 \pm 14.42	16.24 \pm 15.34	0.49 \pm 0.14	177.94 \pm 42.90

Data are expressed as mean \pm S.E.M (n=5). (*P<0.05, **P<0.01, ***P<0.001) vs. control; (^αP<0.05, ^{αα}P<0.01, ^{ααα}P<0.001) vs. paracetamol; (^βP<0.05, ^{ββ}P<0.01, ^{βββ}P<0.001) vs. livolin; (^γP<0.05, ^{γγ}P<0.01, ^{γγγ}P<0.001) vs. Vitamin C (1-way ANOVA followed by Dunnett's multiple comparison test).

Data are expressed mean \pm S.E.M (n = 5). (*P< 0.05) vs. 800mg/kg of *calotropis procera* extract /Paracetamol); (^αP < 0.05) vs. Livolin/ paracetamol ; (^βP<0.05) vs. distilled water/ paracetamol for reversibility study. (1-way ANOVA followed by Dunnett's multiple comparison test) respectively, while the total reducing power of the plant

extract was 0.541/100 μg , which was 54.81% and 58.99% of Vitamin C and Garlic acid respectively. All these properties could be suggested to contribute to the hepatoprotective activity of the plant extract.

TABLE 3: HISTOPATHOLOGICAL ASSESSEMENT OF DRUG-EXPOSED RAT LIVER.

TREATMENT	OBSERVATION	INTERPRETATION
Distilled water + Distilled water (10ml/kg)	Normal liver	Hepatocytes arranged as plates radiating away from the central vein to portal tracts.
Distilled water (10ml/kg)+ Paracetamol(150mg/kg)	Normal architecture, moderate necrofilament, mild congestion, no fibrosis and chronic hepatitis.	Presence of inflammatory cells in the portal tract with the extension into the hepatic lobules. Presence of plasma cells in the portal tracts or liver lobules.
Vitamin C (200mg/kg)+ Paracetamol (150mg/kg)	Normal architecture, no necrofilament, no congestion and no fibrosis.	Hepatocytes arranged as plates radiating away from the central vein to portal tracts.
Livolin(45mg/kg) + Paracetamol(150mg/kg)	Normal architecture, moderate necrofilament, mild congestion, chronic hepatitis and no fibrosis.	Presence of inflammatory cells in the portal tract with the extension into the hepatic lobules. Presence of plasma cells in the portal tracts or liver lobules.
150mg/kg of plant extract + Paracetamol (150mg/kg)	Normal liver	Hepatocytes arranged as plates radiating away from the central vein to portal tracts.
400mg/kg of plant extract + Paracetamol (150mg/kg)	Normal architecture, mild necrofilament, severe congestion and no fibrosis.	Presence of inflammatory cells in the portal tract with the extension into the hepatic lobules.
800mg/kg of plant extract + Paracetamol (150mg/kg)	Normal architecture, moderate necrofilament, mild congestion, chronic hepatitis and no fibrosis.	Presence of inflammatory cells in the portal tract with the extension into the hepatic lobules. Presence of plasma cells in the portal tracts or liver lobules.
Livolin (45mg/kg) + Paracetamol (150mg/kg) R	Moderate necroinflammation, chronic hepatitis, micro and macrovesicular cytoplasmic inclusions	Presence of plasma cells in the portal tracts or liver lobules. Frosted appearance of the hepatocytes due to intracellular accumulation of material. Presence of inflammatory cells in the portal tract with the extension into the hepatic lobules.
Distilled water (10ml/kg)+ Paracetamol (150mg/kg) R	Moderate necroinflammation, chronic hepatitis, micro and macrovesicular cytoplasmic inclusions	Frosted appearance of the hepatocytes due to intracellular accumulation of material. Presence of inflammatory cells in the portal tract with the extension into the hepatic lobules.
800mg/kg of the plant extract+Paracetamol(150mg/kg) R	Only mild portal inflammation, fairly clean liver and cytoplasmic inclusion.	Frosted appearance of the hepatocytes due to intracellular accumulation of material.

Reversibility study after two weeks of cessation of treatment (R).

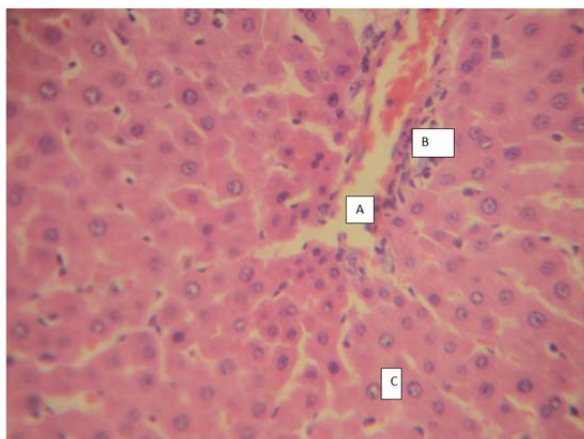


FIGURE 1: Rat's liver (Normal) exposed to distilled water for 14 day (x 400).

- A: Hepatic sinusoids (normal)
- B: Portal tract (normal)
- C: Hepatocytes (normal)

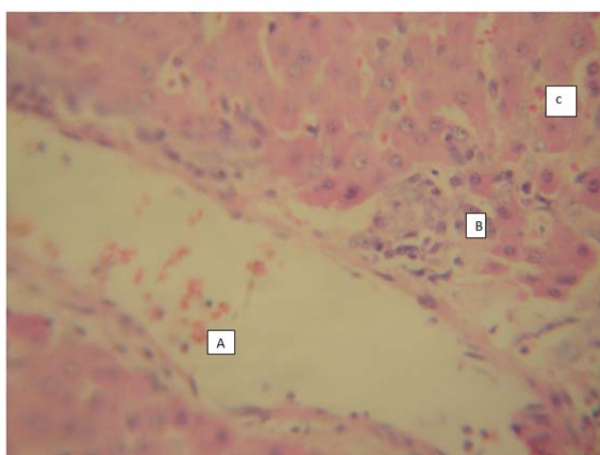


FIGURE 2: Rat's liver (Abnormal) exposed to distilled water (10ml/kg) and paracetamol (150mg/kg) for 14 days (x 400).

- A: Congestion in vesicles (Chronic hepatitis and necroinflammation as indicated by presence of plasma cells in the liver tissue).
- B: Necroinflammation (Plasma cells and lymphocytes in the tissue).
- C: Congestion (Red blood cell in the liver sinusoid).

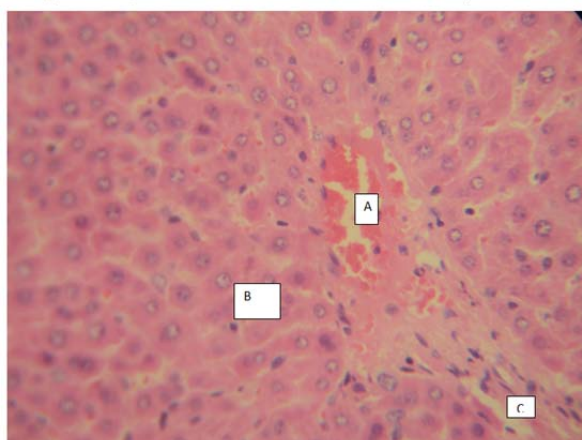


FIGURE 3: Rat's liver (Normal) exposed to Vitamin C (200 mg/kg) and paracetamol (150 mg/kg) for 14 days (x 400).

- A: Hepatic sinusoids (Normal)
- B: Hepatocytes (Normal)
- C: Portal tract (Normal)

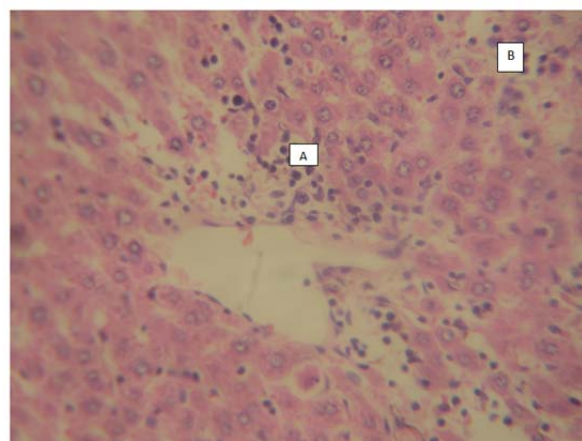


FIGURE 4: Rat's liver (Abnormal) exposed to paracetamol (150mg/kg) and Livolin (45 mg/kg) for 14 days (x400)

- A: Necroinflammation/chronic hepatitis (Plasma cells within portal tract)
- B: Severe necroinflammation/chronic hepatitis (plasma cells within the hepatic lobule)

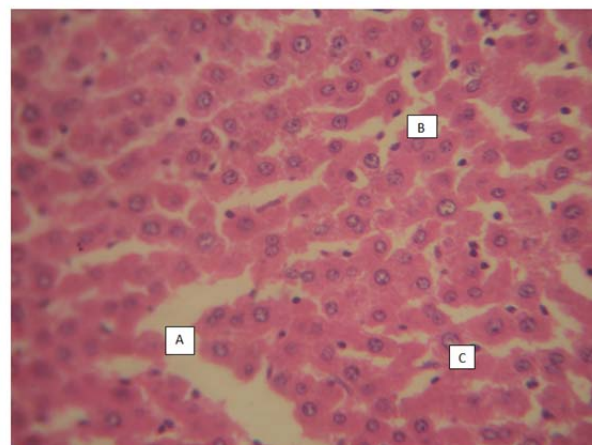


FIGURE 5: Rat's liver (Normal) exposed to aqueous leaf extract of *Calotropis procera* (150mg/kg) and paracetamol (150mg/kg) for 14 days (x400).

- A: Hepatic sinusoid (normal)
- B: Portal tract (Normal)
- C: Hepatocytes (Normal)

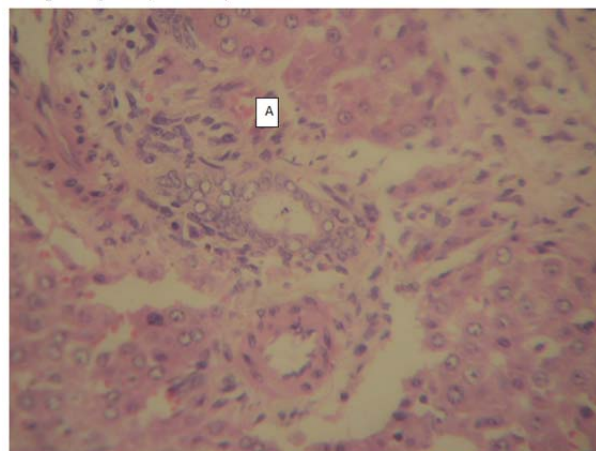


FIGURE 6: Liver of rat exposed to aqueous leaf extract of *Calotropis procera* (400mg/kg) and paracetamol (150mg/kg) for 14 days (x400).

- A: Severe congestion

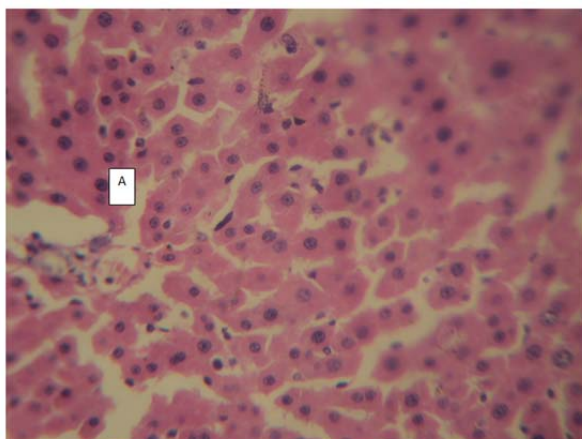


FIGURE 7: Liver of rat exposed to aqueous leaf extract of *Calotropis procera* (800mg/kg) and paracetamol (150mg/kg) for 14 days (x400).

A: Cytoplasmic inclusion

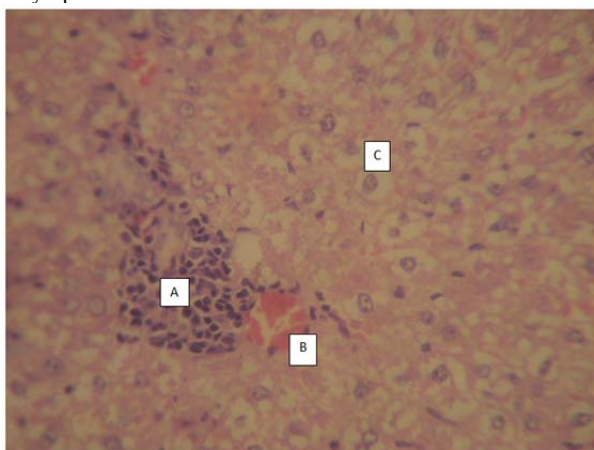


FIGURE 8: Liver (2 weeks after withdrawal of treatment) of rat exposed to paracetamol (150mg/kg) and livolin (45mg/kg) for 14 days (x400).

A: Focal accumulation of plasma cells and Lymphocytes
 B: Congested blood vessels
 C: Hepatocytes with cytoplasmic inclusion

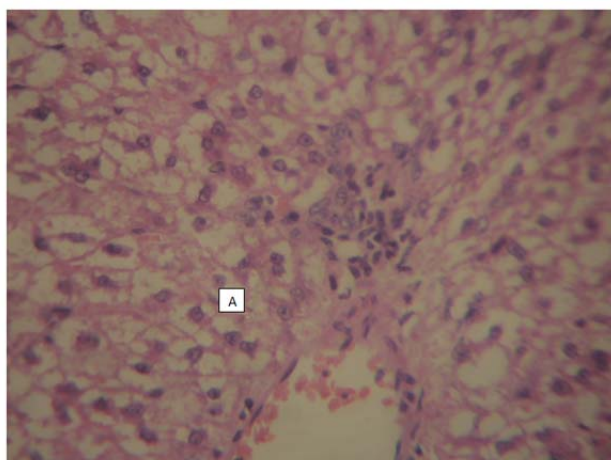


FIGURE 9: Rat's liver (2 weeks after withdrawal of drug) exposed to aqueous leaf extract of *Calotropis procera* (800mg/kg) and paracetamol (150mg/kg) for 14 days (x400).

A: Hepatocytes with cytoplasmic inclusion /Vacuole

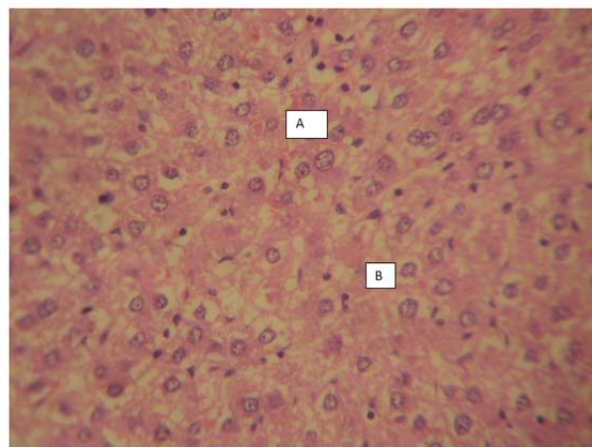


FIGURE 10: Liver (2 weeks after cessation of treatment) of rat exposed to paracetamol (150mg/kg) and distilled water for 14 days (x400).

A: Mild congested blood Vessels
 B: Hepatocyte with cytoplasmic inclusion/vacuole

CONCLUSION

The present work has shown that the aqueous extract of CAP is hepatoprotective; the effect which may be due to its antioxidant property. However, high doses may be deleterious consequent to pro-oxidation. CAP in moderate doses compared effectively with the standard drugs Vitamin C and livolin used in the study, however its relative safety and high pH of 8.4, could also of immense benefit.

ACKNOWLEDGEMENTS

The authors wish to thank the staff of the Department of Biochemistry and Morbid Anatomy of the College of Medicine, University of Lagos, Lagos-Nigeria, for their technical assistance.

REFERENCES

- [1] Setty, S. R., Quereshi, A. A., Viswanath Swamy, A. H. M., Tushar, P., Prakash, T., Prabhu K., Gouda, A. V., *Fitoterapia* 2007, 78: 451-454.
- [2] Valko, M., Leibfritz, D., Moncol, M., Cronin M., Mazur, M., Tesler J., *Int. J. Biochem. Cell Biol.* 2007, 39, 44-84.
- [3] Friedman, S. E., Grendell, J. H., Mc Quaid Kenneth, R., Current diagnosis and treatment in gastroenterology. New York: Lang Medical Books/Mc Graw-Hill, 2003, pp. 664-679.
- [4] Mc Nally, P.F., *GI/Liver Secrets: With Student Consult Access.* Saint Louis: CV Mosby 2006.
- [5] Ostapowicz, G, Fontana, R. J., Schiodt, F. V., et al., *Ann. Int. Med.* 2002, 137 (12), 947-954.
- [6] Keefe, E. B., Friedman, L. M., *Handbook of liver diseases.* Edinburgh: Churchill Livingstone, 2004, pp. 104-123.
- [7] Gagliano N., Grizzi, F., Annoni, G., et al., *Dig. Dis. Sci.* 2007, 25, 118-123.
- [8] Dietmar, B., *Calotropis procera* on Fuerteventura. Technical University Braunschweig, Germany, 2005, pp. 1-7.
- [9] Ahmed, K. K. M., Rana, A. C., Dixit, V. K., *Pharmacog. Maga.* 2005, 1, 48-52.
- [10] Mascolo N., Jain, R., Jain, S. C., Capasso, F., *J. Ethnopharmacol.* 1989, 27, 129-140.
- [11] Markork, M. K., Bekkouche, M., Larhsini, M. B., Lazrek, H. B., Jana, M., *J. Ethnopharmacol.* 2000, 73, 293-297.
- [12] Rasik, A. M., Raghbir, R., Gupta, A., Shukla A., Dubey, M. P., *J. Ethnopharmacol.* 1999, 68, 261-266.
- [13] Dewan, S., Sangraula, H., Kumar, V. L., *J. Ethnopharmacol.* 2000, 73, 307-311.
- [14] Kamath, J. V., Rana, A. C., *Fitoterapia*, 2005, 73, 111-115.

- [15] Basu A., Sen, T., Pal, S., Muscalo, N., Capasso, F., Choudhuri A. K. N., *Phytother. Res.* 1997, 11, 163.
- [16] Zimmerman, M., *Pain.* 1983, 16, 109–110.
- [17] Yen, G. C., Chen, H. Y., *J. Agric. Food Chem.* 1995, 46, 849-854.
- [18] Aiyegoro O. A., Okoh A. I., *Int. J. Mol. Sci.* 2009, 10 (11), 4990-5001.
- [19] Liyana-Pathirana, C. M., Shahidi, F., *J. Agric. Food Chem.* 2005, 53, 2433-2440.
- [20] Evans, W. C., *Pharmacognosy, British library publication*, 2002, 414-418.
- [21] Chattopadhyay, R. R., *J. Ethnopharmacol.* 2003, 89, 217.
- [22] Slater, T. F., Sawyer, B. C., *Biochem Journal*, 1971, 123, 805–814.
- [23] Moron, M. S., Depierre, J. W., Mannervik, B., *Biochimica et Biophysica ACTA*, 1979, 582,67–68.
- [24] Mishra, H. P., Fridovich, I., *J. Biol. Chem.*, 1972, 247, 3170–3175.
- [25] Aebi, H., In: Catalase in Vitro, Methods in Enzymology, Colowick S.P, Kaplan N.O, editors. Vol. 105. Florida: Acad. Press; 1984. pp. 114–121.
- [26] Galighor, A. E., Kozloff, E. N., *Essentials of practical micro technique.* 2 Ed. New York, Lea and Febiger, 1976.
- [27] Luna, L. G., *Manual of Histologic Staining Methods of the Armed Forces Institute of Pathology*, N.Y., McGraw-Hill, 1968, 114-115.
- [28] Chen, C., Krausz, K. W., Shah, Y. M., Idle, J. R., Gonzalez, F. J., et al., *Toxicol.* 2009, 22, 699-707.
- [29] Bhattacharyya, S., Pence, L., Beger, R. D., Chaudhuri, S., McCullough, S. S., Kan Y., Simpson, P. M., Hennings, L., Hinson, J. A., James, L. P., et al., *Metabolites.* 2013, 3, 602-622.
- [30] Mascolo, N., Sharma, R., Jain, S. C., Capasso, F., *J. Ethnopharmacol.* 1998, 22, 211.
- [31] Anil, U. T., Sanjay, J. S., Manisha, P. S., Nehal, H. G., *Pharmacog. Res.* 2012, 4 (1), 50-56.
- [32] Chavda, R., Vadalia, K. R., Gokani, R., *Int. J. Phar.* 2010, 6(6), 937-943.
- [33] McGregor, G. P., Biesalski, H. K., Current opinion in clinical nutrition and metabolic care. 2006, 9 (6), 697-703.
- [34] Bell, E. F., *Am. J. Clin. Nutr.* 1987, 46 (1 Suppl), 183-186.
- [35] Janbaz, K. H., Saeed, S. A., Gilani, A. H., *Fitoterapia.* 2002, 73, 557-563.
- [36] Samani, M. A., Farkhad, N. K., Azimi, N., Fasihi, A., Ahandani, E. A., Kopaei, M. R., *Asian Pacific J. Trop. Biomed.* 2015, 5 (2), 146-157.