

Amelogenesis Imperfecta: A Review of the Literature

Dr Roma M,

Assistant Professor,

*Department of Conservative Dentistry and Endodontics,
Manipal College of Dental Sciences, Mangalore.
(Manipal University)Mangalore*

Dr Shreya Hegde,

Reader,

*Department of Conservative Dentistry and Endodontics
Manipal College of Dental Sciences, Mangalore.
(Manipal University)Mangalore*

Abstract

Amelogenesis imperfecta (AI) is a hereditary group of disorder that causes disturbance in enamel formation resulting in developmental alterations of mineralization. Restoration of the dentition poses a great challenge when all the teeth are severely affected. The treatment opportunities for these patients may help in refining their lifestyle. The total treatment modality aims to relieve the pain and sensitivity, and preserving the tooth structure as much as possible. This article discusses both the structural and aesthetic rehabilitation of a patient with different types of AI.

Key words: Amelogenesis Imperfecta, Dental anomalies, Full mouth rehabilitation, Occlusal wear

INTRODUCTION

Amelogenesis imperfecta is a group of inherent disease that exhibit quantitative or qualitative enamel defect in the absence of systemic complication.[1] Hereditary brown enamel, hereditary enamel dysplasia, hereditary brown opalescent teeth are the other terminologies used for AI. The prevalence varies from 1:700 to 1:14 000, according to the populations studied.[2] AI affects the entire ectodermal component. Amelogenesis Imperfecta trait can be either autosomal dominant, autosomal recessive or X- linked mode of inheritance.[3]

AI affects both the primary and permanent dentitions. In the teeth affected by AI, the dentin and roots appear normal. Based on phenotypic characteristics and mode of inheritance, the classifications of AI are propounded. The most commonly used classification was proposed by Witkop in 1988, which was later revised by Nusier in 2004. [3] Depending upon enamel appearance, structural and developmental defects, AI is classified into 4 patterns: hypoplastic, hypomaturation, hypocalcified, and hypomaturation-hypoplastic .[1]

The restoration of the defects created by AI improves the esthetic and functional concerns of the patient. Treatment Planning of these cases involves an interdisciplinary approach to evaluate, diagnose, and resolve esthetic problems using a combination of periodontal, prosthodontic, and restorative treatment.[4] This review demonstrates the various types of Amelogenesis Imperfecta, their characteristics and the various treatment modalities associated with them.

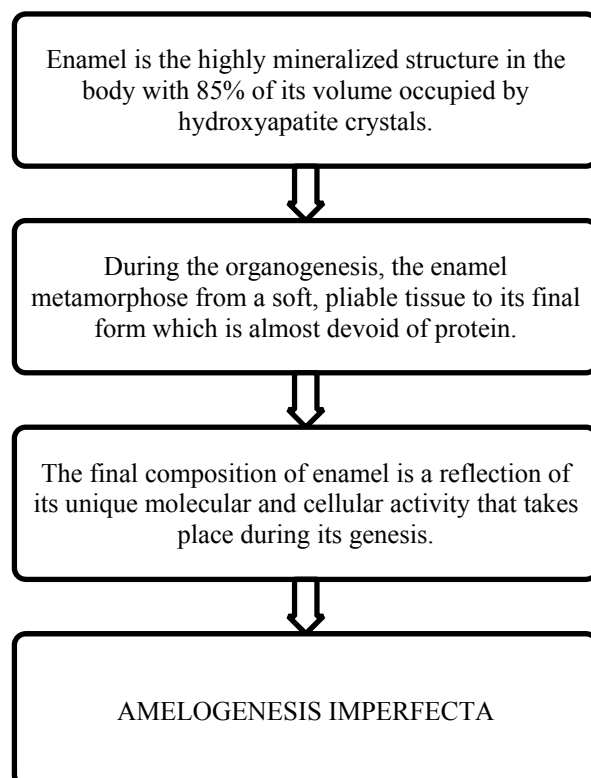
Definition:

AI represents a group of conditions, genomic in origin, which affect the structure and clinical appearance of the enamel of all or nearly all the teeth in a more or less equal manner, and which may be associated with morphologic or biochemical changes elsewhere in the body.[2]

Etiology

Genetic, Febrile illness or Vitamin Deficiency, Local infection or Trauma, Fluoride Ingestion, Congenital syphilis, Birth defects or idiopathic factors.[5]

Pathogenesis [4]



Classification And General Features [5]

Table 1: Clinical and Radiographic appearance		
Hypoplastic form Reduction in the thickness of enamel matrix with normal mineralization	Hypomaturation form Defect in the mineralization process with normal matrix formation	Hypocalcified form Defect in the quality of the mineralization process with normal quantity of matrix formation
Clinical Appearance		
Reduced thickness of enamel	Normal thickness of enamel	Normal thickness of enamel with loss of translucency
Enamel appears normal and less prone to attrition	Enamel is hypomineralized and prone to attrition	Enamel is hypomineralized and exhibits a soft cheesy consistency. Easily broken down.
The color appears normal with translucency to a yellow to dark brown color depending on the thickness of enamel and dentin	Color may be affected by staining from the oral environment. Mottled appearance to yellow-brown or red-brown discoloration	Color may be affected by staining from the oral environment. Teeth appear more dark
Reduction in tooth size		
Rough, irregular or pitted enamel		
Radiographic appearance		
Enamel and dentin appears normal	Enamel has similar radiodensity as dentin	Enamel is less radiopaque than dentin

Hypoplastic AI: [4, 6,7]

Hypoplastic AI subtypes are characterized by the defective formation of enamel which is the primary feature. The hypoplastic types can be characterized by enamel that is pitted, has grooves or furrows, has large areas of missing, or enamel that is very thin over the entire tooth crown. Quantitative defects are seen when the enamel does not form in normal thickness either due to local or general factors. Clinically, the crown size varies from small to normal and small teeth may lack proximal contacts. The colour varies from normal to opaque white – yellow brown. Enamel may be rough, smooth, pitted, grooved, locally hypoplastic or the complete tooth crown may appear with thin enamel.

Hypomaturation AI: [5,7]

In this type, qualitative defect of the enamel is seen where the enamel is not sufficiently mineralized. The teeth appear normal morphologically at the time of eruption, but eventually chip away posteruptively, especially in the occlusal areas. Clinically, the colour of teeth here varies from creamy opaque to marked yellow/brown. The surface of the teeth appear soft and rough leading to sensitivity due to dentinal exposure. Open bite malocclusion is a common feature. The enamel thickness is normal but often chips off and abrades away easily. Radiographically, there appears to be reduced differentiation between enamel and dentin which may be difficult to verify. Enamel has contrast

similar to or greater than dentin, unerupted crowns have normal morphology radiographically.

Hypocalcified AI: [7,8]

Qualitative defect occurs when the enamel is insufficiently mineralized and soft. In comparison with hypomaturation type, the mineralization in this type is markedly reduced. Clinically, the crowns of the teeth in such cases appear to be opaque white to yellow-brown, soft rough enamel surface, dental sensitivity and very poor aesthetics. Due to severe hypomineralization, there may be early loss of enamel. The thickness of enamel appears to be normal at eruption that often chips and but, tends to abrade easily post eruptively. There may be delayed eruption of teeth. An anterior open bite of skeletal origin may be seen. Accumulation of a large amount of supragingival calculus is evident.

Hypomaturation-Hypoplastic with Taurodontism: [6,7]

Clinically, the crown appears to be white/yellow-brown mottled. The teeth appear smaller than normal and they lack proximal contacts. In these cases, the enamel thickness is drastically reduced. The crowns show pitting and tend to have hypo mineralized areas. Radiographically, the enamel contrast is normal to slightly greater than dentin, and shows large or bulbous pulp chambers which appear taurodontic

CONCLUSION

One of the greatest challenges faced by the clinician is the total rehabilitation with Amelogenesis Imperfecta. The enamel formation is affected in multiple ways. The color, thickness and resistance of enamel is reduced to a great extent. Both deciduous and permanent dentition are affected with AI, but more commonly seen in permanent teeth. [6] Various studies have revealed certain oral complaints which are associated with AI are unaesthetic appearance, extensive loss of tooth structure, dentinal sensitivity, and loss of vertical dimension.[7, 8]

The treatment plan with respect to AI patients usually involves various factors like age, socio-economic status and severity of the condition. A multidisciplinary treatment plan should be carried out for indicated situation while implementing careful evaluation, case selection, treatment planning and precise surgical procedures in order to meet the aesthetic and functional demands of the patient with the modern technology.

Several authors[10-12] prefer full porcelain restorations as the treatment modality of their patient with AI. However, the advances in the field of esthetic dentistry, especially in bonding to dentin, help practitioners to restore function and esthetics to an acceptable level.[13] In cases of AI, multidisciplinary approach is the treatment of choice for clinical success.

REFERENCES

1. Saraswathi V Naik, Ghousia S, Shashibushan KK, Poornima S. Amelogenesis Imperfecta- A Case Report. *J Oral Health Res.* 2011;2(4):106-110.
2. Crawford PJ, Aldred M, Bloch-Zupan A. Amelogenesis imperfecta. *Orphanet J Rare Dis.* 2007;2:17-27.
3. Mayur Chaudary, Shweta Dixit, Asha Singh, Sanket Kunte. "Amelogenesis imperfecta" – Report of a case and review of literature. *J Oral Maxillofac Pathol* 2009;13(2):70-7.
4. Emin Murat Canger, Peruze Celenk, Murat Yenisey, Selcen Zeynep Odyakmaz. Amelogenesis Imperfecta, Hypopalstic Type Associated with some Dental Abnormalities: A Case Report. *Braz Dent J* 2010;21(2):170-174.
5. Witkop C. J. Amelogenesis imperfecta, dentinogenesis imperfecta and dentin dysplasia revisited: problems in classification. *Jr. J Oral Pathol.* 1988 Nov;17(9-10):547-53.
6. M. Patel, S. T McDonnell, S. Iram, M.F. W-Y. Chan. Amelogenesis Imperfecta- lifelong management. *Restorative management of the adult patient. British Dental Journal* 2013;215(9):449-457.
7. Gemimaa Hemagaran ,Arvind. M. Amelogenesis Imperfecta - Literature Review. *IOSR Journal of Dental and Medical Sciences* 2014;13(1): 48-51.
8. Santos MCLG, Line SRP. The genetics of amelogenesis imperfecta: a review of the literature. *J Appl Oral Sci* 2005;13:212-217.
9. Peter J M Crawford, Michael Aldred, Agnes Bloch-Zupan. Amelogenesis Imperfecta: Review. *Orphanet Journal of Rare Diseases*2007;1-17.
10. Winter GB. Amelogenesis imperfecta with enamel opacities and taurodontism: An alternative diagnosis for 'idiopathic dental fluorosis'. *Br Dent J* 1996;181:167-72.
11. Paine ML, White SN, Luo W, Fong H, Sarikaya M, Snead ML. Regulated expression dictates enamel structure and tooth function (review) *Matrix Biol.* 2001;20:273–92.
12. Sockalingam S. Dental rehabilitation of amelogenesis imperfecta using thermoformed templates. *J Indian Soc Pedod Prev Dent.* 2011;29:53–61.
13. S. K. Lanning, T. C. Waldrop, J. C. Gunsolley, and J. G. Maynard, "Surgical crown lengthening: evaluation of the biological width," *Journal of Periodontology*, vol. 74, no. 4, pp. 468–474, 2003.
14. Gökçe K, Canpolat C, Özel E. Restoring function and esthetics in a patient with amelogenesis imperfecta: a case report. *J Contemp Dent Pract* 2007;8:90-101.
15. Kostoulas I, Kourtis S, Andritsakis D, Doukoudakis A. Functional and esthetic rehabilitation in amelogenesis imperfecta: a case report. *Quintessence Int* 2005;36:329-338.
16. Ozturk N, Sari Z, Ozturk B. An interdisciplinary approach for restoring function and esthetics in a patient with amelogenesis imperfecta and malocclusion: a clinical report. *J Prosthet Dent* 2004;92:112-115.
17. Şengün A, Özer F. Restoring function and aesthetics in a patient with amelogenesis imperfect: a case report. *Quintessence Int* 2002;33:199-204.
18. Mizrahi B. Combining traditional and adhesive dentistry to reconstruct the excessively worn dentition. *Eur J Esthet Dent* 2008;3(3):270-89.