

Immediate Implants Placement-A Review

K.V.Swathi

Saveetha Dental College, Chennai

Abstract:

A dental implant is a surgical component that interfaces with the bone of the jaw or skull to support a dental prosthesis such as a crown, bridge, denture, facial prosthesis or even can act as an orthodontic anchor. A variable amount of healing time is required for osseointegration before either the dental prosthetic (a tooth, bridge or denture) is attached to the implant or an abutment is placed which will hold a dental prosthetic. There are different approaches to placement of dental implants after tooth extraction. The approaches are immediate post extraction implant placement, delayed immediate post-extraction implant placement (two weeks to three months after extraction), late implantation (three months or more after tooth extraction). Here various clinical cases of immediate implant placements post extraction, their advantages and disadvantages has been reviewed.

Key Words: Immediate implants, Osseointegration, post-extraction

INTRODUCTION:

Placement of implants immediately following extraction has now become an increasingly common strategy to preserve bone and reduce treatment time. On one hand, it shortens treatment time and can improve esthetics because the soft tissue envelope is preserved. (1)

DIAGNOSIS AND TREATMENT PLANNING:

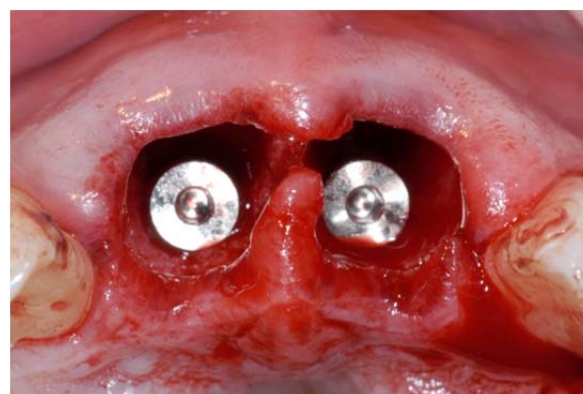
For the long term success of immediate implants, an appropriate diagnosis and treatment plan is to essential. When evaluating a patient for dental implants, thorough medical and dental histories, clinical photographs, study casts, periapical and panoramic radiographs as well as linear tomography or computerised tomography of the proposed implant sites should be considered. The most important step in treatment planning is determining the prognosis of the dentition, and in particular the prognosis of the tooth in question. Crown to root ratio, remaining root length, periodontal attachment level, periodontal attachment level, furcation involvement, periodontal health status of teeth adjacent to the proposed implant site, non restorable caries lesions, root fractures with large endodontic posts etc., should be evaluated. Implants to replace teeth with non vital pulp, fractured at the gingival margin with roots shorter than 13 mm, is often considered as the treatment of choice. (2)

INDICATIONS AND CONTRAINDICATIONS FOR IMMEDIATE IMPLANT PLACEMENT:

The indications for immediate implant placement were based on the ability to attain primary implant stability with an appropriately sized implant in an ideal restorative position. Factors such as soft tissue and bone quantity and quality, as well as the presence of pathology and the condition of adjacent teeth, enter into the decision timing of implant placement. In cases of patient with thin biotype (thin scalloped gingival) wherein the buccal plate is lost or

anticipated to resorb, aesthetics is a primary consideration as to implant timing. If immediate implant placement is performed, a barrier membrane and supporting graft are required, which eventually increases the risk for more complications, leading to an unacceptable aesthetic result. Hence a thick biotype (thicker, less scalloped gingival architecture), causes less of a risk of buccal plate resorption, especially where the plate is intact following extraction. These cases present a better indication for immediate implant placement. (3)

In cases in which implant placement is required in a highly aesthetic zone, in a patient with high smile line, immediate implant placement is contraindicated. This is especially when a thin scalloped gingiva is present.



THE RULE OF 5 TRIANGLES:

To achieve excellence when placing immediate implants, there are 5 key aspects to consider during the decision-making process, to help prevent blunders that can lead to difficult esthetic situations. The following are (I) the presence of a buccal plate, (II) primary stability, (III) implant design, (IV) filling of the gap between the buccal plate and the implant, and (V) tissue biotype. An atraumatic extraction should be done to prevent a more pronounced

bone loss. When positioning the implant in an ideal 3D position, the void should always be grafted with biomaterial. It is recommended to compensate soft tissue remodeling, by means of overbuilding buccally with biomaterial or by a soft tissue graft. Provisional crowns can be used in immediately placed implants to maintain soft tissue contours. Implant design is recommended to be self-tapered, so it can favor reaching primary stability.(4)

SOFT TISSUE MANAGEMENT FOR IMMEDIATE IMPLANTS:

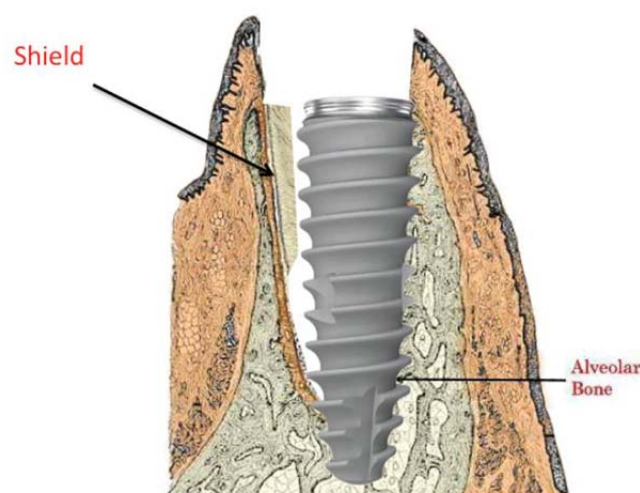
Various surgical techniques have been proposed to achieve primary soft tissue closure with immediate implants. Use of a rotated buccal flap from an adjacent tooth can be used to achieve closure over implants placed at the time of extraction. This procedure can be applied for single or multiple implant sites and can be employed in conjunction with membrane barriers or various grafting materials. The main disadvantage of this technique is the requirement for an adequate width of keratinised mucosa and vestibule depth. Connective tissue graft can be used for the coverage of immediately placed implants. A potential problem is the limitation of donor tissue size. An acellular dermal matrix allograft, gingival grafts can also be used alone or with grafting materials to cover immediately placed implants. The palatal advanced flap or pediculated flap is useful in case of maxillary immediate implant cases. This technique provides adequate tissue mobility and bulk, facilitating a complete, precise and highly predictable coverage of the extraction site in large defect areas, and in case of multiple implants. The main disadvantage of this technique is the prolonged and uncomfortable secondary palatal tissue healing.(5)

When implants are placed into the extraction socket, a partial incongruency would be seen between the outer surface of the socket and bony wall of the socket. This space is known as Jumping distance or critical space. Usage of wider diameter implants instead of bone grafts can be done in such cases for obliteration if the jumping distance.(6)

SOCKET PRESERVATION:

Socket preservation techniques involve minimally traumatic extraction followed by immediate grafting of the extraction sockets using particulate bone graft materials with or without membranes. These socket preservation techniques have been shown to reduce alveolar ridge dimensional changes following extraction. Although socket preservation techniques are beneficial, soft tissue closure and graft containment can be difficulties encountered with these techniques. Socket preservation techniques are beneficial in preserving alveolar hard and soft tissues. When intact or nearly intact extraction sockets are present, an immediate implant placement technique offers the advantages of the socket preservation technique and reduces the time required to achieve a final restoration.(7)

SOCKET SHIELD TECHNIQUE:



Socket shield technique is a method which meets the demands of minimal invasion, tissue preservation, and no need of bone substitute materials.

The application of socket shield technique combined with immediate implant placement for replacing a failing tooth will maintain the ridge shape. The implant-supported prosthesis will function well and healthy peri-implant soft tissue is maintained.(8)

DUAL ZONE TECHNIQUE FOR MANAGEMENT OF IMMEDIATE IMPLANTS:

The dual zone is divided into two regions which are the tissue zone and bone zone. The tissue zone is the labial-palatal dimensional change of the vertical region of tissue defined as ranging from the free gingival margin (0 mm) to the labial crest of bone mid-facially. The bone zone is the tissue apical to the osseous crest. After tooth removal, implant placement, bone grafting, and provisional restoration, the contour of the ridge can change. Dual zone technique can minimize contour change associated with immediate implants especially in the anterior region. This technique allows the indirect removal of excess cement around the final crown to avoid the potential for peri-implantitis due to residual cement left in the implant gingival sulcus.(9)

IMMEDIATE IMPLANT PLACEMENT USING FLAPLESS APPROACH:

The flapless technique provides a minimally invasive approach to extraction with socket grafting or immediate implant placement. Because the interdental papilla remains intact, there is less disruption of blood supply. As a result, there is a greater potential for maintenance of soft tissue volume. In addition, the use of a dense PTFE membrane improves the predictability of immediate implant placement, excluding the requirement for primary closure and resultant disruption of soft tissue architecture.(10)

ADVANTAGES AND DISADVANTAGES OF IMMEDIATE IMPLANT PLACEMENT:

The immediate implant placement, first of all, reduces the number of surgical procedures. This fact is being popular among patients and increases their acceptance, that prefer submit themselves into fewer surgical interventions. According to the clinical way, implants in fresh extraction sites can be placed in the same location as the extracted tooth, minimizing the need for angled abutments and facilitating the positioning of the final restoration. Osseointegration is also more favourable when placing implants immediately following an extraction. Width and height of the alveolar bone are preserved. The procedure keeps contaminants away from the socket. Immediate placement of implants provides better aesthetics for the patient. During the procedure, the bony receptors are preserved by preventing atrophy of the alveolar ridge, preventing recession of the mucosal and gingival tissues. So, generally, it stimulates preservation of gingival aesthetics. A shorter treatment time as well as chair time also offers fewer clinic visits to contribute to the patient's comfort; they don't have to live in a transitional state with or without teeth. The ideal situation for the procedure is where the infection-free, intact socket can be obliterated almost entirely by the implant. (11)

Although immediate implant placement offers many advantages, there are few limitations which include difficulty in maintaining primary stability, inadequate soft tissue coverage, difficulty in preparing the osteotomy due to bur movement (chatter) on the walls of the extraction site, various hindrances during implant placement like tooth ankylosis, fracture of the buccal plate, socket expansion during extraction, or extensive infection etc., (12)

CONCLUSION:

Immediate implant placement following tooth extraction has been found to be a viable and predictable solution to tooth loss. Minimally invasive surgical technique, lesser

chairside and treatment time involved together with minimum post extraction complications, preservation of gingival aesthetics are a boon to the patient. However proper case selection, diagnosis and treatment planning, meticulous post-operative care preceded by a good surgical and prosthetic protocol are very essential for the long term success of the immediate implants.

REFERENCES:

- 1) JORDI Ortega-Martinez et al.(2012)Immediate implants following tooth extraction:A Systematic Review.Med Oral Patol Oral Cir Bucal 1;17(2):e251-61
- 2) Peter Floyd et al.(1999)Dental Implants:Treatment planning for implant restorations.British Dental Journal 187:297-305
- 3) Jay R.Beagle(2013)Indications and contraindications of immediate implant placement.Wiley Online Library.
- 4) Jaime Jimenez Garcia et al.(2014)A New Protocol For Immediate Implants :The Rule Of 5 Triangles:A Case Report.European Association For Osseointegration(pages 4 &5)
- 5) William Becker & Moshe Goldstein(2008)Immediate Implant Placement:Treatment planning and surgical steps for successful outcome.Periodontology 2000,Vol 47:79-89
- 6) Sahitya Sanivarapu et al.(2010)Immediate Implant Placement Following Tooth Extraction:A Clinical And Radiological Evaluation.International Journal Of Oral Implantology And Clinical Research 1(2):67-76
- 7) Jack T.Krauser et al.Immediate Implant Placement And The Socket Seal Classification.<http://www.dentaleconomics.com/>
- 8) Chih-Long Chen et al.(2013)Socket Shield Technique for Ridge Preservation:A Case Report.Journal of Prosthodontics and Implantology Vol 2,Number 2
- 9) Barry K Barteel(2008)Extraction,Immediate Implant Placement and Guided Bone Regeneration using a flapless approach. <https://www.osteogenics.com/media/uploads/.../1231j93p5qbs.pdf>
- 10) Stephen J Chu et al.(2012) The Dual-Zone Therapeutic Concept of Managing Immediate Implant Placement and Provisional Restoration in Anterior Extraction Sockets. <https://www.dentalaegis.com/>
- 11) Immediate implant placement after extraction.<https://www.propdental.es/>
- 12) Koh RU,Rudek I,Wang HL(2010)Immediate implant Placement:Positives and Negatives.Implant Dent 19(2):98-108