

# Comparative Study of Graft Materials Used in Myringoplasty

Dr.D.Sridhara Narayanan<sup>1</sup>, Dr. Vijay kumar B<sup>2</sup> DR. Hari P.M<sup>3</sup>

<sup>1&3</sup> Professor, <sup>2</sup>Senior Resident

Department of Otorhinolaryngology, Sree Balaji Medical College & Hospital,  
Chennai.bharat University Chennai

## Corresponding author

Dr. D. Sridhara Narayanan,  
Professor of ENT,  
Department of Otorhinolaryngology,  
Sree Balaji Medical college & Hospital, Chennai

---

## Abstract

### **Aim:**

Present study was done to compare the hearing improvement and the graft take-up in patients with inactive mucosal type chronic otitis media with central perforation undergoing myringoplasty surgery using either of the two graft materials, temporalis fascia and conchal perichondrium.

### **Materials and methods:**

85 patients were taken for the study and surgery performed in all the 84 patients. All patients were compared post operatively after 3 months for both hearing improvement and graft take-up.

### **Results:**

Air bone gap reduction in the two groups of patients the average reduction of air-borne gap in the group receiving temporalis fascia was 9.68 dB and the average reduction of air-bone gap in the patients receiving conchal perichondrium was 8.41 Db. In this study, temporalis fascia, which is the current gold standard graft material for mringoplasty, achieved the maximum hearing improvement. Also the failure rate of grafts with temporalis fascia was less (7%) compared to conchal perichondrium with a failure rate of 15%

### **Conclusion:**

This study confirms that the temporalis graft is better than cochal perichondrial graft for closure of perforations in inactive mucosal type of chronic otitis media with a central perforation.

The post operative results showed that hearing improvement was better in the study group receiving temporalis fascia as graft material than the group receiving conchal perichondrium. Also the graft failure was less with the study group receiving temporalis fascia than graft take-up was better with remporalis fascia graft than conchal perichondrial graft.

**Key word:** chronic otitis, myringoplasty surgery, temporalis fascia, conchal perichondrium

---

## INTRODUCTION

Myringoplasty is a surgical procedure of closure of tympanic membrane perforation. Myringoplasty surgery involves the use of a graft as a scaffold for the epithelium to grow over the graft and close the perforation. The goal of myringoplasty surgery is to achieve a dry ear by eradicating middle ear disease and also to improve hearing by the closure of tympanic membrane perforation by grafting. The results of myringoplasty are usually measured in terms of success or failure of graft take-up and hearing improvement.

Individuals with benign perforations i.e those with inactive mucosal type of chronic otitis media usually have a very good to excellent chance of obtaining a dry ear and hearing within the normal range following myringoplasty surgery. Such patients may be expected to have 93 to 97% graft take-up and 85 to 90% chance for hearing gain to within 20dB of bone conduction level.

However the success of graft take-up and hearing outcome also depends on the type of the grafts used for myringoplasty. Presently the most commonly used graft

material for the repair of tympanic membrane perforation is temporalis fascia. Another grafting material that is more frequently used is the areolar tissue obtained from the area overlying the temporalis fascia. This graft has the advantage of having either minimal or no bleeding during removal due to its location in the avascular plane, it is easier to handle during graft placement and case of failure the temporalis fascia is still available for use.

In this study the two autologous graft namely temporalis fascia and perichondrium (conchal), both of which are available close to the operating site. The aim of this study is to compare graft take up and hearing restoration by myringoplasty in patients with inactive mucosal type chronic otitis media receiving either the temporalis fascia or the conchal perichondrium graft.

## MATERIALS AND METHODS

The current study was conducted at sree Balaji Medical College, Department of ENT from april 2009 to april 2011. The study population was the patients who had come to the department with inactive mucosal type chronic otitis media

with a dry central perforation was taken up for the study. On total 85 patients were included in the study. Selected patients for the study were randomly divided alternatively into one of the two study group, i.e receiving either temporalis fascia graft or conchal perichondrium graft, alternatively. The investigations carried out to assess the patients for the study includes examination under microscope, pure tone audiogram, diagnostic nasal endoscopy, Xray paranasal sinuses, chest X-ray, routine blood investigations, ECG.

Examination under microscope is done to confirm the diagnosis and the inactive of chronic suppurative otitis media by observing the mucosa of the middle ear and the presence of any discharge or any retraction pocket.

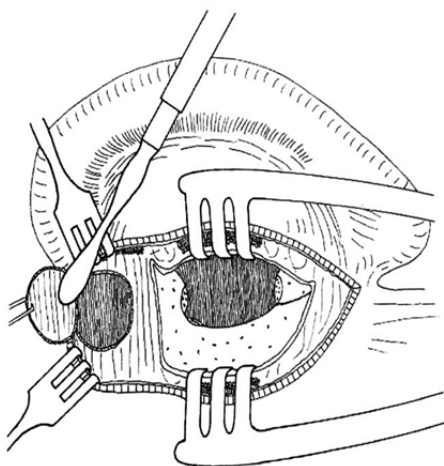
Pure tone audiogram was done to establish the pre operative air –bone gap and to rule out any sensori-neural hearing loss.

Diagnostic nasal endoscopy was done for all cases to out ant focus of sepsis in the para-nasal sinuses and nasopharynx. X-ray para-nasal sinuses to rule out any coexistent sinusitis. X-ray mastoid was done to know the type of mastoid pneumatization. Chest X-ray, routine blood investigations and ECG were carried out in all patients for anaesthetic assessment.

#### PROCEDURE

All patients were done under GA. All operative procedure were done via post aural approach and using operative microscope. For all the cases the same operative procedure was followed. After intubation of the patient the head of the patient is turned to the opposite side so that the ear to be operated is facing up. Infiltration with 2% xylocaine and 1:1,00,000 adrenaline in post auricular region and also in supra-auricular region. The perichondrial graft is harvested via the post aural incision itself.

A small piece of temporalis muscle fascia, for closure of a total perforation can easily be obtained in the retro auricular approach by elevating the skin at the superior borders of the post auricular incision, exposing the fascia. The lateral surface of the deep fascial layer is cleaned using freers rugine. A round incision in the temporalis fascia is performed with scalpel blade no.15. (Figure 1)



**Figure 1. Harvesting temporalis fascia in retro auricular approach**

The fascia elevated with forceps, and its undersurface is again cleaned of remaining muscle fibers.

#### Perichondrium via retroauricular incisions

In the retroauricular fold incision and posterosuperior incision running close to the auricle, the skin and the subcutis are elevated with a pair of blunt scissors. The attachment of the posterior auricular muscle to the auricle is freed, and the muscle is pushed posteriorly. A curved incision through the perichondrium is performed with scalpel blade no.15 the perichondrium is elevated from the cartilage using a freer rugine and a larger piece is resected with a pair of scissors.

If the perichondrium is desired separately, it is worthwhile elevating it from the cartilage with a freers rugine before removing the cartilage, since this type of elevation is easier. The cartilage and perichondrium can be removed separately.

After harvesting the graft the external ear canal is cleaned of any debris and infiltration is given in all the four quadrants of the external auditory canal. A curvilinear incision is then made in the posterior canal wall from 6'o'clock position to 12'o'clock position (vascular strip) and elevated laterally. A postauricular incision is made in the postauricular crease using a # 15 scalpel blade. The incision is made with the dominant sureions hand while the nondominant hand vigorously pulls the ear laterally.

Hemostasis should be achieved prior to graft placement with gel foam packed into the middle ear space while the graft is being trimmed. The dried graft trimmed to size(approximately 2.5 ×1.5 cm). A slit is made in the superior aspect of the graft to accommodate placement medial to the manubrium. The middle are space is filled with gel foam. Packing should start at the Eustachian tube region and proceed posteriorly. With 22-gauge suction in one hand and a drum elevator in the other, the graft is slid medial to the manubrium and onto the lateral attic wall. The graft is the sucked out through the anterior window for support. The remaining graft is draped along the posterior canal wall and the tympano-meatal flap with attached annulus is repositioned over the graft. The entire perforation edges are rechecked for any defect not covered by graft and corrected with the drum elevator.

#### Postoperative care

All patients were kept with nil per oral for 5 hours post operatively. Pain was managed with Inj.Ketorolac i.m. Sutures were removed on the 7<sup>th</sup> day. Patients areb advised to continue antibiotics anti-inflammatory drugs for 10 days. Follow-up is at 3 weeks, 6 weeks and 12 weeks. By 6 weeks, the grafted drum has thinned considerably and takes on the appearance of a normal tympanic membrane.

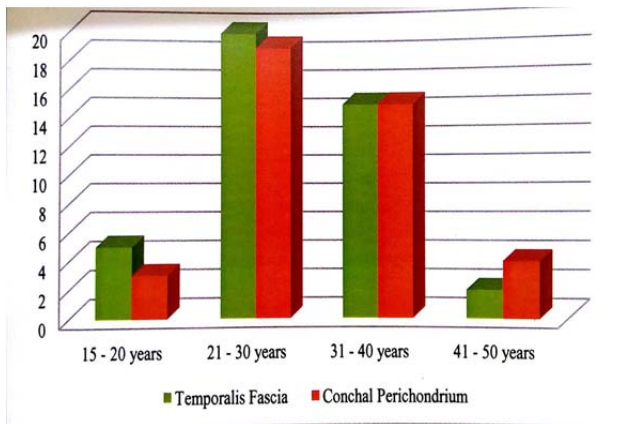
#### Follow up

The graft takes up and hearings are assessed at 12<sup>th</sup> week postoperatively.

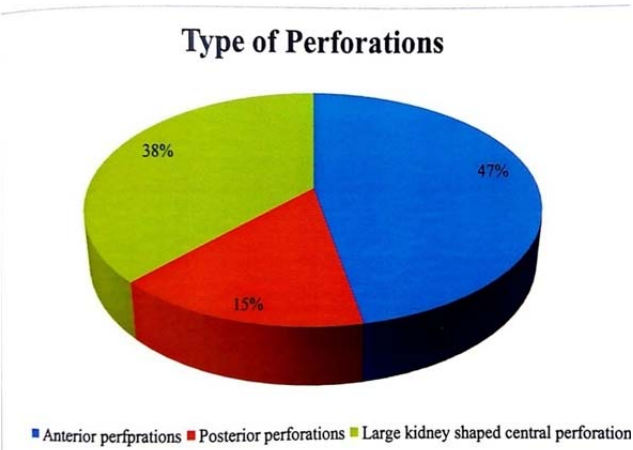
#### RESULTS

Overall 85 patients were included in the study. Of these 85 patients 42 received temporalis fascia graft for closure of tympanic membrane perforations and 41 received conchal perichondrium graft for closure of tympanic membrane perforations. 2 patients were excluded from the study as

there was discontinuously of ossicle that was detected per operatively.  
 The age of the patients in the study varied from 18 -47 years. Patients age group and graft used is presented in the Figure 2.

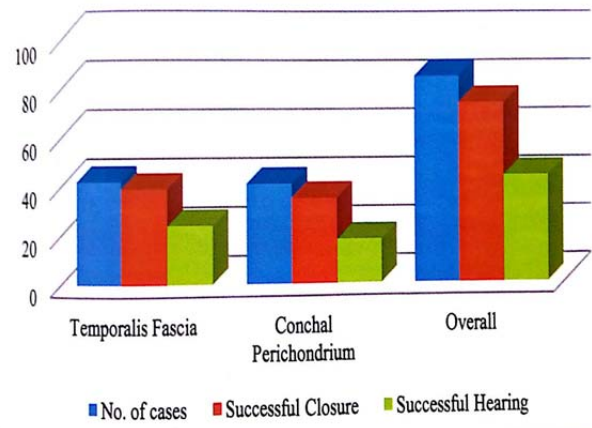


All perforations were only central perforations. According to position of perforation in relation to the handles of malleus, the perforations were classified as anterior, posterior and large central perforation. The type of perforation performed is presented in the figure 3.

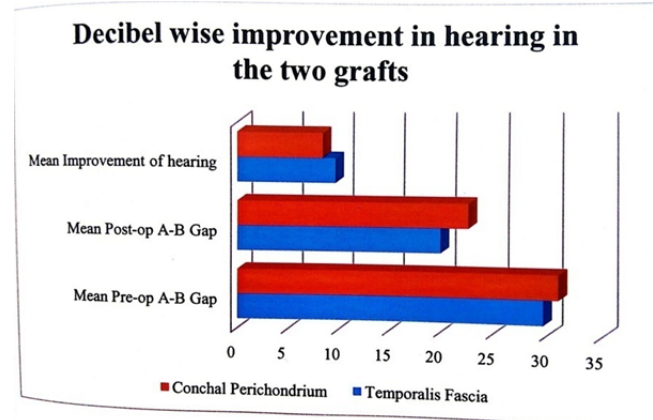


Pre op investigations were all done for all the 85 patients. In all cases haemogram values were within normal limits. Sclerotic mastoid was found in 63 out of 85 patients. The pure tone audiogram in all patients showed air conduction (AC) threshold range at 22.8-47.7 dB and range of bone conduction threshold at 6.6-10dB. The average air bone gap was in the range of 20-41.6 dB.

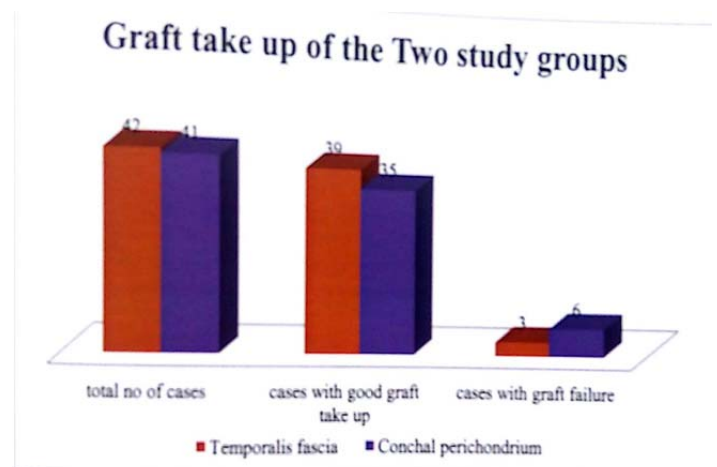
The graft take up was judged by the end of the third months by otoendoscopy. The take up was considered good if there is no residual perforation and vasularity of the graft. If there was any residual perforation then the graft is considered a failure. A result of myringo plasty with graft used is presented in figure 4.



When comparing the air bone gap reduction in the two groups of patients the average reduction of air-borne gap in the group receiving temporalis fascia was 9.68 dB and the average reduction of air-bone gap in the patients receiving conchal perichondrium was 8.41 dB. Decibel wise improvement in hearing in the two grafts is presented in figure 5.



In this study, temporalis fascia, which is the current gold standard graft material for mringoplasty, achieved the maximum hearing improvement. Also the failure rate of grafts with temporalis fascia was less (7%) compared to conchal perichondrium with a failure rate of 15%



### DISCUSSION

In this present study myringoplasty surgery was performed for all the 85 patients who were included in the study. The mean age of the patients undergoing myringoplasty in this study was 28.9 years. All of these patients had complaints of discharging ear of varied duration and varied degree of hearing loss. But dry ear for at least 3 months was one of the major criteria for inclusion of the patients in the study. In all the patients both preoperative and post operative audiometry was performed in all cases at the end of 12 weeks following surgery. In this study successful closure of perforation of 93% and successful hearing improvement of 84% occurred in anterior type perforation. So hearing improvement was better in anterior type of perforations, than in posterior or large central perforations. To check whether there was any significant difference between the mean hearing gain in the group receiving temporalis fascia and conchal perichondrium the student t test for independent samples was applied. The t value was calculated as 4.433. The p value was calculated as 0.000. thus the student t test implies that there was significant difference between the mean hearing gain in the groups receiving temporalis fascia graft and groups receiving conchal perichondrium and the difference obtained are not due to any chance.

The student's t test in comparing the significance between mean hearing gain in successful graft take-up and failed graft take-up showed that there was significant difference between the mean hearing gain in the groups successful graft take up and groups failed graft take up and difference obtained is not due to any chance.

By plotting the three variables i.e. gain in A-B gap, graft used and graft take-up the F values were calculated as 19.653 using ANOVA. This was significant that the gain in A-B gap and graft take up was better in the group receiving temporalis fascia as graft material than the group receiving conchal perichondrium as the graft material.

### CONCLUSION:

This study confirms that the temporalis graft is better than conchal perichondrial graft for closure of perforations in inactive mucosal type of chronic otitis media with a central perforation. The post operative results showed that hearing improvement was better in the study group receiving temporalis fascia as graft material than the group receiving conchal perichondrium. Also the graft failure was less with the study group receiving temporalis fascia than graft take-up was better with temporalis fascia graft than conchal perichondrial graft.

### ACKNOWLEDGEMENT

The authors acknowledge the Dean, Sree Balaji Medical College & Hospital for his kind permission to publish the work.