

# Experimental Justification of Compressive Hemorrhoidectomy with Shape Memory Implants

F.S. Aliev,

*Tyumen State Medical University, Russia, 625023, Tyumen, street Odessa, 54.*

A.Y. Ilkanich,

*Surgut State University, Russia, 628412, Surgut, Lenina prospect, 1*

N.F. Barodin, K.M. Autlev, F.V. Makhnev

*Tyumen State Medical University, Russia, 625023, Tyumen, street Odessa, 54.*

## Abstract

The radical character of compressive hemorrhoidectomy with shape memory titanium-nickelide implants was estimated by angioproctograms before and after the operation. The blockage of arterial blood flow to cavernous tissue and the complete removal of the latter were considered as main criteria for radicality. The research showed that compressive hemorrhoidectomy operation fully meets these criteria. However, along with the typical localization of hemorrhoid boluses, in 33,2% of cases additional permanent arteries (from 1 to 3) were found, usually localized at 1, 5 and 9 o'clock of nominal clock face of anus. This fact can lead to recurrence of the disease.

**Key words:** compressive hemorrhoidectomy, titanium-nickelide, surgery; radicality, angioproctogram, cavernous tissue

## INTRODUCTION

Hemorrhoid is a common human disease. The prevalence of hemorrhoid is 140-160 cases per 1000 adults [1, 2]. The proportion of hemorrhoid from the total number of patients with coloproctological diseases falls from 35 to 41% [1, 3]. Milligan-Morgan hemorrhoidectomy in various modifications is still a common method of surgical treatment in Russia. At the same time in the past decades minimally invasive methods, that do not require a hospital stay, have become a frequent practice. Surgeons most commonly use compression hemorrhoidectomy via rubber band ligation. Rubber band ligation is considered to be an effective minimally invasive procedure with minimal risk of post-operative complications [3, 4]. The following advantages of this method have been pointed out in scientific literature: simplicity of the procedure, low cost, possibility of outpatient treatment, absence of painful conditions, possibility to maintain patient's work capacity. Good results of this treatment in the long term after the operation are observed in 65-85% of cases [5]. While the recurrence rate ranges from 15 to 30% depending on the stage of hemorrhoid and duration of post-operative observation period [1]. Among the main reasons of recurrence are preservation of arterial flow and incomplete removal of cavernous tissue [6, 7, 8]. Therefore, no type of ligation of the base of hemorrhoidal bolus with suture material or elastic latex ring can improve operation results in the long term.

Compression hemorrhoidectomy with titanium-nickelide shape-memory clamps [9], can be considered as an alternative method to rubber band ligation. Clamps for compression hemorrhoidectomy have a linear shape of two parallel mutually adjacent jaws 30-40 mm in length. The essence of the operation is that the pre-cooled jaws of the clamps are forced apart and then put on the base of hemorrhoidal bolus along the anal canal. Being pre-heated, clamps change their shape back to the original one, which ensures the compression of the hemorrhoid base between the jaws of the clamps. This leads to ischemic necrosis and

later rejection of tissues together with the clamps. Unlike latex rings, titanium-nickelide based alloys meet the highest medical and technical demands due to their biochemical and biomechanical compatibility with body tissues. Deformation of titanium-nickelide implants under stress and tension corresponds to similar deformation patterns as in biological tissues and systems, which allows providing constant dosed rubber-like compression of tissues [6]. At the same time, the compressing force doesn't exceed the resistance of the compressed tissues [9]. This technique is considered to be minimally invasive and doesn't even require hospitalization. The analysis of special literature revealed no scientific works dedicated to researching the radical character of this method.

## Research objective

The goal of the research is to study and evaluate the radical nature of compression hemorrhoidectomy with titanium-nickelide clamps under experimental conditions with the focus on vascular architectonics of the distal section of the rectum.

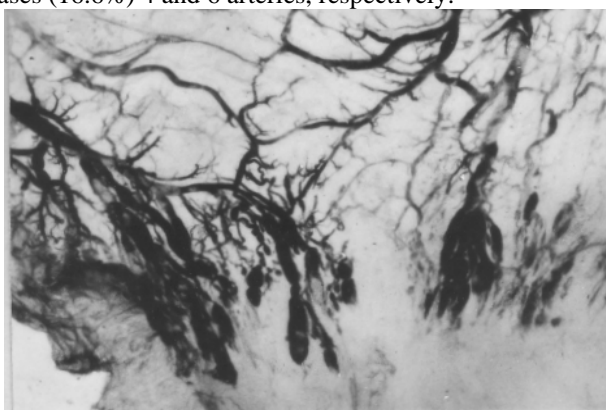
## MATERIALS AND METHODS

The criterion for evaluating the radical character of hemorrhoidectomy was based on the well-known assumption that hemorrhoidal disease is caused by dystrophic changes in the fibro-muscular structure of the anal canal and vascular cavernous malformations located in the distal segment of the rectum [2, 4, 7]. The radical character of compression hemorrhoidectomy with titanium-nickelide devices is proved by the fact of vascular pedicle occlusion caused by its detachment at the level of hemorrhoidal clamping, the maximum compression of cavernous tissue. Experimental studies were carried out on 18 corpses of adults. Vessels of the rectum were catheterized and contrasted through superior rectal vessels (L Kapuller method, 1974). Water suspension of powder-like red lead or zinc oxide can be used as contrast agents. The rectum is then extracted from the body by abdominoperineal access and cut along its anterior wall.

Survey X-ray photographs of the rectum are taken before and after application of compression devices to the mucous membrane of the anal canal. When analyzing the data of angiographic studies, special attention was paid to the type of superior rectal artery branching, the number of main branches and the characteristics of cavernous vascular elements.

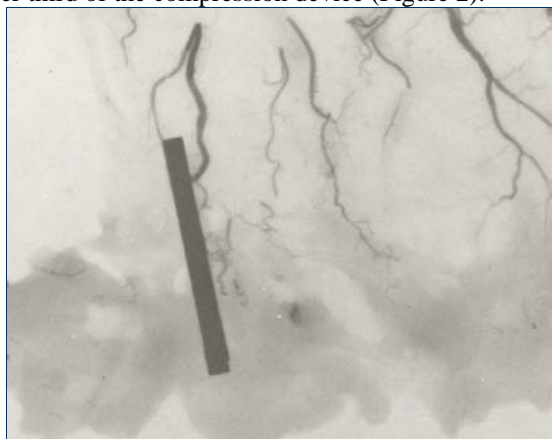
### RESULTS AND DISCUSSION

Angiographic survey showed sectional localization of vascular cavernous glomeruli in accordance with the number of arteries within the typical localization in the projection of internal hemorrhoids. The number of superior hemorrhoidal vessels was different. Only in 7 (38.8%) cases angiographic surveys showed 3 nutrient arteries at 3, 7 and 11 o'clock, in 2 (11.1%) cases - 2 arteries (Fig. 1); 3 cases (16.6%) 4 and 6 arteries, respectively.



**Fig. 1. Angioproctograms. Cavernous structures of hemorrhoids with 2 superior nutrient vessels**

Another 3 (16.6%) cases revealed a segmental localization of the vascular glomeruli without superior hemorrhoidal arteries. In this case, despite the variability of the arterial branches, the localization of internal hemorrhoids is mainly observed at 3, 7 and 11 o'clock. Vascular inosculation with sub-dermal cavernous bodies were observed only in cases. After the application of clamps to the base of the boluses, prior to the contrasting of the vessels, the survey X-ray images of the rectum clearly showed compression of the artery that feeds the hemorrhoidal bolus at the level of the upper third of the compression device (Figure 2).



**Fig. 2. Angioproctogram. Embedding of hemorrhoidal vessels after application of compression implant. Contrasting of vessels with zinc oxide**

After contrasting the vascular system of the distal section of the rectum, along with compression of the hemorrhoidal artery, formation of non-vascular zones in the zone of cavernous elements was observed. Most convincingly it could be seen on angiograms with detaching of the hemorrhoidal bolus above the compression device (Figure 3).



**Fig. 3. Angioproctogram. Hemorrhoidal artery compressed by compression device. The knot above the clamps is cut off.**

Thus, on the basis of the obtained research results, we can assume that compression hemorrhoidectomy with titanium-nickelide shape memory clamps, in contrast to rubber band ligation, will improve post-operative results in the long term. At the same time, the presence of additional arterial trunks, which do not fit with localization of internal hemorrhoids, requires the search for new solutions to prevent recurrence of the disease and the choice of optimal surgical treatment. In clinical setting, the only method for detecting the terminal branches of the superior rectal artery is the transanal duplex scanning. The doppler-controlled desarterization can be used as a supplement to the method of compression hemorrhoidectomy shape-memory implants.

### CONCLUSIONS

Experimental results showed that the compression devices implanted on the bases of the hemorrhoidal bolus securely compress the vascular pedicle together with the nutrition node of the artery and deprive the entire hemorrhoidal complex of the blood supply. This fact proves that compression hemorrhoidectomy operation with nickelide titanium clamps fully meets the criteria of radicality. Additional arterial trunks require the search for new optimal methods of minimally invasive surgical treatment of patients with hemorrhoidal disease.

### REFERENCES:

- [1] Vorobiev G.I., Shelygin Yu. A. and Gratitude L.A. Hemorrhoids: a guide for doctors. 2 nd ed., Pererab. And additional. Moscow: Littera, 2010, pp. 200 .
- [2] Zagryadsky E.A. Transanal desarterization of internal hemorrhoids under the Doppler control with mucopexia and mucosal lifting in the treatment of hemorrhoids III-IV stage. Surgery. 2009; 2: 52-58
- [3] MacRae H.M. and McLeod R.S. Comparison of hemorrhoidal treatments: a meta-analysis. Can J Surg. 1997; 40: 14-7

- [4] Shelygin Yu.A. and Grateful L.A. Reference of coloproctologist. Moscow: Littera, 2012, pp. 64-89
- [5] Savoiz D., Roche B., Glauser T., Dorbrinow A., Ludwig C. and Marti M.C. Rubber band ligation of hemorrhoids: relapse as a function of time. *Int J Colorectal Dis.* 1998; 13: 154-6.
- [6] Kecherukov A.I., Aliev F.Sh., Guenter V.E., Chernov I.A., Molokova O.A., Kononov V.P. and Dolgatov M.A. Application of nickel titanium implants in colon surgery. Shape memory materials and new technologies in medicine (edited by Guenther V.E.). Tomsk, 2007, pp. 67-69.
- [7] Melman E.P. and Datsun I.G. Functional morphology of the rectum and structural basis of the pathogenesis of hemorrhoids. Moscow: Medicine, 1986, pp. 176.
- [8] Titov A.Yu., Mudrov A.A., Kostarev I.V. and Kucherenko O.V. Dezarterizatsiya Internal hemorrhoids with sclerotherapy in the treatment of patients with chronic hemorrhoids. *Medical Council*, 2012; 9: 94-96.
- [9] Aliev F.Sh., Savelyev N.N. and Kotelnikov A.S. (2014). Innovative technology in the treatment of patients with hemorrhoidal disease. *Coloproctology*, 2014; 3: 13.