

# Therapeutic Effect of Sildenafil in Experimental Colitis through Anti-Oxidative Stress and Inhibition of Adhesion Molecules

Mohammed J Manna<sup>1\*</sup>, Ahmed Abu-Raghif<sup>2</sup>, Khulood M Alsara<sup>3</sup>

<sup>1</sup>College of dentistry /Al-Mustansiriya university

<sup>2</sup>Dept. of Pharmacology and Therapeutics, AL- Nahrain University.

<sup>3</sup>Pharmacy department / Al – Isra'a University College

## Abstract

Inflammatory bowel disease is a progressive inflammatory intestinal disease characterized by colon tissue edema and increased epithelial permeability of colon and extensive infiltration of leukocytes in the colon. Failure of current treatment strategies and the adverse effects of currently used drugs, it is crucial to investigate new drugs with more favourable therapeutic profiles. The aim of the present study was to evaluate possible therapeutic effects of sildenafil against acetic acid – induced colitis in a rat model and to found out correlation between severity index with oxidative stress parameters and inflammatory markers. Experimental colitis was induced in rats by rectal administration of 4% acetic acid (vol/vol). Rats with colitis were received either sildenafil 10mg/kg or sulfasalazine 100mg/kg orally for 7days. Macroscopical and microscopical assessment and the measurement of the colonic cytokines (IL-6 and TNF- $\alpha$ ), oxidative stress markers; myeloperoxidase (MPO) and malondialdehyde (MDA), and adhesion molecules (E-Selectin and ICAM-1). Our findings had shown that both macroscopical lesion area and histological colonic injury induced by acetic acid were significantly reduced by both sildenafil and sulfasalazine. These were accompanied by attenuation of the elevated colonic MPO activity, MDA and proinflammatory cytokines. Besides downregulation of the adhesion molecules. These results demonstrated that sildenafil possesses therapeutic potential in experimental colitis. The anti-inflammatory actions involve antioxidant effect along with inhibition of adhesion molecule synthesis in the colonic tissues.

**Key Word** : Sildenafil, ulcerative colitis, Oxidative stress, Adhesion molecules

## INTRODUCTION

Inflammatory bowel disease (IBD) is a chronic inflammatory disease. It is of two different types; ulcerative colitis and Crohn's disease [1]. They are characterized by immune-mediated chronic relapsing intestinal disorders, associated with rectal bleeding and diarrhea resulting in damage of the epithelial barrier and the formation of epithelial ulceration[2]. Despite the fact that little is known about etiology of these diseases, it is believed to involve an abnormal host response to endogenous or environmental or immunological factors, causing initial tissue damage followed by amplification of this response [3]. IBD are also associated with extensive inflammatory infiltrates in the lamina propria characterized by extensive inflammatory infiltrates consisting of polymorphonuclear neutrophils, eosinophils and plasma cells, leading to a remarkable production of unstable chemical species such as nitrogen and reactive oxygen species, significantly involved in injury[4,5].

Activation of these infiltrating cells results in the release of different pro-inflammatory mediators such as tumor necrosis factor-alpha (TNF- $\alpha$ ), interleukin-1  $\beta$  (IL-1  $\beta$ ), an IL-6, plays a crucial role in tissue disruption and ulceration [6].

Although extensive development has been made in the treatment of ulcerative colitis, adverse effects and incomplete efficacy of currently used medications is a continuous challenge[7] For this reason, there is a need to develop new strategies that in could restore the altered immune response that emerges in the inflamed intestine.

One of the important strategies is targeting adhesion molecules that expressed on the surface of endothelial cells and lymphocyte; which in fact recruits immune and inflammatory cells from the periphery into site of inflammation. On the other hand there is evidence that nitric oxide (NO) inhibits the expression of adhesion molecules on endothelial cells, which is an important step in neutrophil migration[8].

Sildenafil is one of the drugs that have nitric oxide modulating activity[9]. This effect of sildenafil is attributable to inhibition of phosphodiesterase-type 5 enzyme that catalyze the hydrolysis of cGMP[10], and has vascular smooth muscle relaxant effect and inhibition of platelets aggregation by preventing the breakdown of nitric oxide –dependant cGMP[11]. Moreover sildenafil has antioxidative stress potential<sup>(12)</sup> and prevent lipid peroxidation and cytokine release[13].

## MATERIAL AND METHODS

### Materials

Animals : Adult male albino rats (200-220g) were purchased from animal house of the national center for drug control and researches (NCDRC). Animal were housed five per cage for one week prior to the experiment and had access to laboratory chow pellet and were allowed to drink tap water ad libitum. All animal experiments were performed after getting prior approval from the institutional animal ethics committee college of medicine Al-Nahrain university.

Drugs : sildenafil and sulfasalazine were purchased from Sigma –Aldrich company .

### Experimental Design

This study was conducted on 40 adult male albino –wister rats weighing 200-220g previously submitted to starvation for at least 24hrs . Animals were divided into four group (n=10/group) .Group I kept as control and received no treatment .Group II ,III, IV were subjected to the induction of colitis by rectal administration of 4% acetic acid (AA) (v/v) . Thirty minute after the induction of colitis group II was given normal saline orally ; group III and IV were treated orally with sildenafil 10mg/kg and sulfasalazine 100mg/kg respectively for 7 days.

### Induction of colonic inflammation

Since prior feeding has been shown to prevent the ulcerogenic action of certain drugs and chemical[14]. Rats were starved for at least 24hrs before the induction of colitis but were be allowed free access to tap water , during starvation , rats were kept in cages provided with a wide wire –mesh floor to avoid coprophagy. On the day of the experiment , water was held two hours before the procedure. Experimental ulceration in colon tissue was done according to the method described by Mousavizadeh *et al* [15] with slight modification. In brief, under light ether anesthesia rats were administered 5ml/kg of 4% acetic acid (AA) solution (BDH Chemical Ltd., England) by transrectally using a flexible silicone plastic tube with an external diameter of 2mm was inserted rectally into the colon to 8cm . After acetic acid administration, rats were holed horizontally for 2 min to prevent AA leakage. Control animals underwent the same procedure using equal volume of normal saline instead of AA solution.

### Preparation of drugs

All drugs were freshly prepared before administration on the day of the experiment .

Investigated drug (Sildenafil) and the standard sulfasalazine were prepared as suspensions in distilled water using sodium Carboxymethyl cellulose (s CMC) 0.3% W/V . Sildenafil was used at a dose 10mg/kg (these doses were chosen depending on previous studies that have been showing their gastroprotective activity at a concentration 10mg/ml [16, 17].

Sulfasalazine was used as standard therapy in a dose of 100mg/kg[18].

### Assessment of colitis

After the end of experiment , animals were sacrificed by an over dose of diethyl ether inhalation and then the abdomen was rapidly dissected and open and the colon was removed .The pieces of colons were cut open in an ice bath cleansed gently using normal saline , and observed normally for macroscopic and microscopic assessment. Then samples were cut into two pieces , one piece for histopathologic assessment (maintained in neutral formalin 10% as a fixater ) and one piece for immunohistochemistry study

### Macroscopic evaluation

**Colonic mucosal damage** (mean area of colonic mucosal damage)

The excised colonic segment (8 cm proximal to anus ) was immediately immersed in normal saline , cleaned from adherent tissues and then opened longitudinal and rinsed with 0.9% sodium chloride solution to discard the fecal materials .

Then the segment was fixed with pins on a dissecting board , and the area of mucosal damage was measured using a computerized planimeter in accordance to the method described earlier[19].

**Colon edema** The colon specimen of each animal was incised along its mesenteric border and gently washed .This is measured through colon weight (CW). It was used as a index of tissue edema , which reflected the severity of colitis[20].

### Disease activity index (DAI)

To quantify the clinical evaluation of the disease we used the DAI described by Meerveld and Tyler[21] that based which include body weight loss stool consistency , rectal bleeding (gross or occult ) we used five grades of weight loss {0 , no loss or weight gain ; 1 , 1-5 % loss ; 2, 6-10%loss ; 3 : 11-15% loss ; 4: greater than 15% loss } , three grades of stool consistency {0: Normal ; 2 : loose ; 4 : diarrhea } , and three grades of bleeding {0 : normal ; 2 occult blood –positive ; 4 : gross bleeding }.

The presence of occult blood in faces was determine using benzidine test.

The total score of DAI was calculated as combined of these scores divided by 3[22].

### Macroscopic colonic score

The macroscopic colonic score was assessed by the scoring system adapted from[23] as following: score are assigned based on the clinical features of the colon using a scale ranging from 0-4 as follows : 1, intact epithelium with no damage ; 2 , patch type superficial hyperemia ; 3 , generalized patch type hyperemic regions; 4 , generalized hyperemic and hemorrhage.

### Histological evaluations:

The colonic samples were fixed in 10% formalin, dehydrated, embedded in paraffin, deparaffinized with xylene , cut into 4  $\mu$ m sections and stained by Hematoxylin and eosin (H&E). Slides were examined and scored for histopathological evaluation. The slides were coded to prevent observer bias during evaluation. All tissue sections were examined in a blinded fashion by experienced histopathologist and results scored according to Cooper et al[24].

**Table 1 :Histopathological score of colitis**

Score	Destruction of epithelium and/or glandular crypts	Dilation of glandular crypts	Depletion and loss of goblet cells	Inflammatory cell infiltration	Edema	Hemorrhagic mucosa	Crypt abscess	Apoptosis	Dysplasia
0	morphologically normal	Normal aspect	Normal aspect	absence of infiltration	Absent	Absent	Absent	absent	absent
1	focal destruction	Focal dilation	slightly depleted goblet cells	infiltrate at the sub-epithelial and lamina propria level or crypt bases infiltration	Focal	Focal	focal	Focal	Focal
2	zonal destruction	Zonal dilation	zonal or moderately depleted goblet cells	infiltration reaching muscularis mucosa	zonal and/or moderately diffuse	Zonal	Zonal	Zonal	Zonal
3	diffuse and/or mucosal ulceration involving submucosa and/or diffuse crypt loss	diffusely dilated crypts	diffusely or complete depletion of goblet cells	severe and extensive infiltration reaching submucosa and/or involving muscularis propria	extensive and severe	Diffuse	Diffuse	Diffuse	diffuse

**Table (2): Gross features in control and study groups**

Variable †	Control n=10	Colitis n=10	Sild n=10	Sulfaz n=10
MD(mm2)	0.00 ±0.00 D	16.11 ±0.74 A	7.65 ±0.44 B	5.26 ±0.43 C
CW (g)	1.13 ±0.17 C	3.12 ±0.24 A	2.81 ±0.18 A	1.63 ±0.23 B
DAI	0.00 ±0.00 D	10.50 ±1.50 A	4.40 ±1.11 B	2.10 ±0.30 C
MAC score	0.00 ±0.00 D	9.30 ±0.64 A	4.40 ±0.49 B	2.50 ±0.50 C

Capital letters for comparison; different letters indicates significant difference; similar letters indicates insignificant difference; Sild; Sildenafil; Sulfaz: sulfasalazine; † values expressed as mean ±Standard deviation (SD).

**Table (3) :Histopathological score and adhesion molecules**

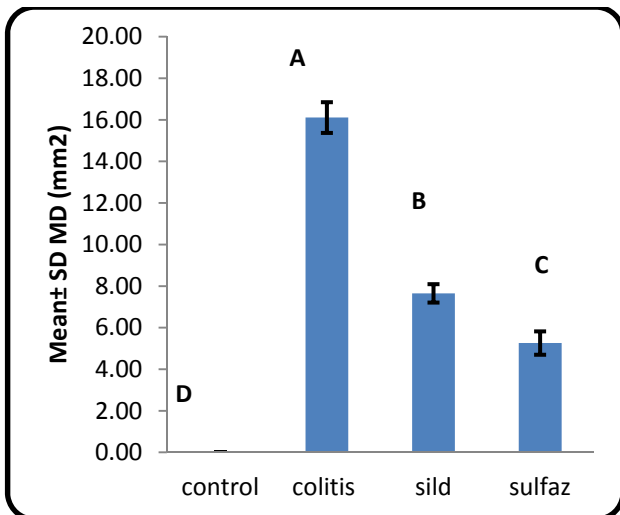
Variable †	Control n=10	Colitis n=10	Sild n=10	Sulfaz n=10
Histo score	0.00 ±0.00 C	3.00 ±0.24 A	1.80 ±0.40 B	1.80 ±0.40 B
ICAM-1	0.90 ±0.30 C	4.00 ±0.34 A	2.90 ± 0.30 B	2.90 ±0.30 B
CD62	0.90 ±0.30 C	3.90 ±0.30 A	1.80 ±0.40 B	1.90 ±0.30 B

Capital letters for comparison; different letters indicates significant difference; similar letters indicates insignificant difference; Sild; Sildenafil; Sulfaz: sulfasalazine; † values expressed as mean ±Standard deviation (SD).

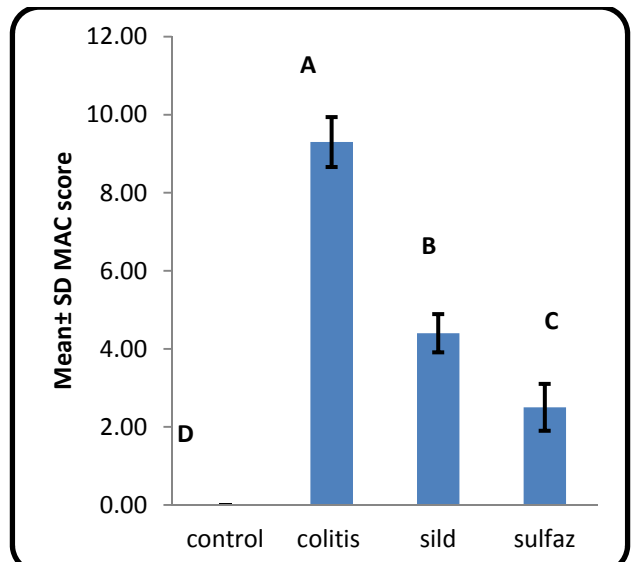
**Table (4) : Cytokines and oxidative stress markers immunohistochemical score**

Variable †	Control n=10	Colitis n=10	Sild n=10	Sulfaz n=10
TNF- $\alpha$	0.40 ±0.09 D	4.00 ±0.30 A	2.20 ±0.40 C	2.70 ±0.46 B
IL-6	1.00 ±0.23 D	4.00 ±0.30 A	2.10 ±0.54 C	2.50 ±0.50 B
MDA	1.70 ±0.46 D	4.00 ±0.35 A	2.30 ±0.46 C	2.70 ±0.46 B
MPO	0.80 ±0.40 C	4.00 ±0.45 A	1.80 ±0.40 B	1.70 ±0.46 B

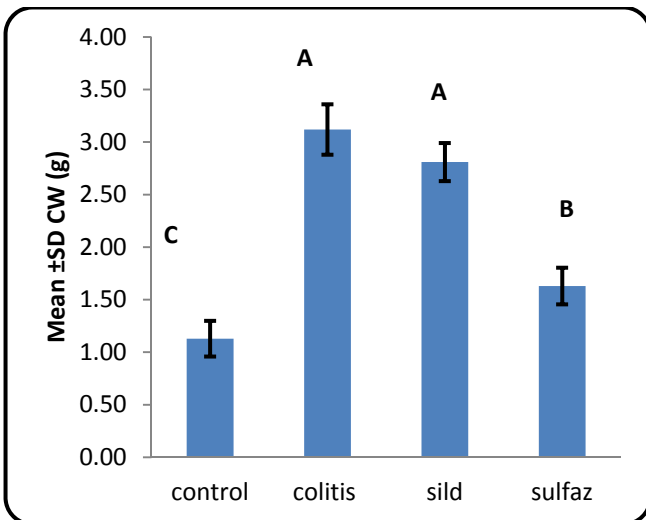
Capital letters for comparison; different letters indicates significant difference; similar letters indicates insignificant difference; Sild; Sildenafil; Sulfaz: sulfasalazine; † values expressed as mean ±Standard deviation (SD).



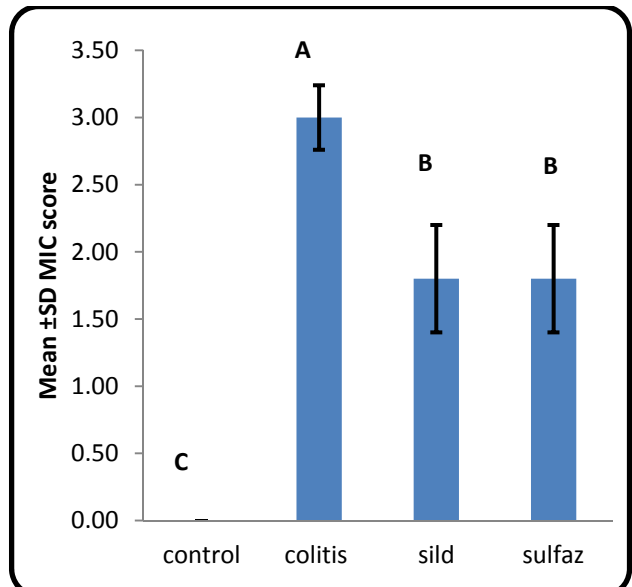
**Figure 1:** Mean area of mucosal damage in control and study groups  
Capital letters for comparison; different letters indicates significant difference; similar letters indicates insignificant difference; MD : Mucosal damage ; Sild; Sildenafil; Sulfaz: sulfasalazine



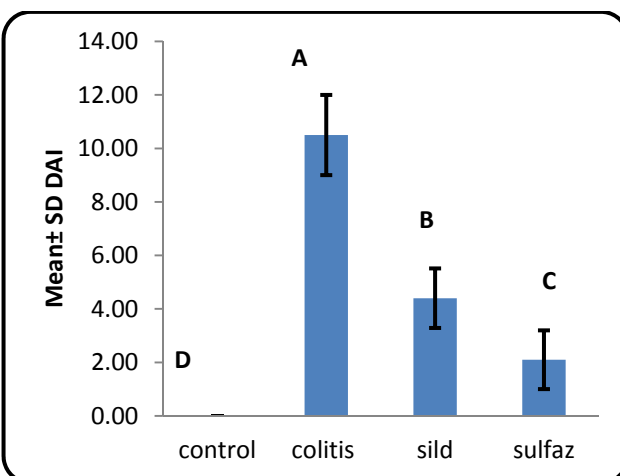
**Figure 4:** Mean macroscopic score (MAC) in control and study groups  
Capital letters for comparison; different letters indicates significant difference; similar letters indicates insignificant difference; Sild; Sildenafil; Sulfaz: sulfasalazine



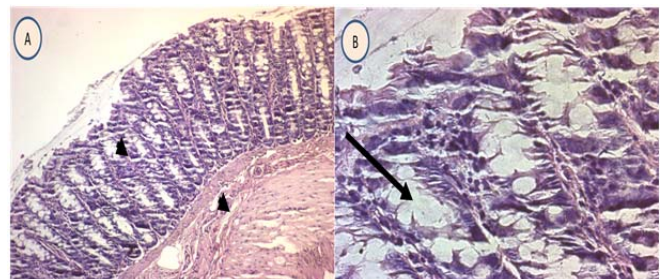
**Figure 2:** Mean colonic weight (CW) in gram in control and study groups  
Capital letters for comparison; different letters indicates significant difference; similar letters indicates insignificant difference; Sild; Sildenafil; Sulfaz: sulfasalazine



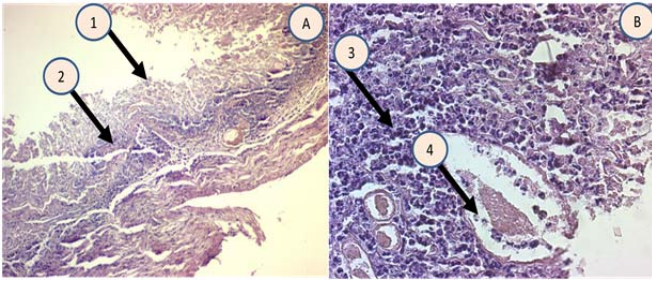
**Figure 5:** Mean histopathological score (MIC) in control and study groups  
Capital letters for comparison; different letters indicates significant difference; similar letters indicates insignificant difference; Sild; Sildenafil; Sulfaz: sulfasalazine



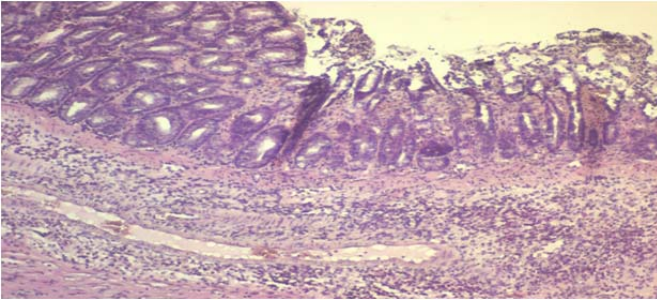
**Figure 3:** Mean disease activity index (DAI) in control and study groups  
Capital letters for comparison; different letters indicates significant difference; similar letters indicates insignificant difference; Sild; Sildenafil; Sulfaz: sulfasalazine



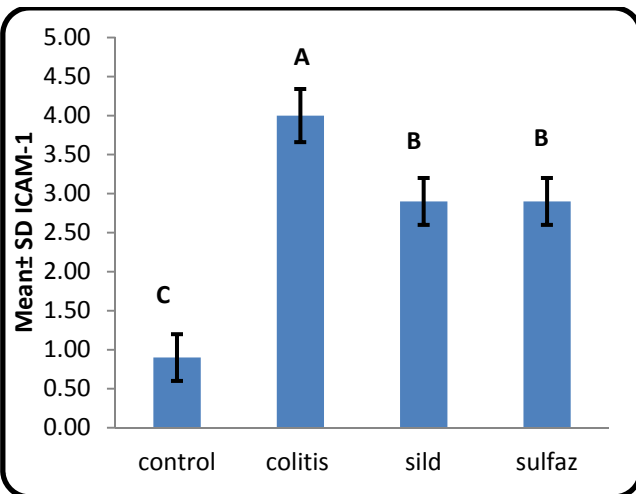
**Figure 6:** Histological section through colonic wall showing normal mucosal and submucosal pattern with no evidence of inflammation (arrow head) and preservation of goblet cells (arrow); A: 10X; B: 40 X; H and E stain.



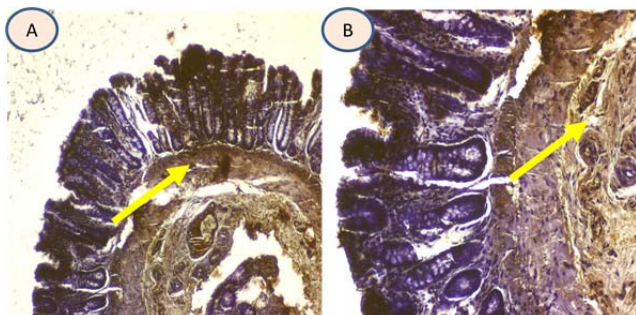
**Figure 7:** Histological section through colonic wall showing mucosal ulceration (1); superficial inflammation (2); mononuclear inflammatory infiltrate (3) and crypt abscess (4) in experimentally induced colitis in rat; A: 10X; B: 40 X; H and E stain.



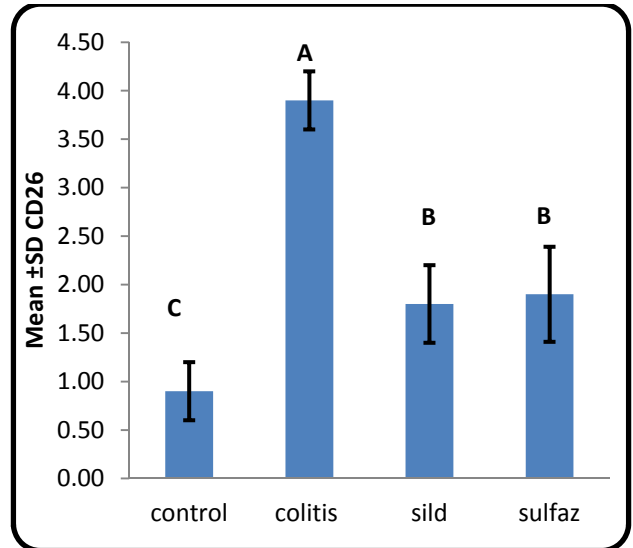
**Figure 8:** Histological section through colonic wall showing drug effects in which there is evidence of mucosal regeneration and glandular formation, less severe inflammation and goblet cells regeneration; A: 10X; B: 40 X; H and E stain.



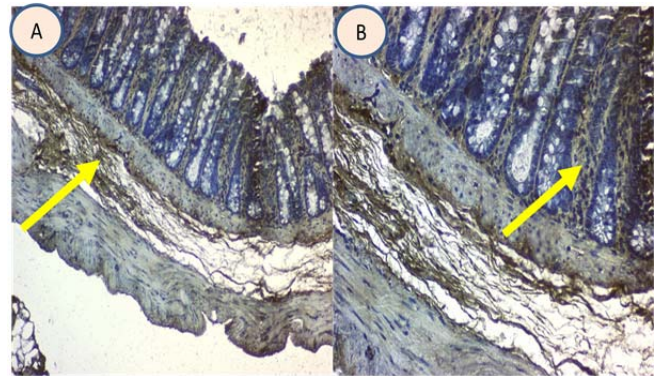
**Figure 9:** Mean intracellular adhesion molecule-1 (ICAM-1) score in control and study groups. Capital letters for comparison; different letters indicates significant difference; similar letters indicates insignificant difference; Sild; Sildenafil; Sulfaz: sulfasalazine



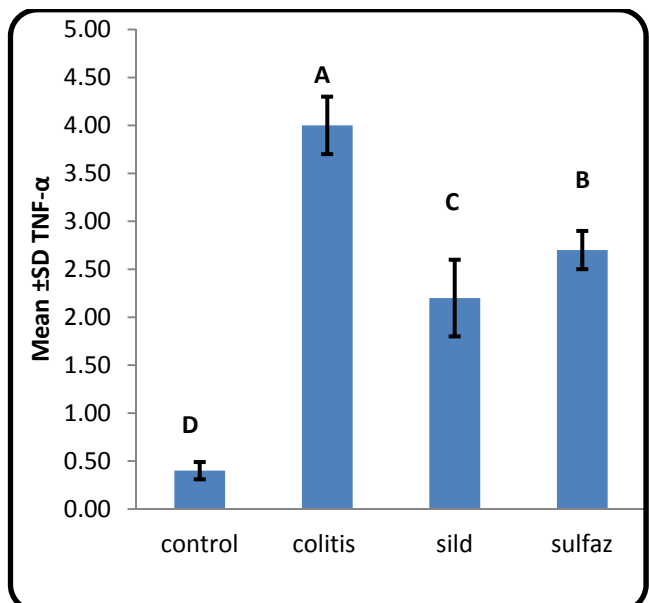
**Figure 10:** Immunohistochemical expression of ICAM-1 showing membranous pattern (yellow arrow); A: 10X; B: 20X.



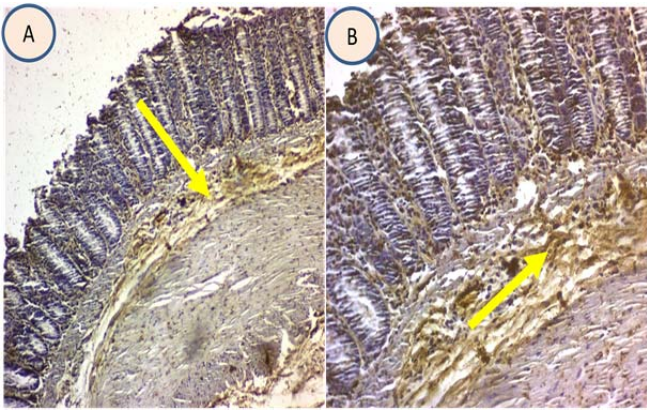
**Figure 11:** Mean CD62 score in control and study groups. Capital letters for comparison; different letters indicates significant difference; similar letters indicates insignificant difference; Sild; Sildenafil; Sulfaz: sulfasalazine



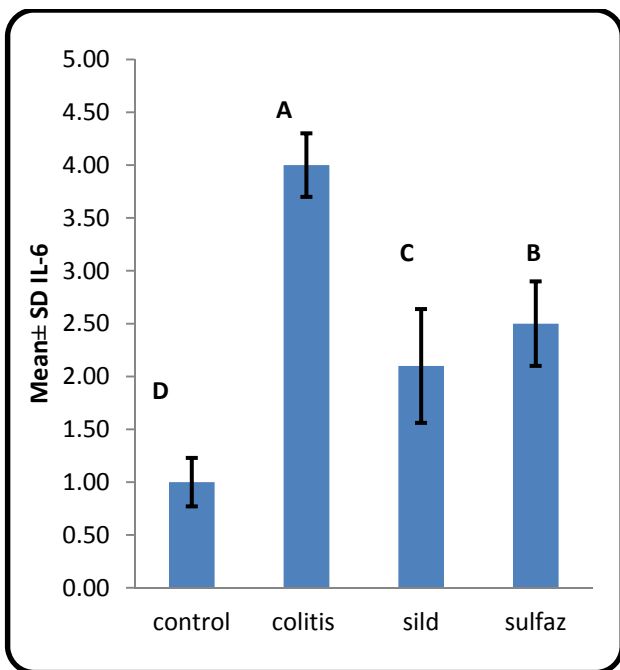
**Figure 12:** Immunohistochemical expression of CD 62 showing membranous pattern (yellow arrow); A: 10X; B: 20X.



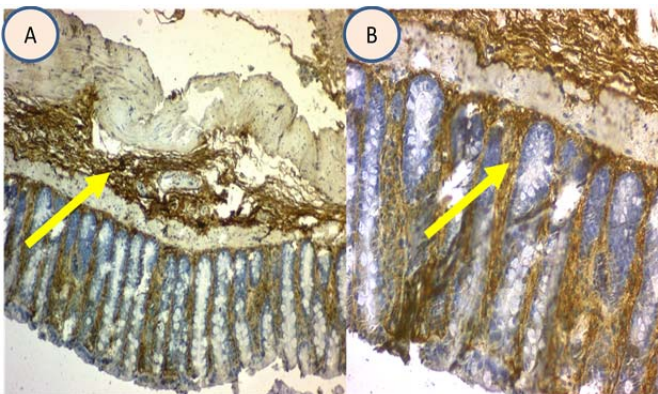
**Figure 13:** Mean TNF-α score in control and study groups. Capital letters for comparison; different letters indicates significant difference; similar letters indicates insignificant difference; Sild; Sildenafil; Sulfaz: sulfasalazine



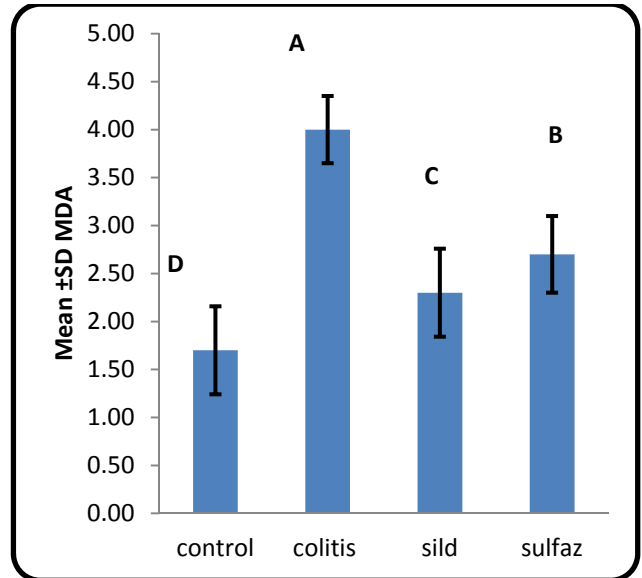
**Figure 14:**Immunohistocheical expression of TNF- $\alpha$  showing membranous and secretory pattern (yellow arrow); A: 10X; B: 20X.



**Figure 15:** Mean IL-6 score in control and study groups  
Capital letters for comparison; different letters indicates significant difference; similar letters indicates insignificant difference; Sild :sildenafil; Sulfaz: sulfasalazine

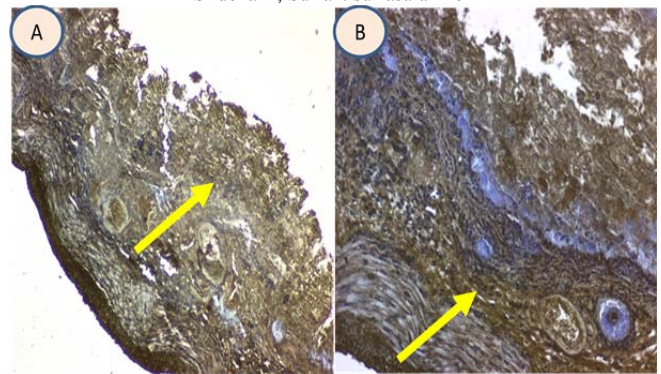


**Figure 16:**Immunohistocheical expression of IL-6 showing secretory pattern (yellow arrow); A: 10X; B: 20X.

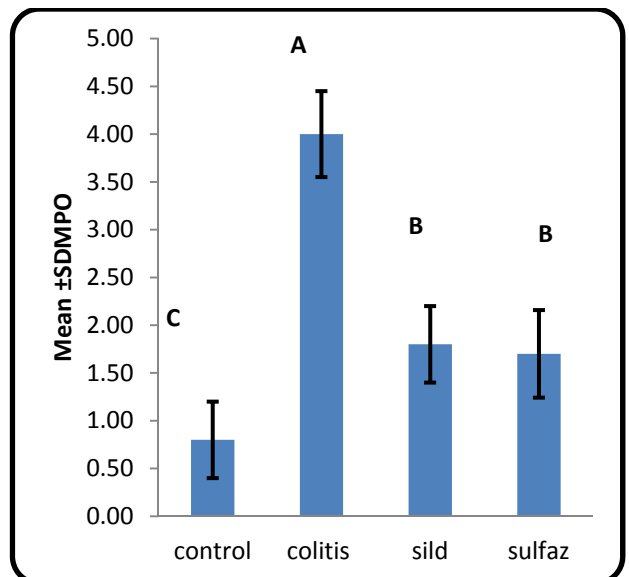


**Figure 17:** Mean malondialdehyde (MDA) score in control and study groups

Capital letters for comparison; different letters indicates significant difference; similar letters indicates insignificant difference; Sild; Sildenafil; Sulfaz: sulfasalazine

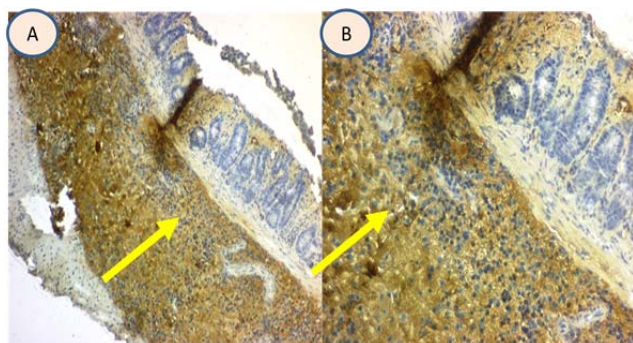


**Figure 18:**Immunohistocheical expression of MDA showing cytoplasmic pattern (yellow arrow); A: 10X; B: 20X.



**Figure 19:** Mean myeloperoxidase (MPO) score in control and study groups

Capital letters for comparison; different letters indicates significant difference; similar letters indicates insignificant difference; Sild; Sildenafil; Sulfaz: sulfasalazine



**Figure 20:**Immunohistochemical expression of MPO showing cytoplasmic pattern (yellow arrow); A: 10X; B: 20X

### Immunohistochemistry

Immunohistochemistry offers the advantage of directly demonstrating cells in the affected tissue[25]. The advent of specific antibodies developed for immunohistochemical reactions, together with the standardization of a specific method to meet the objectives of the present study, permitted analysis of the production of various biochemical markers in the paraffin-embedded intestine samples for measurement of the colonic cytokines (IL-6 and TNF- $\alpha$ ), oxidative stress markers (myeloperoxidase (MPO) and malondialdehyde (MDA)), and adhesion molecules (CD62 and ICAM-1). Quantification of IHC was performed according to the following semiquantitative scores[26] based on the percentage of positively stained cells as following: 0, no staining; 1,  $\leq 25\%$ ; 2, 26-50%; 3, 51-75%; and 4, 76-100%.

### Statistical analysis

Data were collected, summarized, analyzed and presented using three statistical software programs: the statistical package for social science (SPSS version 22), Microsoft Office Excel 2013 and Med Calc 2014. Numeric variables were presented as mean and standard deviation. The results of Kolmogorov Smirnov test of normality distribution for numeric variables was significant and comparison of mean values among groups was carried out using Kruskal Wallis Test and then comparison between any two groups was done using Mann Whitney U test. Spearman correlation test was used to evaluate correlations between histological scores and immunohistochemical expression scores. P-value was considered significant when it was equal to or less than 0.05[27].

## RESULTS

### Effect of sildenafil on macroscopic features

Rectal instillation of acetic acid was applied in this study is one of the modality that has been used to produce macroscopic colonic mucosal injury in rats. Acetic acid triggered an intense inflammatory reaction on the 7<sup>th</sup> day of colitis induction, the distal colon showed severe macroscopic edematous inflammation. The colonic mucosa was inflamed, hyperemic and hemorrhagic compared to normal control group. However, oral administration of sildenafil and sulfasalazine after the induction of colitis significantly ( $p < 0.01$ ) attenuate the colonic damage scores as shown in table 2 and figure 1. Nevertheless sildenafil failed to produce significant reduction in the colonic weight as compared

with sulfasalazine group that demonstrated significant ( $p < 0.05$ ) reduction effect comparable to the normal group as shown in table 2 and figure 2. However, both sildenafil and sulfasalazine showed significant decrease ( $p < 0.01$ ) in DAI as shown in table 2 and figure 3. Furthermore both drugs elicit significant ( $P < 0.01$ ) decrease in macroscopic score as shown in table 2 and figure 4.

### Effect of sildenafil on histopathological features

The present study demonstrated characteristic histological features in untreated colitis, essentially loss of intestinal crypt architecture and sloughing of intestinal cells, reduced goblet cell number and presence of different inflammatory cell infiltration as demonstrated in figure 5 and 6. On the other hand sildenafil and sulfasalazine treated groups, the histopathological changes were significantly ( $P < 0.05$ ) attenuated as judged by epithelization of colonic mucosa, reduction of edema and neutrophil infiltration as shown in figure 5. No significant differences was observed between sildenafil and sulfasalazine treated groups, both of them revealed a significant decrease in the pathological scores as compared with the colitis group, figure 5 and table 3.

### Effect of sildenafil on adhesion molecules (ICAM-1 and CD62)

The increased colonic ICAM-1 in the colitis group was found to be significantly ( $p < 0.05$ ) decreased after sildenafil and sulfasalazine treatment as shown in table (3), figure 9. Also both tested drugs cause significant ( $p < 0.01$ ) decrease in CD62 compared to colitis group as shown in figure 11.

### Effect of sildenafil on proinflammatory cytokines (TNF- $\alpha$ and IL-6).

As shown in table (4) and figure 13 and 15, colonic levels of TNF- $\alpha$  and IL-6 showed drastic raise after acetic acid introduction compared to those of control group. In contrast these values were significantly ( $p < 0.05$ ) lower in rats treated with sildenafil and sulfasalazine. However, sildenafil significantly ( $p < 0.05$ ) decrease proinflammatory cytokines as compared with sulfasalazine treated group.

### Effect of sildenafil on oxidative stress markers (MDA and MPO)

Administration of sildenafil or sulfasalazine to acetic acid treated rats significantly ( $p < 0.05$ ) reduced MDA compared to the colitis group as shown in figure 17. On the other hand treatment with either sildenafil or sulfasalazine significantly ( $p < 0.01$ ) inhibited acetic acid induced MPO production in tissue as depicted in figure 19.

## DISCUSSION

In the present study, gross improvement in colitis after treatment with the sildenafil, this finding supported by evidence of macroscopic improvement following administration of sildenafil that has been reported by Khoshakhlagh *et al* [28] in an experimentally induced inflammatory bowel disease in mice. Our data showed that sildenafil did not significantly reduces colonic weight in experimentally induced colitis in rats and this finding is similar to the finding of Iseri *et al* [29]. On the other hand sildenafil had significantly reduced macroscopic score

and histopathological score of colon in experimentally induced colitis and this finding comparable with the finding of Khoshakhlagh *et al* [28]. The explanation of the beneficial role of sildenafil may be attributed to the following: first of all it has been demonstrated that inhibition of phosphodiesterase inhibitor-5 will cause marked improvement in colonic blood flow. This may be attributed to increase in the level of nitric oxide (NO) which is a potent vasodilator. The increase in NO level is attributed to accumulation of intracellular cGMP after the inhibition of the enzyme phosphodiesterase inhibitor-5 by sildenafil with resultant block to the pathway of NO degradation [30]. On the other hand, it has been shown in present study that sildenafil administration to rats experimentally induced colitis plays a significant role in reducing inflammation via reduced expression of intercellular adhesion molecules such as ICAM-1 and E-selectin. This observation has been demonstrated by Valatsou *et al* [31] which they proved that the immunohistochemical expression of both ICAM-1 and E-selectin were significantly reduced following administration of sildenafil.

Furthermore the present study also showed significant reduction in the immunohistochemical expression of both IL-6 and TNF- $\alpha$  and this finding is in accordance with the findings of previous studies that has been shown that sildenafil significantly reduces the level of pro-inflammatory cytokines such as IL-6 and TNF- $\alpha$  [29,32]. The reduced level of pro-inflammatory cytokines may be attributed to reduced hypoxia following improvement of local blood flow caused by NO. Hypoxia is well known factor to induce expression of pro-inflammatory cytokines [33]. Moreover the present study has been shown that administration of sildenafil caused significant reduction in immunohistochemical expression of oxidative markers (MPO and MDA) and these finding agrees with previous studies that has been established that sildenafil administration significantly reduces markers of oxidative stress such as myeloperoxidase (MPO) [29,34] and MDA [29,35].

#### CONCLUSIONS

sildenafil has a potent anti-inflammatory and anti-oxidant effects that can be used successfully in treatment of experimentally acetic acid induced colitis in rats.

#### ACKNOWLEDGEMENTS

The author wishes to thank pathologist Dr. Ban Jumaa Qasim /College of medicine /Al-Nahrain university for endless assistances during this research.

#### REFERENCES

1. Qureshi A.A., Omer S.K., Eswar K. *et al*. Probiotics in diarrhea: myths and facts. *Int. J. Pharm. Pharm. Sci.* 2010 ;2(3): 23-28.
2. Da Silva MS, Sánchez-Fidalgo S, Talero E, Cárdeno A, *et al*. Anti-inflammatory intestinal activity of Abaremacochliacarpos (Gomes) Barneby and Grimes in TNBS colitis model. *J Ethnopharmacol* , 2010;128:467-75.
3. Hendrickson BA, Gokhale R, Cho JH. Clinical aspects and pathophysiology of inflammatory bowel disease. *Clin Microbiol Rev* , 2002;15:79-94
4. Oz HS , Chen TS , McClain CJ ,*et al*. Antioxidants as a novel therapy in a murine model of colitis. *J Nutr Biochem* , 2005;16(5): 297-304.
5. Martin GR and Wallace JL . Gastrointestinal inflammation: a central component of mucosal defense and repair. *Exp Bio Med*, 2006 ;231(2) :130-137
6. Kolios G, Petoumenos C, Nakos A. Mediators of inflammation: Production and implication in inflammatory bowel disease. *Hepatogastroenterology* ,1998;45:1601-9.
7. Esraa EA , Rasha B A , Abeer E M *et al* . Protective Effect of Ketamine against Acetic Acid-Induced Ulcerative Colitis in Rats. *Pharmacology and Pharmacy* 2016; 7, 9-18
8. Santos CL , Souza MH , Gomes AS , *et al* . Sildenafil prevents indomethacin-induced gastropathy in rats: role of leukocyte adherence and gastric blood flow. *Pharmacol.* 2005 ; 146(4): 481–486.
9. Ignarro LJ , Napoli C, Loscalzo J .Nitric Oxide Donors and Cardiovascular Agents Modulating the Bioactivity of Nitric Oxide. *Circ Res.* 2002;90:21-28.
10. Monique A and Favez B .Phosphodiesterase Type 5 Inhibitors and sudden sensorineural hearing loss Abstract. *Braz J Otorhinolaryngol.* 2013;79(6):727-33.
11. Mehmet A, Oktay I, Enver R , *et al* . The effects of vardenafil and pentoxifylline administration in an animal model of ischemic colitis. *Clinics (Sao Paulo)* 2014 ; 69(11): 763–769.
12. Aghababaeian R., Ghazi K M , Abdi K *et al*. Protective effects of sildenafil and dipyridamol from lead-induced lipid peroxidation in perfused rat liver. *Intl. J. Pharmaol* ,2005 ; 1: 157–160
13. Osama M A , Alaa A , Tarek M A . Ameliorative Effects of Sildenafil in Acetic Acid-Induced Chronic Colitis in Rats. *Life Sc J* , 2012 ; 9(1) : 354.
14. Robert A and Dale JE . Prevention of duodenal ulcers in rats by feeding. *Proc Soc Exp Biol Med* , 1971 ;136 (2): 439–40
15. Mousavizadeh K, Rahimian R, Fakhfoury G *et al* .Anti-inflammatory effects of 5-HT receptor antagonist, tropisetron on experimental colitis in rats. *Eur J Clin Invest* ,2009 ; 39 (5) :375–383.
16. Matloub SY and Manna MJ .The cytoprotective effect of different doses of Sildenafil on indomethacin-induced gastric mucosal damage in rats. *Fac Med Baghdad* , 2010;52 ( 4) : 426-431
17. Matloub SY, Manna MJ, and Hussein KH G .Simvastatin And Rosuvastatin In The Protection Against NSAID Induced Gastric Mucosal Injury In Rats And Role Of Their Antioxidant Activity. *I R J P* ,2012; 3 ( 2 ) : 121-124.
18. Paula V P, Seito LN , Di Stasi LC , *et al* . Epicatechin Used in the Treatment of Intestinal Inflammatory Disease: An Analysis by Experimental Models. *Evidence-Based Complementary and Alternative Medicine* , 2012 ,Article ID : 508902, 12 pages
19. Warzecha Z, Ceranowicz D, Dembiński A .Ghrelin accelerates the healing of cysteamine-induced duodenal ulcers in rats. *Med Sci Monit* , 2012 ;18(5):181-7.
20. Mehesen MN, Gouda NA; Khorshid OA *et al*. Comparative study of the anti-inflammatory effect of simvastatin, rosuvastatin alone and combined with prednisolone on experimental model of inflammatory bowel disease. *International Journal of Academic Research*, 2015; 7 (3A): 183-191.
21. Meerveld BG and Tyler KR. CPI-1189 protects against DSS-induced colitis in mice. *Am J Pharmacol Toxicol* , 2006; 1:54–9.
22. Mao JW , He XM , Tang HY *et al* . Protective role of metalloproteinase inhibitor (AE- 941) on ulcerative colitis in rats. *World J Gastroenterol* , 2012 ;18 (47) :7063-7069.
23. Kuralay F, Yildiz C, Ozutemiz O, *et al* . Effects of Trimetazidine on Acetic Acid-Induced Colitis in Female Swiss Rats. *Journal of Toxicology and Environmental Health*, 2003 ;66: 169- 179
24. Cooper HS, Murthy SN, Shah RS . Clinicopathologic study of dextran sulfate sodium experimental murine colitis. *Lab Invest*, 1993 ;69:238-49
25. Pedro L B , Ângela F L , Sueli N .Immunohistochemical Assessment Of Mucosal Cytokine Profile In Acetic Acid Experimental Colitis. *Clinics* , 2005 ;60(4):277-86.



26. Hernández-Rodríguez J, Segarra M, Vilardell C *et al* . Tissue production of pro-inflammatory cytokines (IL-1beta, TNFalpha and IL-6) correlates with the intensity of the systemic inflammatory response and with corticosteroid requirements in giant-cell arteritis. *Rheumatology (Oxford)* 2004;43(3):294-301.
27. Daniel WW. Biostatistics A foundation for analysis in the health sciences.Ch seven, 7.10, determining sample size to control type II errors. 9th edition: 2009 , Pp278.Saunders
28. Khoshakhlagh P, Bahrololoumi-Shapourabadi M, Mohammadirad A, *et al* . Beneficial effect of phosphodiesterase-5 inhibitor in experimental inflammatory bowel disease; molecular evidence for involvement of oxidative stress.*ToxicolMech Methods* 2007;17:281–8.
29. Iseri SO, Ersoy Y, Ercan F, *et al* . The effect of sildenafil, a phosphodiesterase-5 inhibitor, on acetic acid-induced colonic inflammation in the rat. *J Gastroenterol Hepatol* 2009;24:1142–1148
30. Aziret M, Irkorucu O, Reyhan E, *et al* . The effects of vardenafil and pentoxifylline administration in an animal model of ischemic colitis. *Clinics* 2014 ;69(11):763-769.
31. Valatsou A, Briasoulis A, Vogiatzi G, *et al*. Beneficial Effects of Sildenafil on Tissue Perfusion and Inflammation in a Murine Model of Limb Ischemia and Atherosclerosis. *Curr Vasc Pharmacol* , 2017 ;15(3):282-287
32. Kniotek M and Boguska A . Sildenafil Can Affect Innate and Adaptive Immune System in Both Experimental Animals and Patients. *Journal of Immunology Research* , 2017; 17:454-460.
33. Ahmed OM, Afifi A, Ali TM, *et al*. Ameliorative Effects of Sildenafil in Acetic Acid-Induced Chronic Colitis in Rats. *Life Science Journal* , 2012;9 (1): 354-361.
34. Yildirim A., Ersoy Y., Ercan F., *et al* .Phosphodiesterase-5 inhibition by sildenafil citrate in a rat model of bleomycin-induced lung fibrosis. *Pulmonary Pharmacology and Therapeutics* , 2010; 23(3):215–221.
35. Xu W, Song S, Huang Y *et al* . Effects of perindopril and valsartan on expression of transforming growth factor-beta-Smads in experimental hepatic fibrosis in rats.*J Gastroenterol Hepatol* , 2006;21 (8):1250–1256.