

Anterior Cruciate Ligament Reconstruction: Arthroscopic Modified Transtibial with Hamstring Tendon Autograft

Ihsan A.M. Alsalman¹, Iskandar Mahdi Alardi¹

Department of Surgery, College of Medicine, University of Al-Qadisiyah, Iraq

Abstract

Back ground: Anterior cruciate ligament (ACL), tear is a common knee ligaments injury among young patients due to non-contact sport injuries, result in instability of the joint. Reconstruction still is the golden stander surgical treatment of such injury.

Aim: To evaluate short term functional outcome of modified transtibial ACL construction.

Patients and Methods: A case series study of 30 male patients operated in the same hospital by same surgeon using modified transtibial quadruple hamstring tendon graft for ACL reconstruction using interference screw for tibial fixation and slit tag for femoral fixation.

Results: Excellent results in 12 patients, good in 13, fair in 4 and poor in one patient, which's comparable to the others international results using transtibial technique or transportal technique for reconstruction,

Conclusion: modified transtibial arthroscopic ACL reconstruction, still gives good functional results on short term.

Key words: Anterior cruciate ligament, ACL reconstruction, Knee instability.

INTRODUCTION

Anterior cruciate ligament (ACL), is an important structure to stabilize the knee joint, the main function is to prevent a pivot shift of the knee during activities [1,2]. It is the most frequently completely disrupted ligament of the knee, commonly occur from non-contact, twisting or landing event during sport activities [3].

The incidence of ACL tear increasing in general population due to sport participation, and its rupture lead to progressive instability of knee with long term sequel [5].

Arthroscopic reconstruction of ACL, to stabilize the knee joint, prevent meniscus injury and cartilage damage, is the golden standard surgery for torn ACL, with various method for femoral tunnels placement techniques, non- anatomical conventional trans-tibial or anatomical trans-portal femoral tunnel placement or all inside technique for both tibia and femoral tunnel placement, and recently ideal transportal tunnel [4,5,6].

Graft choices for ACL reconstruction, either autograft, allograft or prosthetic materials. Autogenous hamstring tendon graft, is graft of choice in primary reconstruction [7].

Therefore, this case series study was designed to evaluate the functional results of Arthroscopic modified transtibial ACL reconstruction on short term follow up.

PATIENTS AND METHODS

A Prospective case series study, consisted of thirty patients with traumatic anterior cruciate ligament injury, underwent arthroscopic assisted reconstructions, in Al-Diwanyia teaching hospital orthopedic department, between January 2011 to January 2014, using quadruple hamstring tendons. Patients in the age of 19_35 years old with symptomatic ACL tear are included in this study, patients with multi-ligaments injuries, or ACL rupture with complex meniscus injuries were excluded from this study.

Preoperative assessment of all cases including detailed history and physical examinations which including special test for instability, anterior drawer test was positive in all patients, Lachmann test was grade 2 in all patients and pivot shift test which positive (grade 2-3) in all patients also.

Radiological assessment by anteroposterior (A-P) standing, lateral views radiography, for all patients and finally MRI examination of the knee.

In all patients, the finding (clinical and MRI) suggest complete tear of ACL, so we plan to do reconstruction for them.

Operative Technique

All patients admitted to the hospital at the day of operation, early morning preoperative antibiotics administration were done with third generation cephalosporin (ceftriaxone) just before operation. Surgery done in all our patients under regional spinal anesthesia. The patient placed supine on the operating table with the knee hanging from side of the table, examination under anesthesia were done to confirm the instability (lachman and pivot shift tests), then exsanguination tourniquet was applied to the limb. At first, we do a diagnostic arthroscopy through anterolateral port to confirm the diagnosis of ACL tear and to deal with meniscus pathology if present by partial menisectomy through anteriomedial port. Then we harvested the hamstring tendon through straight incision about 2-3 cm, started at the level of tibia tuberosity, on medial tibia border. incised the Sartorius aponeurosis and identify the tendon of gracilis and semitendinosus which harvested by tendon stripper .Preparation of four strand tendons on tendon plate, and measure the thickness of the quadruple tendons by the device, then we fixed by ethebound suture at one end .After quadruple tendons preparation we proceed again to arthroscopy of the knee through anterolateral port

and start to prepare the bony tunnels, first we remove the remnant of ACL by motor shaver leave only part of its tibia attachment that useful to identify tibia foot print and because of its proprioception, then try to identify the over the top position on posterior aspect of medial surface of lateral femoral condyle to identify the foot print of femoral attachment of ACL.

We start to drill the tibial tunnel by the tibial tunnel jig, the entry of tibia tunnel was made on the medial tibia border near the anterior border of medial collateral ligament ,trying to make it more horizontal than vertical tunnel, in order to make nearanatomical(ideal) femoral tunnel inside the joint, we put the hole of tunnel in the posterior part of original ACL tibia foot print between the medial and lateral tibia eminence just behind the posterior border of anterior horn of lateral meniscus, 5-7 mm anterior to PCL. After introduction of wire in tibia we examine the impingement of wire against the roof of intercondylar notch, (usually tibia tunnel length between (3-4 cm). we start drilling of tibial tunnel by 5 mm hole at first, then we pass awire from this hole, and manipulate the wire inside the joint with different degrees of knee flexion with varus and internal tibial rotation to find near anatomical(ideal) femoral tunnel site, as much as we can, in the posterior quadrant of medial wall of lateral femoral condyle, then we drill the wire in femoral tunnel site. After that we drill both tibial and femoral tunnel in the same time by drill bite corresponding to actual diameter of harvested tendons, we try to make it between 10_9 o'clock on right knee and 2_3 o'clock on left knee if possible. We fixed the endobuttom to the folded end of ligament at appropriate length in order to achieve flipping and then start to pull the quadruple graft through tibia tunnel. A passing pin was advance through the tunnel and the graft pull proximally, the endobutton was flipped on anterolateral femoral cortex, once flipping occurs we put the knee through full range of movement (flexion extension) for twenty times, then fixed the graft in tibia tunnel by metallic interference screw while the knee in full extension. Close the wound in layers, no drain used and back slab in full extension.

Post-operative care and rehabilitation.

Immediately after surgery, we use six phases rehabilitation program, focusing on reduction of pain and swelling during first week by ice packing and analgesia, the encourage Quadriceps muscle exercise and partial weight bearing as patient tolerate. Patients discharge from hospital, after 24 hours from surgery with full instruction for physiotherapy program and schedule for follow up visits. First visit after two weeks in which, stiches removal and replace the back slab by fixed knee brace locked in extension, the start gradual knee extension flexion exercise to encourage full knee extension and flexion, then we see patients every two weeks for first 3 months then every month for next 3 -5 months. After six weeks, we remove the brace, encourage full weight-bearing, open chain knee exercise to strength the extensor and flexor of the knee and balancing exercise. We allow sport activity if the patient has good muscle power and control (6-8) moths postoperatively. After that follow up visit every two months. Final assessment was

done on basis of stability test and lysholm score at 24 months after surgery. Tunnel position was assessed on postoperative radiographs using Hornets Quadrant method [8].

RESULTS

All the patients in this study were male patients, the mean age of them was 27 years ranging from 18-35years. Right knee was involving in 19 cases (63.3%), left knee in 11 cases (36.6%), the sport injuries account for all study cases. Times from injury to the surgery ranging from 8-24 months, the time of surgical procedure, were range from 90-120 minutes, all of surgery done under regional anesthesia, and all the patients discharge on the next day of surgery. Only 4 patients in our series had associated meniscal injury (13. 3%).We assess the results of our patients according to Lysholm knee score system, the preoperative score was 22-60 (poor) in all patients, that was improved postoperatively in majority of patients at the end of final visit (at the end of two year of surgery). The score was excellent (more than 90) in (12) patients (40%), good (84-90 score) in thirteen (13) patients (43.3%), fair (65-83 score) in (4) patients (13.3%) and poor results (less than 65) in one patient (3.3%)(tab.1). Lachman tests, result after six months of surgery, was grade 2 in 7 patients (23.3) %, grade 1 in 12 patients (40) %, and zero in 11 patients (36. 7%).On last follow up visit, test was zero in 17 patients (56.6%), 1 in 9 patients (30%) and 2 in 4 patients (13.4%) fig.1.

Pivot shift test, was 0-1 grade in all patients on the last follow up visit.

On assessment of femoral and tibia tunnels on radiography, the femoral tunnel was in posterior quadrant on blumensat line on lateral radiograph and on 11-10 o'clock on anteroposterior radiograph in 26 patients and in middle quadrant on blumensat line and on 12-11 o'clock in four patients.

Table 1. Lysholm Scale Results

Number of patients	Result
12 patients	Excellent (score more than 90)
13 patients	Good (score 84-90)
4 patients	Fair (65-83)
1 patients	Poor (less than 60)

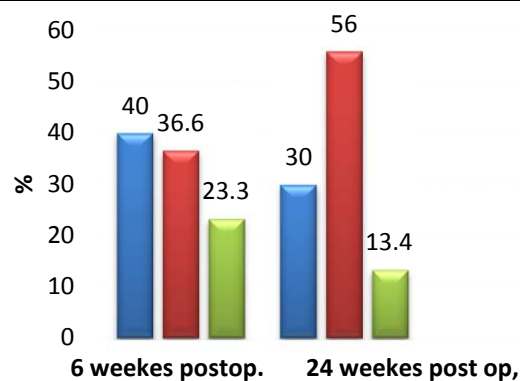


Figure 1. Lchman test results after surgery at each review point.(six months and two year after surgery).

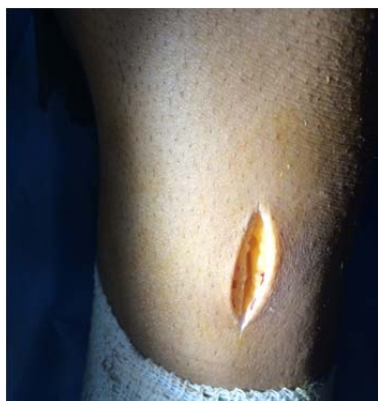

Figure 2. skin incision for harvesting of ST tendons

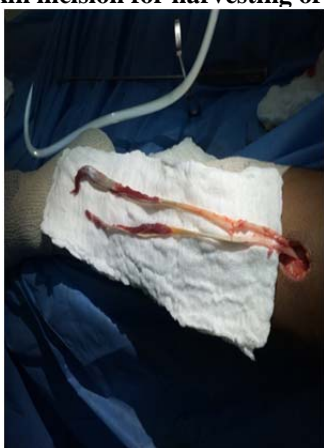

Figure 3. ST tendon harvested.

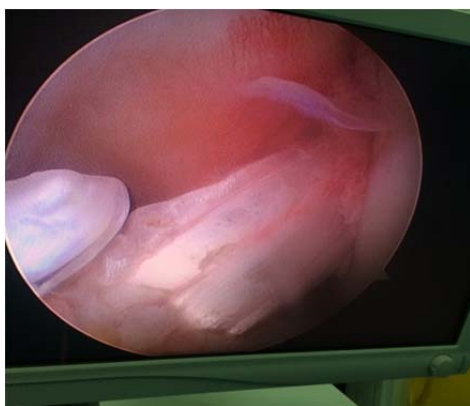


Figure 4. Arthroscopic view for quadruple tendon inside the knee

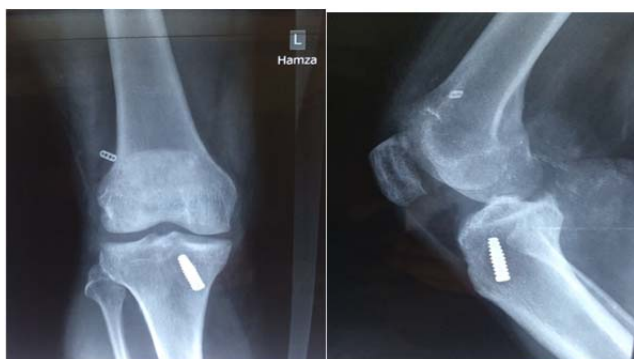

Figure 5. Postoperative x-ray assessment for tunnel placement

DISCUSSION

Surgical reconstruction of ACL has become the standard treatment of these injuries, the primary goal of the reconstruction is to restore the knee stability. Successful clinical results following ACL reconstruction with hamstring tendons autograft has been reported by many authors. Optimizing femoral tunnel positioning is crucial for successful ACL reconstruction surgery, every decade we change our minds about femoral tunnel positioning, in 1980 was isometric position, 1990 non anatomical transtibial, 2005 transportal anatomical, and recently shift to ideal transportal site of femoral tunnel that should be encroach on ridge to be anatomical, functional and also isometric position to optimizing the A-P and rotational stability. In our locality, no study reveals the results of ACL reconstruction surgery, so as a beginner in this field we should exposed the results of our cases to the results of others international studies used same score for evaluation, nearly same duration of follow up and compare between them to improve our learning curve. All patients in our study are male no female patient, so it's more common in male than female in our country, because our females, less likely practicing sport activity. the mean age of our patients are 25 years old, right knee is more common than left in our series (19 patients with right knee), 11 patients with left knee[11].

We used modified method for placement of femoral tunnel through transtibial port, trying to optimizing femoral tunnel, more horizontal approaching the ideal site for tunnel to improve the clinical results, by start drilling the tibial tunnel near or at anterior border of medial collateral (MCL) ligament, exist intra-articular in posterior one third of tibial foot print of ACL, then start to negotiate the femoral tunnel site with wire on the posterior one third of medial wall of lateral femoral condyle with varus degree of flexion of the knee, varus and internal rotation of tibia[11].

When we compare our results with results others international studies that using the same score, Nebelung et al. Reviewed the results of 29 patients with autogenous ST tendons graft, the grade 66% of the results as normal or nearly normal [11]. Qiang et al. reviewed the results of 38 patients with ST graft reconstruction, the preoperative lysholm score was 69 ± 4.8 to the 94 ± 1.1 postoperatively at the end of 18 months [12]. Mirzatoioei et al. Reported postoperative lysholm score of 78% operated by ST tendon ACL reconstruction, and 81.41% operated by transfemoral tunnel in 88 patients after 18 months[13]. S plaski et al. In 2009 series with mean follow up tie of 51 month, the lysholm score improve from 72.1 to 94.1 mean at final follow up, using ST graft with femoral end button fixation, in 105 patients. (14). Ejuerhed L et al. Series the mean lysholm score improve from 68 to 90 postoperative at final follow up using the ST graft with endobutton fixation in 71 patients [15]. Eriksson et al. series in 2001, the score improves from 71 to 86 mean at final follow up of 31 months, using ST tendons with femoral end button fixation [16]. Mohr d Shafi Bhat, reported the improvement in lysholm score from 52.7 preoperative to 89.7 postoperative in 30 patients after 24 months follow up [17].

Youn Ys , reported comparable results in 40 patients, 20 patients with transportal approach and 20 patients with modified transtibial approach on short term follow up [18].

So our results, nearly comparable or some time even better than the results of other studies, this give us a positive feedback as a beginner in this field to improve our learning curve.

CONCLUSION

Arthroscopic modified transtibial ACL, reconstruction, gives good results, better than traditional transtibial one and approaching the result of transportal approach. So in spite its draw back on the length of tibial tunnel (its make tibial tunnel short 3-4 cm), its reliable method specially in at the beginning, because it's easier than transportal tunnel placement.

REFERENCES

- 1- John M. Flynn. Orthopedic knowledge update,10 editions, AAOS. 2011; p 453-461.
- 2- Marker D Miller, Stephen R Thompson, Jennifer A Hart. Review of orthopedics, six editions:(2012):298-231.
- 3- Spicer DDM, Blagg SE, Unwin AJ. Alum RE. Anterior knee symptoms after four strand hamstring tendon anterior cruciate ligament reconstruction. Knee Surge. Sport Traumatol Authors. (2008):286-289.
- 4- Pinczewski LA, Salmon IJ, Jackson WF, et al. Toshiro S. Radiological landmarks for placement of tunnels in sigle bundle reconstruction of ACL. Journal Bone Joint Surge Br (2008),90-B:172-179.
- 5- Koutras, Giorgio, Papadopoulos, et Al. Journal of Knee surgery, Sport traumatology, Arthroscopy; (2013), 21(8):1904.
- 6- Department of orthopedic surgery, Urmia university of medical sciences, Urmia, Iran. Comparison of short term clinical outcomes between transgibial and trans-portal ACL reconstruction. Act Ortho Traumatol Turc. (2012);46(5):361-6.
- 7- Groin F, Buzz R, Ag, et al. Femoral tunnel position in anterior cruciate reconstruction using three techniques: acadaver study. Arthroscopy (1999);15(7):750-756.
- 8- Houser C, Tecklenburg K, Kuenzel KH, et al. Postoperative evaluation of femoral tunnel position in ACL reconstruction: plain radiography versus computed tomography. Knee Surge sport Traumatol Arthrosc. (2005);13(4):256-262.
- 9- Johnson H, Elmqvist LG, Karrholm J, et al. Over the top or tunnel reconstruction of anterior cruciate ligament, A prospective randomized study of 54 patients. J Bone Joint Surge Br.1994;76(1):82-87.
- 10- Khalfayan ED, Sharkey PC, Alexander AH, et al. The relationship between tunnel placement and clinical results after ACL reconstruction. Am J Sports Med.4996;24(3):335-341.
- 11- Dakhil, A.S. Association of Serum Concentrations of Proinflammatory Cytokines and Hematological Parameters in Rheumatoid Arthritis Patients. J Phram Sci Res. 2017; 9, 1966-1974.
- 12- Klos TV, Harman MK, Habets RJ, Banks Allocating femoral graft placement from lateral radiographs in ACL reconstruction: A comparison of 3 methods of measuring radiographic images. Arthroscopy, (2000); 16(5):499-504.
- 13- Nebelung W, Becker R, Merkel M, et al. Bone tunnel enlargement after anterior cruciate ligament reconstruction with semitendinosus tendon using endobutton fixation on femoral side. Arthroscopy (1998); 14:810-5.
- 14- Qiang, Z., Shu, Z. Comparison of two methods of femoral tunnel preparation in single bundle anterior cruciate ligament reconstruction. Acta Cir. Bras. (2012) 27, 8.AUG.
- 15- Mirzatolooei F. Comparison of short term clinical outcomes between transtibial and transportal femoral fixation in hamstring ACL reconstruction. Acta Orthop Traumatol Turc.(2012).
- 16- Paweski S, Rossi J, Meeloz P ACL reconstruction Assessment of hamstring autocracy femoral fixation using the Endobutton. CL. Orthopedics and Traumatology Surgery and Research (2009).95:606-613
- 17- Ejerhed Lars, Karts Jeri, Sternberg N, et al. Patellar tendon or semitendinosus tendon auto grafts for anterior cruciate ligament reconstruction. Am Sport Med (2003); 31:19-25.
- 18- Eriksson K, Anderberg P, Hamburg P, et al. A comparison of quadruple semitendinosus and patellar tendon graft in reconstruction of anterior cruciate ligament. J Bone Joint Surge. Br (2001)83(3):348-354.
- 19- Moh d Shaft Baht. Moh d Yaseen Rather. Short term results of anterior cruciate ligament reconstruction using fur strand hamstring autograft with endobutton fixation. Journal of Dental and Medical sciences. (2013) 11:67-72.
- 20- Youn Ys,Cho SD,Lee SH.Modified transtibial versus anteromedial technique in anatomical single bundle ACL reconstruction, comparsion of femoral tunnel and clinical results. American Journal of sports medicine. (2014);42(12):29941-7.